



CODEN [USA]: IAJPB

ISSN: 2349-7750

**INDO AMERICAN JOURNAL OF  
PHARMACEUTICAL SCIENCES**<http://doi.org/10.5281/zenodo.2634106>Available online at: <http://www.iajps.com>

Research Article

**MANDIBULAR FRACTURES MANAGEMENT WITH SINGLE  
PLATE FIXATION TO ACHIEVE IMMEDIATE POST  
OPERATIVE FUNCTIONAL RECOVERY****<sup>1</sup>Dr. Ayesha Naz, <sup>2</sup>Dr. Sehrish Arshad, <sup>3</sup>Dr. Hira Aamir**<sup>1,3</sup>Lahore Medical and Dental Collage, Lahore<sup>2</sup>de Montmorency College of Dentistry, Lahore**Article Received:** February 2019**Accepted:** March 2019**Published:** April 2019**Abstract:**

**Objective:** To evaluate the archbar as a tensioning band compared to the tension band plate, providing an alternative technique for mandibular osteosynthesis to reduce implant material and minimize implant-related postoperative complications.

**Study Design:** A Retrospective Study.

**Place and Duration:** In the Oral and Maxillofacial Surgery Department of Mayo Hospital Lahore for three year duration from September 2014 to September 2017.

**Methods:** The study included open reduction and internal fixation (ORIF) in eighty patients with mandibular fractures and two groups of mini-plates and screws. Group A treated with two plates fixation group B were treated with the one plate fixation with tension strips by anarchbar in the second plate to ensure effective balancing of the fracture sections. Most of these patients were treated with local anesthesia. Postoperative complications were lower in Group-B than Group-A, preferring to use a archbar as a tension band. To defeat the torsional forces generated in the front of the mandible body during the function.

**Results:** Infection was the postoperative complication in (7.5%), 5% in Group A and 2.5% in Group B, and the other complications in Group A included 5% malocclusion and extraction. No such complication was found in 10% of the plate and 10% in the B group.

**Conclusion:** Osteosynthesis with both techniques was effective to provide an immediate postoperative function, but complications in Group B were few.

**Key words:** Mandibular fractures, tension band, double plaque osteosynthesis, implanted material, postoperative complications.

**Corresponding author:****Dr. Ayesha Naz,**

Lahore Medical and Dental Collage, Lahore

QR code



Please cite this article in press Ayesha Naz et al., *Mandibular Fractures Management with Single Plate Fixation To Achieve Immediate Post-Operative Functional Recovery.*, Indo Am. J. P. Sci., 2019; 06(04).

**INTRODUCTION:**

Man has been traumatized since Adam's days, but the problem of increasing vehicle traffic and interpersonal violence is aggravated. More awareness of the aesthetic and optimized need for the earliest functional recovery has led mandibular surgeons to develop surgical techniques to provide better options for the treatment of mandibular fractures [1]. He challenged the traditional methods of treatment with rigid internal fixation, maxillary facial fixation, splint use and intraosseous wiring in jaw- fractures [2]. The internal fixation technique, using plates and screws, resulted in a delicate reduction, superior aesthetic results, greater comfort and safety for patients, and an early restoration of functional life. The use of clamping plates and the development of self-assembled mandibular compression screws were included in the learning process, and a better system was found that was not necessary for an early recovery of functional life, and was used to compress the fractured segment. In the recovery period of the mandibular bone, the need for a stretching plate with fixing plates to achieve a chewing function was accepted by many surgeons [3]. The need for eccentric dynamic clamping plates, tension band plate was overcome. Spiessl could overcome the rotational forces in the alveolar section of fractures by adding the archbar as a tension band. This adaptation stabilized throughout the entire length of the fracture and eliminated the alveolar space separation or the fracture of the fractured bone [4]. The need for tension bands is evident to achieve a satisfactory stabilization during chewing regardless of the size and type of plates used. Champy introduced a non-compressing mini-plate system, the plates were applied close to the jaw stress zone and monocortical screws were used to secure the plates [5]. The mini-plate system requires a plate in the posterior region of the mandible and two plates in the parasymphel area to provide adequate support and stability for immediate work on bone fragments. The introduction of better and well-designed biocompatible plates and screws, modifications in surgical techniques and a better understanding of the biomechanics of bone repair have yielded more acceptable results, and these techniques are now widely and routinely applied [6]. Susceptibility to corrosion of stainless steel and release of titanium in local tissues by phagocytosis and vascular transport to distant sites; The lungs are considered facts. The use of two mini-plates recommended by many authors was compared to using an archbar as a tension band instead of the second plate in dentate areas to provide the desired optimum balance and to achieve an effective neutralization during the

function of mandibular osteosynthesis in unstable areas<sup>7</sup>. The reduction in implant material has made the process easy, reliable and profitable.

**MATERIALS AND METHODS:**

This Retrospective Study was held in the Oral and Maxillofacial Surgery Department of Mayo Hospital Lahore for three-year duration from September 2014 to September 2017.

Eighty patients of the mandibular fractures in the body area were divided into two equal groups as 'A' and 'B'. These patients were randomly selected from the maxillofacial unit after clinical and radiographic evaluation. Forty patients in the "A" group were treated by fixing two plates on the bone in the area below the peaks of the teeth and fixing them along the fracture line with two screws at each of the lower edge of the mandibular bone. The side of the fracture line is separated by at least 5 mm. Forty patients of the second group were treated by open reduction and fixation with a single plate in the flat bone towards the lower edge of the mandibular bone with two screws on both sides of the flat bone in the area below the peaks of the teeth and the fixation line. The semi-round wire made of stainless steel is adapted to the buccal side of the teeth along the fracture line along the tooth belt, which contains at least two teeth on each side and is fixed by a soft stainless-steel wire along 0. To serve as a tension band, it is 5 mm in diameter. A high torque drilling machine was used at a speed of less than 1000 rpm (revolutions per minute) to prevent overheating during bore hole drilling by screwing holes in the bones.

**Procedure**

The face and the surgical site were prepared and the patient was covered with sterile towels. Anesthetic solution, 1 to 2% lidocaine; 100,000 adrenalin were administered to local and regional blockade. In order to reduce the bleeding, the anesthetic solution was injected into the recommended surgical site. Some cooperative or elective cases are operated under general anesthesia. Before surgical procedures, sensitive non-traumatic fixation was established carefully to ensure proper traumatic occlusion. A mucoperiosteal incision was made in the buccal or labial sulcus from the fracture line and the flap was projected to reach the fracture site. Monocortical screws were placed in the bone on both sides of the fractured line, and the soft 0.5 mm stainless steel wire was wrapped around the screws shown in figure to approximate and stabilize the fractured sections. The plates were correctly adapted and secured with at least two screws on each side of the fracture line.

Continuous and abundant watering with normal saline from the drill tip and surrounding area was continued during drilling. The second plate in group A was similarly fixed to a shape-2 of at least 5 mm. Temporary inter-dimensional fixation and cable connections in Figure 8 were removed, functional obstruction was reevaluated and wound was sealed with 3/0 vicryl in layers.

In group B, the second plate was removed and the half-way wire was adapted and fixed along the fracture line as in figure 4.

### Post-Operative Complications

In both groups, postoperative morbidity was evaluated according to the criteria given as A and B. Infection was noted when abscess manifested itself. Malocclusion was confirmed according to the evaluation of occlusion, maximum division, relation to midline, molar relationship. Patients' feelings about any abnormality during chewing were classified using articulation paper when they were present. Patients were asked whether there was a subjective feeling of hypesthesia or numbness in the

lips and mental region because of the difference in the nature of sensation compared to the uninjured side and the skin of the cheek. Sensory tests were performed with a slight touch of cotton and a sharp / sharp differentiation with the dental probe on the jaw and lower lip. When the plaque was exposed or the infection persisted with continued medication or any other complaint about the plaque was issued. If the persistent mobility of the fracture segments was observed after 4-8 weeks of treatment, complications were included as non-union. The data were subjected to statistical analysis and a ratio test was applied to verify the significance of the difference between the two groups as  $p < 0.05$ .

### RESULTS:

The majority of the patients belong to the age group (16 to 25 years). Were 55.5% and 22.5% (26-35 years) and 95% were male. The maximum number of patients treated in this study was broken in 72.5% of the mandible, 12.5% in the premolar region and 15% in the symphysis region. Traffic accidents are 70%, the main cause of mandible fractures, and 15% is the second common cause, details in Figure

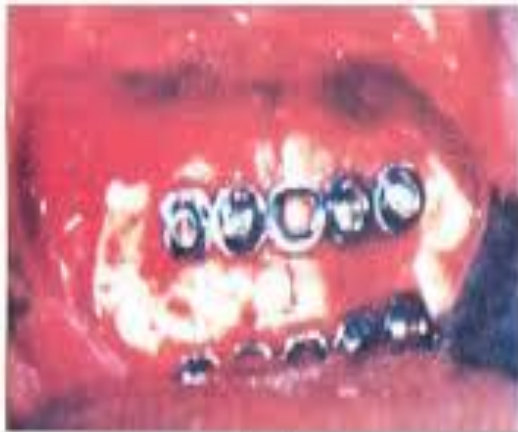

Fig 3

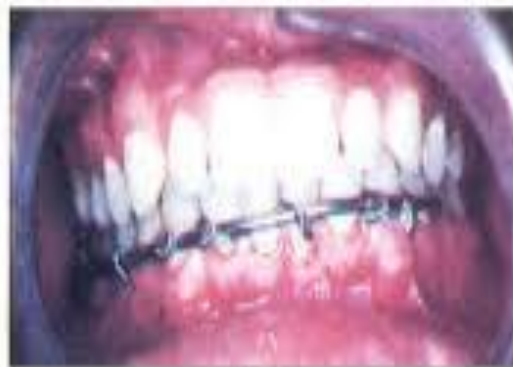

Fig 4

The delay in trauma and treatment was divided into three groups: the first group included patients treated at the first week and 62%, 28% received treatment at the second week and only 10% were delayed for two weeks. Infection was a common complication in both groups, which was 7.5% in total, 10% in double plaque group and 5% in single plaque group. Occlusal changes were nominal, only two patients were 2.5%, while selective occlusal grinding was required in the double-plaque group, while the intercuspidal relations in the second group did not change. Four patients required 5% plaque removal and all belonged to group A. Details of the complications shown in Figure 5.

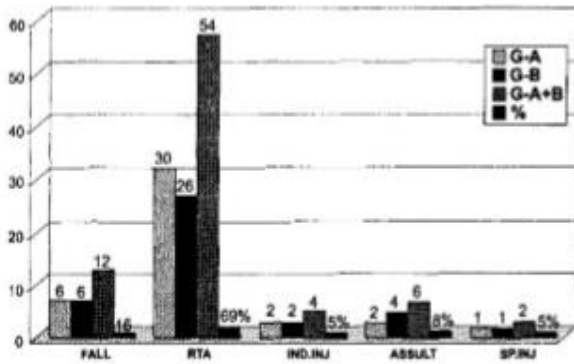


Fig 5. Etiology of fractures in Group-A and Group-B




Fig 6. Complications in Group-A and Group-B

**DISCUSSION:**

The ultimate goal of maxillofacial surgeons in the treatment of maxillofacial trauma is the restoration of physical integrity and the earliest possible functional life with the highest morbidity. In this study, the maximum number of patients was 70% due to traffic accidents and 2.5% in the group of sports injuries. Most of the RTA was associated with the car speed [8]. The use of metal plates and screws in the treatment of mandibular fractures has reported an infection rate of 3% to 27% in previous studies. The mobility of the fractured segments was the most common technical cause of infection. Technical errors, such as involuntary insertion of the screws into the fracture line, poor adaptation of the plate or contour, adequate cooling during the preparation of holes for the insertion of screws, increase the risk of post-operative infection [9]. The failure of the

technique has been shown to be a frequent event in the application of rigid internal fixation devices to mandibular fractures. The absence of antibiotics used is considered a predisposing factor for infection, so it is recommended that antibiotics are used as prophylaxis and postoperative routine [10]. Many authors have recognized it as an important risk factor for female infection in the fracture line. During this study, there was an infection of 7.5% in total, 5% in the 'A' group and 2.5% in the B group. While infection in group B responded to removal of the infected tooth, in the 'A' group, 2.5% were treated with antibiotics and 2.5% responded to plaque removal. 5% antibiotic use was observed in all cases. A patient with alveolar fracture in the 'B' group had an apical infection in one of the teeth and responded well to root canal treatment.

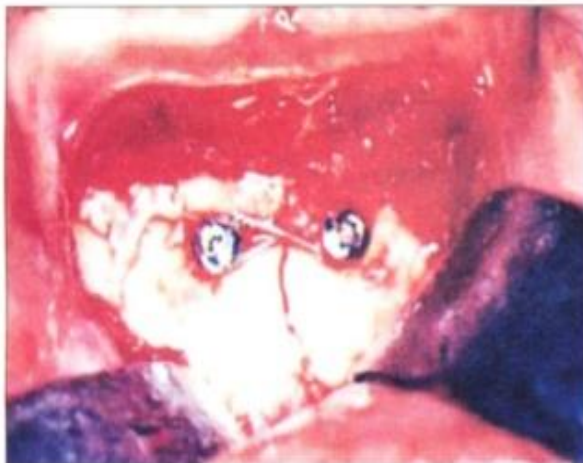

Fig 1

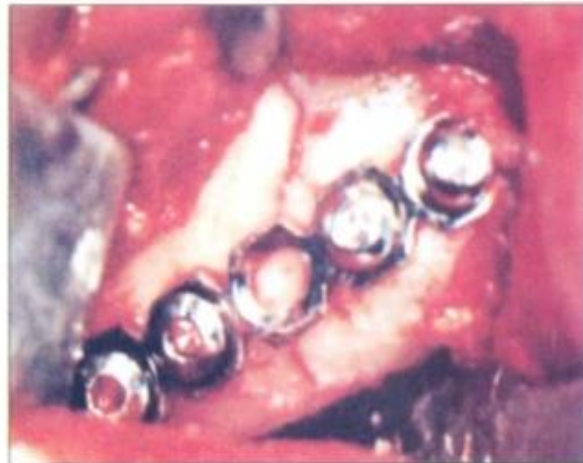

Fig 2

Overall, the infection rate of 7.5% was comparable to previous studies. In group 'A' the incidence of infection doubled according to the 'B' group. The assumption is that the reduction of the implanted material minimizes operational errors and facilitates easy adaptation of a plate to the selected soft mandibular bone, thereby reducing postoperative complications<sup>11</sup>. The low infection rate in the 'B' group reflects the stability provided by the fixation of the labial spring superior to the tensioning tape plate. The treatment method was found to be the main factor associated with increased risk of infection. In previous studies, it was reported that there was up to 18.2% malocclusion, whereas it was 2.5% during this study<sup>13</sup>. Inadequate bending and adaptation of the plates are said to be the cause. These cases of malocclusion belonged to 'A' group and were corrected by occlusal grinding. They are the result of an error in the number of plates or inadequate reduction and stabilization during the osteosynthesis procedure. These plates were then exposed to the buccal groove and removed. The sensitivities of the plaque, the sensation of hot and cold, or the thermal sensitivity felt after the operation, and the protective effects against plaque stress in the underlying bone are the reasons for the elimination of plaques<sup>14</sup>. Possible complications related to the presence of plaques: loosening of the equipment, related sensitivity, swelling, pain and infection. X-ray effects of metal toxicity, hypersensitivity, carcinogenicity, radiation and metal implants are rare causes of implant removal. Six weeks after the surgery, the spring-grinding operation increased the stresses applied to the bone, thus the protection against stress was minimized compared to the double-plate fixing system. The use of an Archbar as a tension band reduced the possibility of complications related to technical errors during fixation of the second plate and screws<sup>15</sup>. Probability of possible complications, such as protection against stress, obviousness, thermal sensitivity and others, has been reduced (previously analyzed). Double reduction of plaque removal for the second surgery. These advantages increased the reliability of the technique and reduced the cost and fear of the patient.

### CONCLUSION:

The osteosynthesis of both techniques provided optimal stability for fracture healing and allowed immediate chewing. The superiority of the second technique is clear. Rigid fixation by this technique is faster and lower cost, requires less amount of implanted material, less problem than double-plate fixation. The results were improved with this method because of the easy and better adaptability of a plate and less screws. Archbar fixation provided better

control over occlusal stability and enabled small occlusal corrections after surgery without any second surgical intervention.

### REFERENCES:

1. Batbayar, E-O., P. U. Dijkstra, R. R. M. Bos, and B. van Minnen. "Complications of locking and non-locking plate systems in mandibular fractures." *International journal of oral and maxillofacial surgery* (2019).
2. Dergin, Guhan, Yusuf Emes, and Buket Aybar. "Evaluation and Management of Mandibular Fracture." In *Trauma in Dentistry*. IntechOpen, 2019.
3. Sukegawa, Shintaro, Takahiro Kanno, Masanori Masui, Yuka Sukegawa-Takahashi, Tsukasa Kishimoto, Ai Sato, and Yoshihiko Furuki. "Which fixation methods are better between three-dimensional anatomical plate and two miniplates for the mandibular subcondylar fracture open treatment?." *Journal of Cranio-Maxillofacial Surgery* (2019).
4. Desai, Vyoma, and Manoj Kumar Jain. "Locking Miniplates Osteosynthesis of Anterior Mandibular Fractures—Quo Vadis?." *Journal of Oral and Maxillofacial Surgery* (2019).
5. Sirin, Yigit, Senem Yildirimturk, Emre Aytugur, Sirmahan Cakarer, Sinan Horasan, and Koray Guven. "A comparison of panoramic radiography and cone beam computed tomography in the detection of osteosynthesis complications in sheep mandibular angle fractures." *Oral surgery, oral medicine, oral pathology and oral radiology* 127, no. 2 (2019): 167-174.
6. Wusiman, Patiguli, Bin Nie, Wei Dong Li, and Adili Moming. "Management of mandibular angle fractures using 3-dimensional or standard miniplates: A systematic review and meta-analysis." *Journal of Cranio-Maxillofacial Surgery*(2019).
7. Hu, W., Mohit Agrawal, Sandeep Thadani, Shailesh Kumar Mukul, Ramita Sood, Aditi Patel, Rahul Dhanak, and Suket Tailor. "Comparative evaluation of a single 2.0-mm AO locking reconstruction plate with conventional miniplate osteosynthesis for treatment of linear non-comminuted fractures of symphysis and parasymphysis region of the mandible." *Journal of stomatology, oral and maxillofacial surgery* 120, no. 1 (2019): 11-15.
8. Alpert, B. and Jones, L.C., 2019. Complications of Mandibular Fractures. *Facial Trauma Surgery E-Book: From Primary Repair to Reconstruction*, p.201.

9. Mishra, Niranjana, Nirav Thakkar, Indubhusan Kar, Shadab Ali Baig, Gaurav Sharma, Rosalin Kar, Gyana Ranjan Sahu, and Krishna Gopal Birmiwala. "3-D Miniplates Versus Conventional Miniplates in Treatment of Mandible Fractures." *Journal of maxillofacial and oral surgery* (2019): 1-8.
10. Wusiman, Patiguli, Alifu Tayie, Wang Ling, and Adili Moming. "Management of Mandibular Fractures Using Locking and Nonlocking Miniplates." *Journal of Craniofacial Surgery* 30, no. 2 (2019): 448-452.
11. Marschall, Jeffrey S., Robert L. Flint, George M. Kushner, and Brian Alpert. "Management of Mandibular Osteomyelitis with Segmental Resection, Nerve Preservation, and Immediate Reconstruction." *Journal of Oral and Maxillofacial Surgery* (2019).
12. Zhang, Ze-Liang, Shuai Wang, Chang-Fu Sun, and Zhong-Fei Xu. "Miniplates Versus Reconstruction Plates in Vascularized Osteocutaneous Flap Reconstruction of the Mandible." *Journal of Craniofacial Surgery* 30, no. 2 (2019): e119-e125.
13. Ashraf, Usman, Shaheen Ahmed, Abdul Hafeez Shaikh, Noureen Iqbal, Abbas Zaidi, Syed Jaffar, Umer Hasan, and Anwar Ali. "CONDYLAR FRACTURE; CORRELATION OF TREATMENT OUTCOMES OF CONDYLAR FRACTURE FIXATION WITH SINGLE AND MULTIPLE MINIPLATES." *Professional Medical Journal* 26, no. 3 (2019).
14. Wusiman, Patiguli, Dilidaer Taxifulati, Li Weidong, and Adili Moming. "Three-dimensional versus standard miniplate, lag screws versus miniplates, locking plate versus non-locking miniplates: Management of mandibular fractures, a systematic review and meta-analysis." *Journal of Dental Sciences* (2019).
15. Munding, Gerhard S., Joseph S. Gruss, and Richard A. Hopper. "Management of Panfacial Fractures." *Facial Trauma Surgery E-Book: From Primary Repair to Reconstruction* (2019): 248.