



CODEN [USA]: IAJ PBB

ISSN: 2349-7750

**INDO AMERICAN JOURNAL OF  
PHARMACEUTICAL SCIENCES**<http://doi.org/10.5281/zenodo.3736727>Available online at: <http://www.iajps.com>

Research Article

**CLINICAL PRESENTATION, FREQUENCY AND POST-SURGICAL COMPLICATIONS OF RETROSTERNAL GOITER****Dr Muhammad Faisal Ejaz, Dr Zarmina Fatima, Dr Muhammad Umar Rasool**  
Lahore General Hospital Lahore**Article Received:** February 2020**Accepted:** March 2020**Published:** April 2020**Abstract:**

**Objective:** This research work carried out to find out the rate of occurrence of retrosternal goiter (RSG), its clinical manifestations and post-surgical complications in the patients appeared with goiter.

**Methodology:** This is prospective, transverse research work which carried out in Surgery Department of General Hospital, Lahore from March 2017 to December 2020. All the patients suffering from goiter were assessed for the thyroid's retrosternal extension, clinical manifestations and post-surgical complication.

**Results:** Among total nine hundred and seventy-eight patients, 9.10% (n: 89) patients were present with thyroid's retrosternal extension. Most of the patients were females (94.510%) & euthyroid (91.020%). Total 39.330% patients were in their 5<sup>th</sup> decade of life. We found the retrosternal extension of two lobes in 83.150% patients, and extension of single lobe in 16.150% patients. The most common complaint was dyspnea according to most of the patients, followed by headache in 30.330% and dysphagia in 25.840% patients. There was presence of recurring laryngeal nerve palsy in 4.490% patients. There was development of hypocalcaemia in 3.370% patients as well as same rate of infection of wound after surgical intervention.

**Conclusion:** Thyroid's retrosternal extension is very common. The surgery of this complication is easily possible through cervical technique.

**Key Words:** Thyroid, palsy, extension, goiter, retrosternal, surgery, occurrence, prevalence, lobes, development, cervical.

**Corresponding author:****Dr. Muhammad Faisal Ejaz,**  
Lahore General Hospital Lahore

QR code



Please cite this article in press Muhammad Faisal Ejaz et al, **Clinical Presentation, Frequency And Post-Surgical Complications Of Retrosternal Goiter**, Indo Am. J. P. Sci, 2020; 07(04).

**INTRODUCTION:**

There can be finding of ectopic thyroid tissue in rare circumstances in center part of neck, subsequent region of tongue, below the lower pole of thyroid and sometimes in the anterior mediastinum [1]. RSG is uncommon presentation of intra-thoracic extension of an enflamed thyroid, normally as an outcome of multi-nodular goiter. There is variety of the definition of goiter in available literature. Golden burg [2] elaborated the RSG when it reaches the level of 4<sup>th</sup> thoracic vertebra, Singh in 1994 [3] described it when greater than fifty percent of thyroid tissue under thoracic inlet and White in 2008 [4] defined it when it needs mediastinal dissection. The most accepted standard is prescribed by Candela [5] which described that when there is extension of thyroid more than two centimeter under thoracic inlet.

Both portions of cervical and retrosternal sides normally maintain their supply of blood directly from the arteries of thyroid. In 75.0% to 90.0% patients, the location of gland is in the antero-superior compartment and in 25.0% patients, gland was present in middle compartment. Ectopic thyroid tissue had abnormal supply of blood from the loco-regional vessels of blood [6]. The removal of thyroid with surgical intervention is a matter of choice and most of the patients present have improvement following the surgical intervention. The removal of RSF is possible through cervical incision in most of the patients except among patients present with past history of mediastinal surgical intervention [7, 8]. The rationale of this research work was to find out the rate of occurrence of RSG, clinical manifestation and post-surgical intervention in the patients suffering from goiter.

**METHODOLOGY:**

This transverse research work carried out in the Department of Surgery of General Hospital, Lahore from March 2017 to December 2020. Ethical committee of the institute gave the permission to conduct this research work. We took written consent

from the patients after explaining them the purpose of this research work. The assessment of all the patients suffering from goiter carried out and we included the patients present with the thyroid's retrosternal extension in this research work. For the evaluation of the retrosternal extension, we followed the standard prescribed by Candela [5]. In accordance with this standard, any enlargement of thyroid greater than two centimeters detected under thoracic inlet during surgery, when the necks of the patients were held in extension is regarded as RSG. We excluded all the patients present with the retrosternal extension of less than two centimeters of thyroid tissue under thoracic inlet diagnosed during surgical intervention or present with no retrosternal extension.

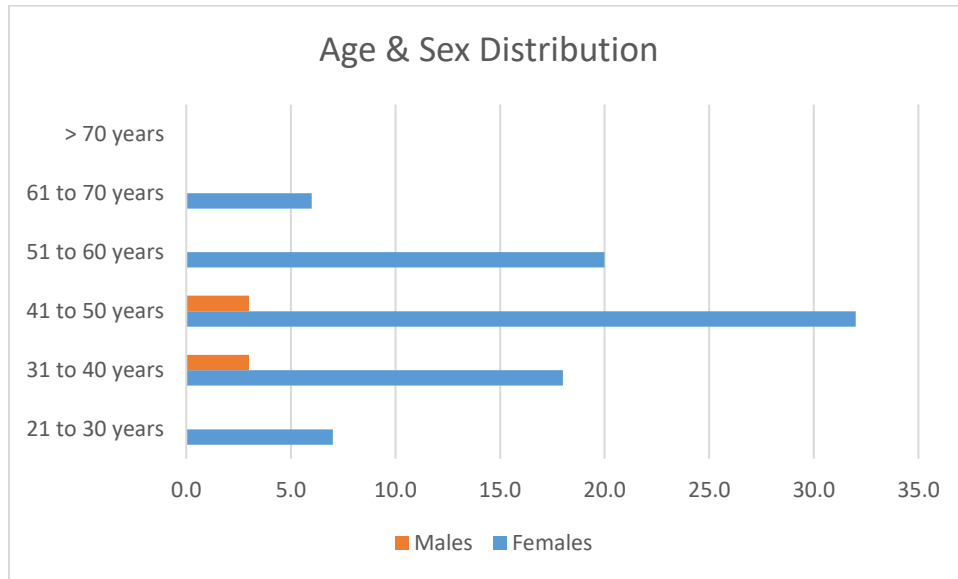
All these patients got admission and underwent complete clinical, histopathological and bio-chemical evaluation. In the suspected patients, the examination of the degree of the thyroid extension carried out by investigations as chest X-ray chest, X-ray of thoracic inlet or computed tomography and then confirmed at the time of surgical intervention. The preparation of the patients for surgery carried out and we performed necessary investigations for application of thyroidectomy. All the patients underwent thyroidectomy through cervical approach. The assessment of the results carried out and we used EPI-6 software for the statistical analysis of the collected information.

**RESULTS:**

Total nine hundred and seventy eight patients reported with multi-nodular goiter in OPD of Surgery Department in the duration of this research work. Among total diagnosed patients, 9.10% (n: 89) patients were present with confirmed diagnosis of thyroid's retrosternal extension. No patient of this research work was present with the mediastinal thyroid retrosternal site. Most of the patients were females and they were in their 4<sup>th</sup> and 5<sup>th</sup> life decade (Table-1) as 23.590% and 39.330% correspondingly.

**Table- I: Age and Sex distribution of Retrosternal Goiter in different age groups.**

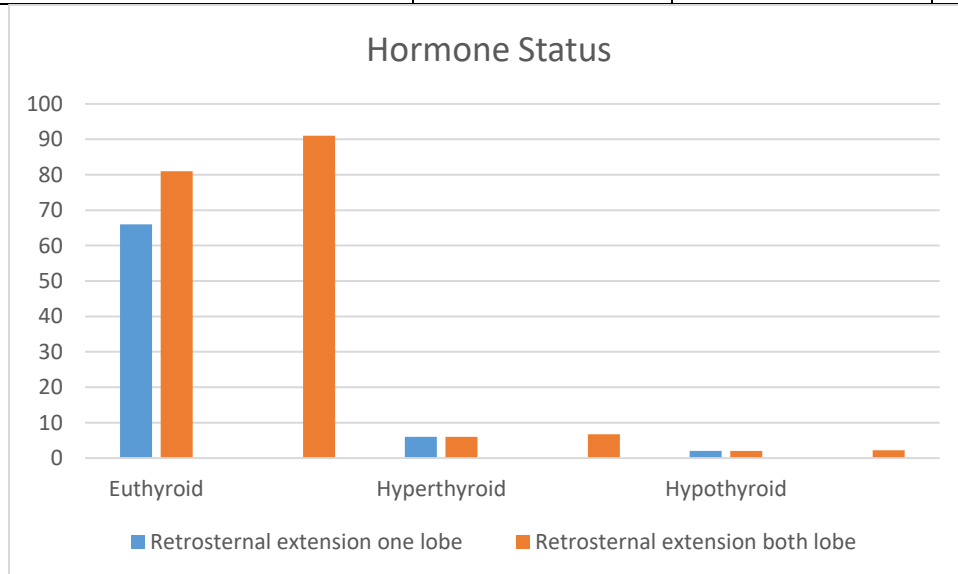
Age Groups	Females	Males	Total Percentage among group	
21 to 30 years	7.0	-	7.0	7.860%
31 to 40 years	18.0	3.0	21.0	23.590%
41 to 50 years	32.0	3.0	35.0	39.330%
51 to 60 years	20.0	-	20.0	22.480%
61 to 70 years	6.0	-	6.0	6.740%
> 70 years	-	-	-	-



Most of the patients (91.020%) were euthyroid and 6.740% patients were present to be hyperthyroid as mentioned in Table-2. This table also describes the lobe involvement in the thyroid’s retrosternal extension.

**Table-II: Hormone Status of Retrosternal Goiter**

Type of Goiter	No	Percent	Hormone Status					
			Euthyroid		Hyperthyroid		Hypothyroid	
			No	%	No	%	No	%
Retrosternal extension one lobe	15	16.85	15	-	-	-	-	-
Retrosternal extension both lobe	74	83.15	66	-	6	-	2	-
Total	89	100	81	91.02	6	6.74	2	2.24
95% Confidence limits			82.50 to 95.70		2.77 to 14.60		0.40 to 8.60	

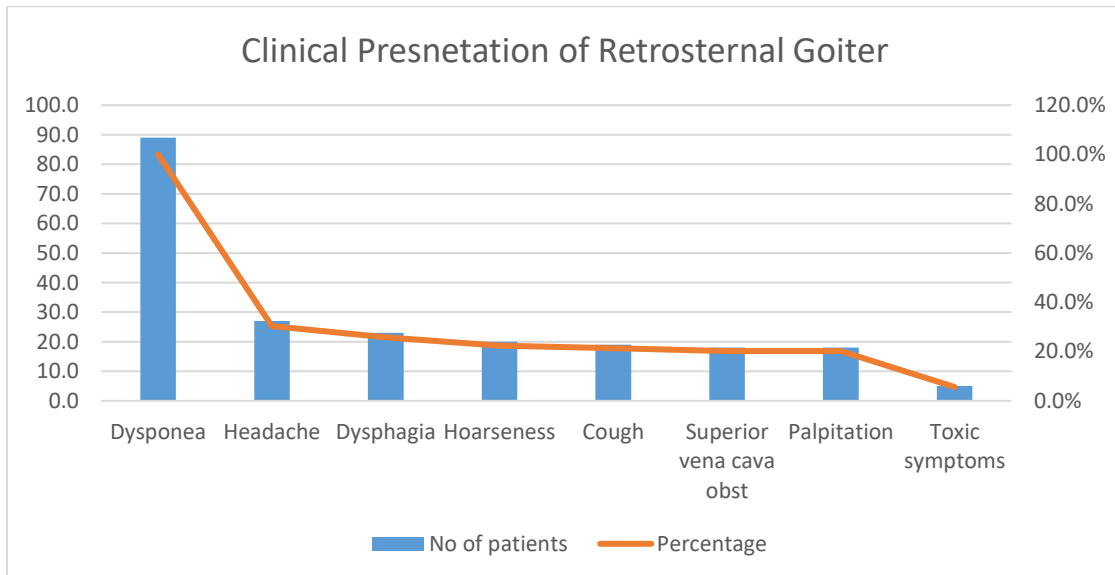


Total 83.150% patients were present with the retrosternal extension of two lobes and sixty six out of seventy four patients were euthyroid. Only 16.850% were present with retrosternal extension of single lobe and all of these patients were euthyroid. All the patients present with the thyroids retrosternal extension were having the complaint of dyspnea.

Other following complaints examined were headache in 30.330%, dysphagia in 25.840% and change of voice in 22.470% patients (Table-3).

**Table-III: Clinical Presentation of Retrosternal Goiter**

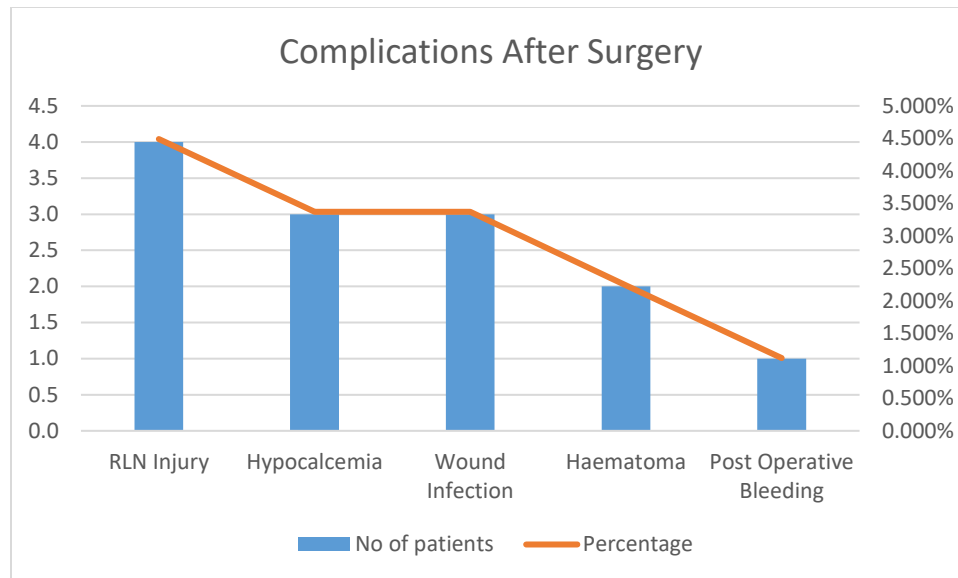
Clinical presentations	No of patients	Percentage
Dyspnoea	89.0	100.0%
Headache	27.0	30.330%
Dysphagia	23.0	25.840%
Hoarseness	20.0	22.470%
Cough	19.0	21.340%
Superior vena cava	18.0	20.220%
Palpitation	18.0	20.220%
Toxic symptoms	5.0	5.610%



After surgical intervention, recurring palsy of laryngeal nerve was the most common complication observed in 4.490% patients, hypocalcaemia was present in 3.37% patients and infection of wound was also observed in 3.37% patients (Table-4). There was successful performance of all the surgeries through surgical approach. There was no requirement of median sternotomy in any patient. There was no intra-operative or post-surgical mortality in this research work.

**Table-IV: Complications After Surgery**

Complications	No of patients	Percentage
RLN Injury	4.0	4.490%
Hypocalcemia	3.0	3.370%
Wound Infection	3.0	3.370%
Hematoma	2.0	2.240%
Post-Operative Bleeding	1.0	1.120%



### DISCUSSION:

RSG is commonly a symptomatic condition, with very low but definite danger of malignancy. Dyspnea & choking are the most common symptoms of the RSG [9-11]. In this current research work, almost all the patients were present with complaints of dyspnea or sensation of choking. Headache, hoarseness in voice and dysphagia were stated by 1/3<sup>rd</sup> patients. Same findings were also the outcome of some other research works [8, 9, and 12] from various regions of the world but the incidence of this complication is much less as compared to the findings of this research work. The most possible cause of this fact was that majority of the patients of this research work were present with goiter of larger size. There can be confirmation of the diagnosis by radiological assessments of chest, computed tomography of neck and chest, magnetic resonance imaging of mediastinum, thyroid's ecotomography and scintigraphy of thyroid. Among all these tools, MRI and CT scan are the most vital components of pre-surgical assessment and planning of surgery particularly when there is suspicion of RSG [12, 13]. The scan of thyroid may be carried out for the exclusion of other diagnosis like lymphoma which displays the functioning thyroid [14, 15]. Majority of the patients suffering from RSG were present with more than fifty years of age and the prevalence of this complication was 3 times more in females as compared to males [6, 9, and 16].

Hedayati stated the very high prevalence (30.0%) of RSG [17]. We noted that 9.1% patients of this research work were present with the retrosternal extension of thyroid. The female patients outnumbered the male

patients. The surgical intervention of this complication is possible through cervical incision and it has much acceptable danger of morbidity [17, 18].

In this current research work, there was no requirement of median sternotomy in any patient and we performed thyroidectomies through cervical incision, while Calo reported, in his research work from Italy, 3.280% sternotomy and 0.930% thoracotomy [16]. In similar manner, Ben, [12] from Israel, stated a rate of sternotomy as 9.0%, 8.30% by Chow [19] from Hong Kong and 4.0% by Arici [20] from Turkey.

There are some complications associated with surgery as intra-thoracic hemorrhage, reappearance in un-resected tissues and recurring damage of laryngeal nerve. The rate of complication as reported in international literature is lower than 5.0% in hands of specialists [11, 13, 19, and 20]. Calo [16] and Chow [19] stated the prevalence of recurring injury of laryngeal nerve in 2.20% and 2.70%, hypocalcaemia in 4.0% and 13.30%, formation of hematoma in 1.80% and 2.70% patients correspondingly. Approximately similar rate of complications were also stated by the findings of some other research works [12, 21]. In this research work, we discovered the recurring injury of laryngeal nerve (4.490%), hypocalcaemia in (3.370%), infection of wound (3.370%) and formation of hematoma (2.240%) in our patients, this finding of is almost similar with the results of international literature.

### CONCLUSION:

Retrosternal goiter is very common complication in regions present with high occurrence of goiter. Cervical approach is very easy way for its surgery.

#### REFERENCES:

1. Batori M, Chatelou E, Straniero A. Endocrinosurgery Eur Rev Med Pharmacol Sci 2007;11(4):265-268.
2. Ríos A, Rodríguez JM, Balsalobre MD, Tebar FJ, Parrilla P. The value of various definitions of intrathoracic goiter for predicting intra-operative and postoperative complications. Surgery 2010;147(2):233-238.
3. Erbil Y, Bozboru A, Barbaros U, Ozarmagan S, Azezi A, Molvalilar S. Surgical management of Substernal goiter: Clinical experience of 170 patients. Surg Today 2004;34(9):732-736.
4. Moron JC, Singer JA, Sardi A. Retrosternal goiter: A six year institutional review. Am Surg 1998;64(9):889-893.
5. Chauhan A, Serpell JW. Thyroidectomy is safe and effective for Retrosternal goiter. ANZ J Surg 2006;76(4):238-242.
6. Hanks JB. Thyroid. Townsend CM, Beauchamp RD, Evers BM, Mattox KL (Editors) In Sabiston Text Book of Surgery 17th edition, Saunders, Philadelphia 2004;961-962.
7. Ben Nun A, Soudack M, Best LA. Retrosternal thyroid goiter: 15 year experience. Isr Med Assoc J 2006;8(2):106-109.
8. Makeieff M, Marlier F, Khudjadze M, Garrel R, Crampette L, Guerrier B. Substernal goiter: Report of 212 cases. Ann Chir 2000;125(1):18-25.
9. Mc Dougall R. In vivo radionuclide tests and imaging. In Breverman LE, Utiger RD (editors) The thyroid, A fundamental and clinical text 9th edition. Lippincott Williams & Wilkins, London. 2004:318.
10. Gerard SK, Cavalieri RR. I123 diagnostic thyroid tumor whole body scanning with imaging at 6, 24 and 48 hours. Clin Nucl Med 2002;27:1-8.
11. Calo PG, Tatti A, Farris S, Piga G, Mallocci A, Nicolosi A. Substernal goiter: Personal experience. Ann Ital Chir 2005;76(4):331-335.
12. Hedayati N, McHenry CR. The clinical presentation and operative management of nodular and diffuse Substernal thyroid disease. Am Surg 2002;68(3):245-251.
13. Rodriguez JM, Hernandez Q, Pinero A, Ortiz S, Soria T, Ramirez P, et al. Substernal goiter: Clinical experience of 72 cases. Ann Otol Rhinol Laryngol 1999;108(5):501-504.
14. Chow TL, Chan TT, Suen DT, Chu DW, Lam SH. Surgical management of Substernal goiter: Local experience. Hong Kong Med J 2005;11(5):360-365.
15. Arici C, Dertsiz L, Altunbas H, Demircan A, Emek K. Operative management of Substernal goiter: Analysis of 52 patients. Int Surg 2001;86(4):220-224.
16. Chaudhary IA, Samiullah, Masood R, Mallhi AA. Complications of thyroid surgery: A five year experience at Fauji Foundation Hospital, Rawalpindi. Pak J Surg 2006;22(3):134-137.
17. Olk J. Applied anatomy of the chest wall and mediastinum. In Baker RJ, Fischer JE (Editors) Mastery of surgery 4<sup>th</sup> edition Lippincott William and Wilkins, Philadelphia. 2001;633-634.
18. Goldenberg IS, Lindskog GE. Differential diagnosis, pathology, and treatment of substernal goiter. JAMA 1957;163:527-529.
19. Singh B, Lucente FE, Shaha AR. Substernal goiter: A clinical review. Am J Otolaryngol 1994;15(6):409-416.
20. White ML, Doherty GM, Gauger PG. Evidence-Based Surgical Management of Substernal Goiter. World J Surg 2008;32:1285-1300.
21. Candela G, Varriale S, Di Libero L, Manetta F, Giordano M, Maschio A, et al. Surgical therapy of goiter plunged in the mediastinum. Considerations regarding our experience with 165 patients. Chir Ital 2007;59(6):843-51.