CODEN [USA]: IAJPBB ISSN: 2349-7750

INDO AMERICAN JOURNAL OF
PHARMACEUTICAL SCIENCES
http://doi.org/10.5281/zenodo.3777526

Available online at: http://www.iajps.com *Research Article*

ENDOVASCULAR TREATMENT OF SEVERE ISCHEMIC STROKE TO THE OBSTACLE PAIR: CORRELATION BETWEEN THE OBSTACLE AND SEVERE STENOSIS OF THE PROXIMAL INTERIOR OF THE CERVIX CAROTID DUCT

[1]Dr. Ammara Azam, [2]Dr Muhammad Waleed Sanaullah, [1]Dr. Mubashir Ahmad
[1]DHQ Hospital Rawalpindi
[2]Mayo Hospital Lahore

Article Received: February 2020 **Accepted:** March 2020 **Published:** April 2020

Abstract:
Objective: *Strokes identified with internal carotid artery torque impediments and the significant intracranial supply pathway are related by unfortunate medical result. We assessed medical viability of the endovascular method for administration of those cuts. Authors similarly considered medical outcome with respect to the type of lesions of cervical internal carotid artery: complete barrier versus extreme stenosis.*
Methods: *Authors thoughtfully examined 45 cases through intense ischemic stroke who were treated with endovascular therapy for paired injuries among July 2018 and June 2019. After isolating cases into two sets based on the type of proximal cervical ICS injury (complete impediment also simple stenosis), we reviewed sectorial information, angiographic results, and medical results. An adjusted score on the Rankin scale ≤2 was characterized as an ideal clinical outcome.*
Results: *Of 48 patients, 30 (66.5%) had a complete barrier to cervical ICA, and enduring 18 had high-grade stenosis. An effective stent remained placed in altogether cases with ideal clinical outcome (30/48.66.5%). The effective reperfusion score (thrombolysis in localized cerebral necrosis ≥2b) remained 79.7%; obstacle collection (19/30, 66.8%) versus stenosis collection (16/16, 100%) of cases. The modified mean score on the Rankin scale at 90 days was 2.36± 1.83. The ideal clinical outcome rate was higher for stenosis collection (12/16, 74.5%) than for obstacle collection (17/28, 60.4%) without measurable critical contrast (p = 0.508).*
Conclusion: *Acute endovascular cure of carotid vein pair lesions is in fact the practical and medically viable intercession that takes little account of type of lesion in proximal cervical ICA.*
Keywords: *Endovascular, Treatment, Severe Ischemic Stroke, Obstacle Pair, Correlation, Severe Stenosis, Proximal Interior, Cervix Carotid Duct.*

Corresponding author:
Dr. Ammara Azam,
DHQ Hospital Rawalpindi

QR code

Please cite this article in press Ammara Azam et al, ***Endovascular Treatment Of Severe Ischemic Stroke To The Obstacle Pair: Correlation Between The Obstacle And Severe Stenosis Of The Proximal Interior Of The Cervix Carotid Duct.,*** *Indo Am. J. P. Sci, 2020; 07(04).*

INTRODUCTION:

Stroke identified as a pair of impediments to the internal cervical carotid supply (ICA) pathway with an associated lesion of intracranial pathway happens in around 16% of intense ischemic strokes of huge vessels [1]. In clinical practice, stroke with paired impediment is a restorative test owing of their poor visualization. Intravenous thrombolysis is known for its inadequate clinical results in light of the deprived recanalization rates of about 9-10% throughout initial 3 hours, described in earlier examinations [2]. Despite the fact that endovascular therapy is being progressively implemented in intense strokes with a huge vascular barrier, there is limited evidence of the endovascular approach for strokes with a torque barrier [3].

In addition, angioplasty or subintimal recanalization of impeded ducts is a notable procedure for treating completely blocked coronary supply pathways, iliac pathways, and infection of peripheral blood vessels. This method is used occasionally in patients with sudden obstruction of the carotid vein during a severe ischemic stroke, as the concept of obstruction is extraordinary [4]. Thus, the purpose of this review was to define medical involvement of our organization, including cases through impediment related to an intense ischemic stroke, in ICS, and to examine medical viability and results of the endovascular method with little regard to the type of impediment [5].

METHODS AND MATERIALS:

Patients:

The Recognized Review Board permitted the current review; well-versed agreement was rescinded in light of idea of a review of survey. From July 2018 and June 2019, authors recognized 74 cases which experienced carotid corridor stenting for an intense ischemic stroke and who archived severe stenosis or cervical CIA impediment on attractive reverberation angiography (MR) within 12 hours of their visit to the crisis office. Based on the review of charts, photos, in addition exit reports, we explored and thoughtfully disaggregated information from 49 patients who landed within 8 hours of indications for intense ischemic stroke otherwise through a vague onset of stroke inside 12 hours of the last ordinary time "following an intracranial obstacle with extreme stenosis or impediment of cervical CIA and directed eCAS by intracranial thrombectomy. Eight cases with blood vessel dismemberment (n = 6) or a cardiogenic embolic source (n = 1) were avoided (Figure 1). In vicinity of atherosclerotic stenosis, brain tissue adjusts somewhat to ischemia, though, here remains not any adjustment of brain tissue when blood vessel testing is performed.

Stroke MRI and basic leadership:

Altogether patients experienced an MRI for intense ischemic stroke using the 3 T or 2.6 T MR scanner. The RI convention includes dispersal-weighted images through b-values of 0 and 2000, angular reverberation images (GRE), liquid constriction inversion recovery images, gadoliniumT1-weighted images and gadolinium-enhanced MR angiography of key cervical and intracranial ducts, and infusion-weighted MR images (PWI). Cases were incorporated into endovascular therapy if they had DMF lesions covering less than 33% of the CMA domain, and visual assessment revealed an infusion-weighted image / DMF image confounding factor greater than 33%. Cases remained suitable for recanalization if they had an NIHB >4 or applicable practice shortage.

Figure 1. Flow diagram presentation screening and collection of cases.

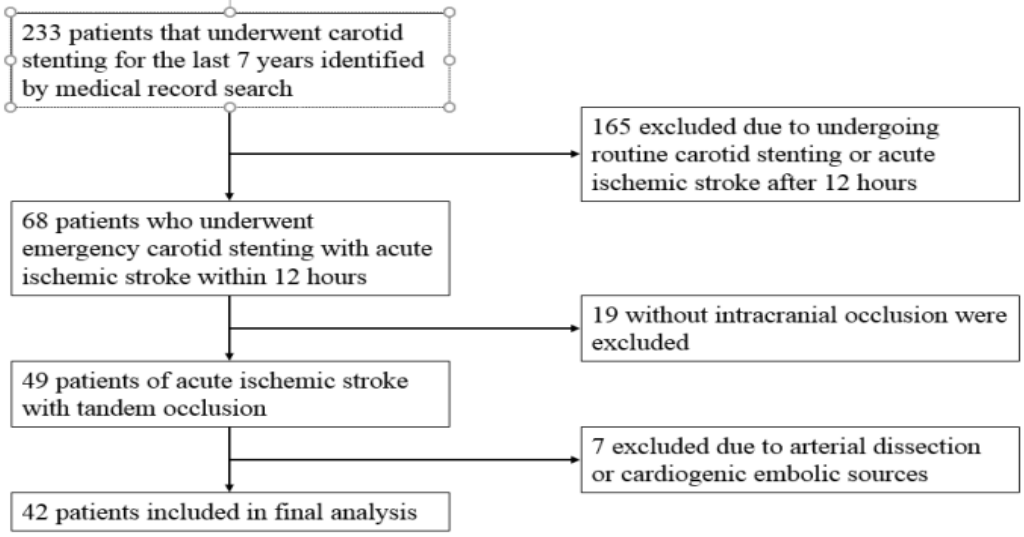

Clinic radiological assessment and follow-up:
We characterized the specialized e CAS impairment by recovering in any case the ICA flow through recanalization and evaluated the outcomes of intracranial angiography as indicated by thrombolysis in localized cerebral necrosis (TICI) scores. A TICI score ≥2b recommended successful recanalization. All post-treatment CT scans remained frequent promptly and 24 hours after method to recognize intracranial drainage or various complexities, e.g., encephaloma. Radiography was used to check the degree of localized necrosis within 3 to 5 days after the strategy. Difficulties with voluntary drainage were taken into account using the European Cooperative Acute Stroke Study III (HI-1/HI-2/PH-1/PH-2) consortium.
Factual review: The information was tested for typical dissemination using a Kolmogorov-Smirnov test. Typical dissemination factors, such as age at conclusion and essential tumour size, were analyzed using a free t-test and subsequently reported as mean SD. Correlations of absolute factors were collected using the $\chi 2$ test or, for small cells, the precise Fisher's test. Consequently, a multivariate strategic review of relapse was conducted for factors with $p < 0.1$ factual significance. Each measurable review was achieved by means of the SPSS Statistics 23 programming package.

RESULTS:

Patient qualities and consequences of endovascular cure remain recorded in Tables 1 and 2. Figures 2 and 3 show the cases of obstruction and stenosis caused by the agent.

Tolerant Populations and Outcomes of the Procedure:
The average NIHSS score for selected cases on underlying neurological assessment remained 14.3-6.8 (territory, 5-25), and altogether cases had a NIHSS score of 5 in all cases at confirmation. Of 48 cases, 30 (66.5%) had total proximal ICA and 18 (36.8%) had extreme stenosis (81-97%) on the underlying demonstrative cerebral angiography. Barriers to participation in intracranial courses were as follows: distal ICA (8/48, 17.8%), MCA M1 section (23/48, 54.5%), MCA M2 fragment (13/48, 26.9%) and ACA (2/48, 3.5%). The mean strategy time was 73.7 25.9 min (run, 40-140). The duration of the procedure was shorter in the stenotic assembly than in hindered assembly (p = 0.052). Proximal CIA stent implantation was successful in each of the 42 cases where the proximal CIA stent was used. 2 single stents: Carotid Wall Stent (closed cell type, 33/42 = 78.6%) and Acculink RX Carotid Stent (open cell type, 8/48 = 20.5%). In 38 cases (86.9%), extra intracranial mechanical thrombectomy included 24 who underwent penumbra aspiration thrombectomy in addition 14 who experienced stent return thrombectomy (Solitary: 11, Eric: 2).

Table 1. Clinic radiological features of case population.

Female	8/42 (19)
Age, years	70.9} 8.8 (46–88)
Symptom to arrival, min	189.7} 153.9 (34–605)
Initial NIHSS	13.2} 5.9 (4–24)
Cervical ICA stenosis, %	98.7} 6.4 (84–100)
Arrival to groin puncture, min	88.5} 51.2 (18–325)
MCA-M1	22/42 (52.4)
ICA-T	7/42 (16.7)

Clinical results:
33 of 48 cases (72.5%) had early neurological improvement (NIHB improvement of 5 foci in any case was contrasted and NIHB started or NIHB 0-3 on day 7 after recanalization) after hospitalization. Symptomatic intracerebral drainage (ICD) occurred in 6 cases (15.4%.) inside 24 hours of cure, 3 of whom received a recommendation for rtPA. Here remained not any momentous variance in indicative ICD among patient collections as compared to treatment of basic thrombolysis. Of the seven cases with HCI, four cases (10.6%) kicked the bucket, one of whom kicked the bucket in the light of pneumonia and the other three created intense ICH after the strategy and transmitted it independently of the decompressive craniectomy.

Table 2. Clinic radiological results after endovascular cure rendering to lesion type of cervical internal carotid artery:

	Cervical stenosis (*n* = 18)	Cervical occlusion (*n* = 30)	*p*- value
TICI 3 [n (%)]	9 (60)	10 (37)	0.43
TICI 2b-3 [n (%)]	18 (100)	20 (66.7)	0.016a
Mean mRS at 90 days	2.2	2.44	0.69
Procedure time (min)	63.7 • } 17.5	79.3 • } 27.0	.051a
Death at 90 days [n (%)]	1 (6.7)	3 (11.1)	1.00
mRS ≤2 [n (%)]	11 (73.3)	16 (59.3)	0.52

DISCUSSION:

Approximately 12-25% of cases through severe ischemic stroke have ipsilateral extracranial stenotic carotid illness, which can cause significant dead brain tissue at the sight of an obstruction to the main extra-intracranial supply route [6]. As indicated by current investigations, intense impediments of cervical CIA from time to time (51-67%) can be distinguished as impediments coupled with intracranial increases in coagulation, usually in the terminal fragment of the branches of CIA or MCA [7]. Past examinations suggest that cases with a torque impediment are less likely than those with a confined CAM impediment. Linfante, et al. report that CAM barriers have the developed degree of recanalization (89%) inside 4 days of contrasting tPA and couple barriers (32%) [8]. Vascular impediment can frequently present a circumstance similar to intense coronary artery disease, including the arrangement of anterior plaque fissure-related thrombus in non-basic basic stenosis [9]. Therefore, in intense situations, at least the couple of early occlusive lesions of CIA can reason neighboring wounds through a disordered central thrombosis that passes moderately efficiently through the wounds compared to a peripheral blood vessel condition without subintimal angioplasty [10].

Figure 2. Case sample of 79-year-old male having tandem occlusion (NIHSS score 17).

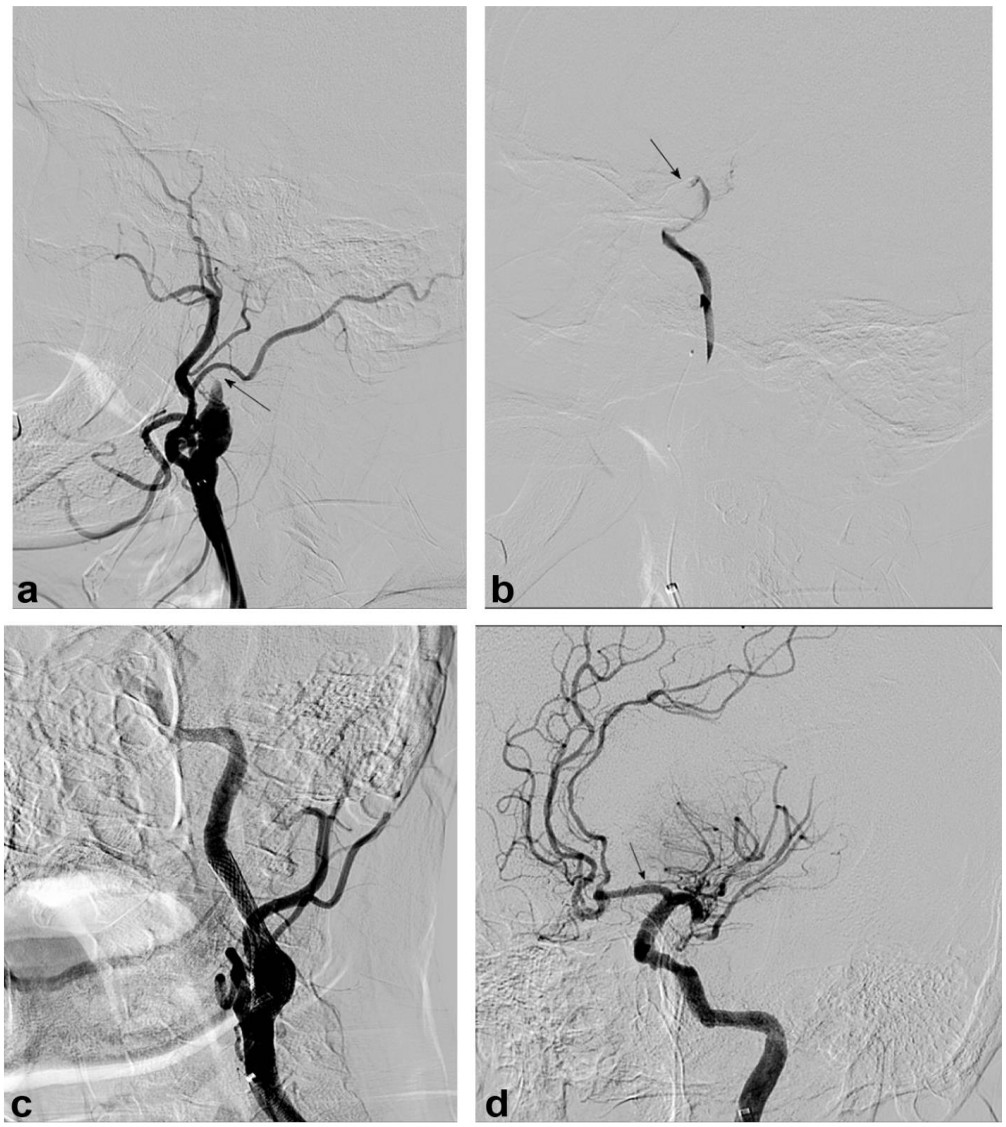

CONCLUSION:

Taking everything into account, endovascular multimodality method for intense stroke due to the couple's obstacle revealed significant viability, safety, specialized plausibility, and a high rate of high clinical outcomes (30/48, 66.5%) with little consideration of proximal cervical ICA type injury; obstacle gathering (18/30, 63.4%) versus stenosis gathering (13/18, 74.6%). In particular, collection of cervical ICA stenosis had the short methodological time and a tall recanalization rate. Additional randomized, imminent, double-blind investigations in multicenter settings should endorse our results.

REFERENCES:

1. Shao Q, Zhu L, Li T, Wang Z, Li L, Bai W, et al. Management of tandem internal carotid and middle cerebral arterial occlusions with endovascular multimodal reperfusion therapy. Int J Neurosci 2016; 126: 1077–83. doi: https:// doi. org/ 10. 3109/ 00207454. 2015. 1121387
2. Cohen JE, Gomori M, Rajz G, Moscovici S, Leker RR, Rosenberg S, et al. Emergent stent-assisted angioplasty of extracranial internal carotid artery and intracranial stent-based thrombectomy in acute tandem occlusive disease: technical considerations. J Neurointerv Surg 2013; 5: 440–6. doi: https:// doi. org/ 10. 1136/ neurintsurg- 2012- 010340
3. Puri AS, Kuhn AL, Kwon HJ, Khan M, Hou SY, Lin E, et al. Endovascular treatment of tandem vascular occlusions in acute ischemic stroke. J Neurointerv Surg 2015; 7: 158–63. doi: https:// doi. org/ 10. 1136/ neurintsurg- 2013- 011010
4. Spiotta AM, Lena J, Vargas J, Hawk H, Turner RD, Chaudry MI, et al. Proximal to distal approach in the treatment of tandem occlusions causing an acute stroke. J Neurointerv Surg 2015; 7: 164–9. doi: https:// doi. org/ 10. 1136/ neurintsurg- 2013- 011040
5. Behme D, Mpotsaris A, Zeyen P, Psychogios MN, Kowoll A, Maurer CJ, et al. Emergency stenting of the extracranial internal carotid artery in combination with anterior circulation thrombectomy in acute ischemic stroke: a retrospective multicenter study. AJNR Am J Neuroradiol 2015; 36: 2340–5. doi: https:// doi. org/ 10. 3174/ ajnr. A4459
6. Grigoryan M, Haussen DC, Hassan AE, Lima A, Grossberg J, Rebello LC, et al. Endovascular treatment of acute ischemic stroke due to tandem occlusions: large multicenter series and systematic review. Cerebrovasc Dis 2016; 41(5-6): 306–12. doi: https:// doi. org/ 10. 1159/ 000444069
7. Mueller-Kronast NH, Zaidat OO, Froehler MT, Jahan R, Aziz-Sultan MA, et al. Systematic evaluation of patients treated with neurothrombectomy devices for acute ischemic stroke: primary results of the STRATIS registry. Stroke 2017; 48: 2760–8. doi: https:// doi. org/ 10. 1161/ STROKEAHA. 117. 016456
8. Widimsky P, Koznar B, Abelson M, Blaško P, Lanzer P, Mazighi M, et al. Stent or balloon: how to treat proximal internal carotid artery occlusion in the acute phase of ischemic stroke? Results of a short survey. Cor Vasa 2016; 58: e204–e206. doi: https:// doi. org/ 10. 1016/ j. crvasa. 2016. 02. 006
9. Rubiera M, Ribo M, Delgado- Mederos R, Santamarina E, Delgado P, Montaner J, et al. Tandem internal carotid artery/middle cerebral artery occlusion: an independent predictor of poor outcome after systemic thrombolysis. Stroke 2006; 37: 2301–5. doi: https:// doi. org/ 10. 1161/ 01. STR. 0000237070. 80133. 1d
10. del Zoppo GJ, Poeck K, Pessin MS, Wolpert SM, Furlan AJ, Ferbert A, et al. Recombinant tissue plasminogen activator in acute thrombotic and embolic stroke. Ann Neurol 1992; 32: 78–86. doi: https:// doi. org/ 10. 1002/ ana. 410320113