CODEN [USA]: IAJPBB ISSN: 2349-7750

INDO AMERICAN JOURNAL OF
PHARMACEUTICAL SCIENCES
http://doi.org/10.5281/zenodo.3748876

Available online at: http://www.iajps.com Research Article

COMPUTED TOMOGRAPHY AND CARDIOVASCULAR MAGNETIC RESONANCE IN ISCHEMIC HEART ILLNESS

[1]Dr Aadarsh Naz, [2]Dr Anum Khan Rana, [3]Dr Rukhsar Farid
[1]Lahore General Hospital
[2]Mayo Hospital Lahore
[3]Jinnah Hospital Lahore

Article Received: February 2020 **Accepted:** March 2020 **Published:** April 2020

Abstract:
Ischemic coronary artery illness is very complex pathological procedure caused by improvement of coronary atherosclerosis, through downstream consequences on left ventricular myocardium. This is described by the long preclinical stage, a sudden progression of localized myocardial necrosis and increasingly persistent illness states, just like stable angina pectoris in addition ischemic cardiomyopathy. Late progress in computed tomography and cardiovascular attractive reverberation currently permit comprehensive imaging of every of those diverse periods of illness, which likely allows the monitoring of ischemic coronary artery disease over the life of the patient. Specifically, CT has become the non-invasive decision method for imaging coronary supply pathways, while CMR provides accurate valuations of myocardial perfusion, adequacy and capacity. Our current research was conducted at Services Hospital, Lahore from March 2018 to February 2019. The medical utility of those systems is gradually being confirmed by powerful preliminary randomized controlled trial information, despite fact that further selection of cardiac CT and CMR will need additional indication of medical appropriateness also cost viability.

Key words: *Computed tomography, cardiovascular magnetic resonance, ischemic heart illness.*

Corresponding author:
Dr Aadarsh Naz,
Lahore General Hospital

QR code

Please cite this article in press Aadarsh Naz et al ***Computed Tomography And Cardiovascular Magnetic Resonance In Ischemic Heart Illness,*** *Indo Am. J. P. Sci, 2020; 07(04).*

INTRODUCTION:

Ischemic coronary artery illness is very complex and protracted illness considered via obsessive changes in coronary supply pathways and in myocardium, merging different stages and clinical disorders [1]. Current non-invasive imaging through computed tomography and Cardiovascular Attractive Reverberation currently lets the detection of every of those changed stages [2]. Specifically, computed tomography allows accurate imaging of coronary atherosclerosis (sign disorders, angiography, antagonistic attributes of plaque), while CMR permits careful examination of the left ventricle (perfusion, representation of infarction, labour), although this qualification is gradually becoming obscured with innovative advances [3-4]. This article gives an overview of CT and CMR imaging in ischemic coronary artery disease and examines their comparative advantages and disadvantages. The conversation discusses their existing clinical application also possible upcoming developments, also generous limits that exist to general screening [5].

METHODOLOGY:

Our current research was conducted at Services Hospital, Lahore from March 2018 to February 2019. The medical utility of those systems is gradually being confirmed by powerful preliminary randomized controlled trial information, despite fact that further selection of cardiac CT and CMR will need additional indication of medical appropriateness also cost viability.

Pathophysiology of ischemic heart disease:

Coronary atherosclerosis is the dynamic, protracted illness characterized by a long and largely unrecognized preclinical stage. The main obsessive variation from the norm, the fat trail, can be considered to be ahead of schedule, as second decade of life. Finally, those streaks grow into atherosclerotic plaques comprising of the focal lipid center attached by a filamentous apex. As plaque develops, vessel under influence expands outward, saving both width of the lumen and the blood flow, in a procedure called "positive renovation". Subsequently, even huge plaques can be adapted without creating side effects and without being noticed during an embarrassing angiogram or stress test. In the long term, the plaque begins to grow in lumen of the vessel, which impedes blood circulation and causes myocardial ischemia and the side effects of angina pectoris. Though level of luminal stenosis is thoroughly connected to improvement of myocardial ischemia, many different aspects, just like shock on entry, erosion and disruption, also contribute to the obstruction of blood flow during specific stenosis. Most often, ACS is activated by an intense, stringy upper fissure, which disclosures tissue issue-rich thrombogenic lipid center of the blood stream. On the other hand, the disintegration of the endothelium casing the top of the tendon might lead to development of the platelet-rich thrombus, accounting for up to 32% of MI. In any event, ACS is not an unavoidable importance of disruption of the filamentous apex. Undoubtedly, subclinical plate rupture seems normal, with up to 72% of disruptive coronary plates covering histologic indication of past cracking and resulting fixation. The importance of thrombotic reply to plate disturbance remains also significant and is represented through various components counting blood thrombogenicity, flow along vessel and plate constituents.

IMAGING THROUGH CT AND CMR:

The effective usage of CT in addition CMR imaging for heart has been associated to application with static organ frameworks, primarily owing to breathtaking motion of the heart throughout cardiovascular and respiratory cycles. Nevertheless, advancements in scanner innovation nowadays offer vigorous motion correction techniques and significantly better spatial and fugitive targets, heralding the novel era of non-invasive cardiac imaging. Every innovation has various strengths and weaknesses (Table 1) that may possibly yield reciprocal data with respect to ischemic coronary artery disease.

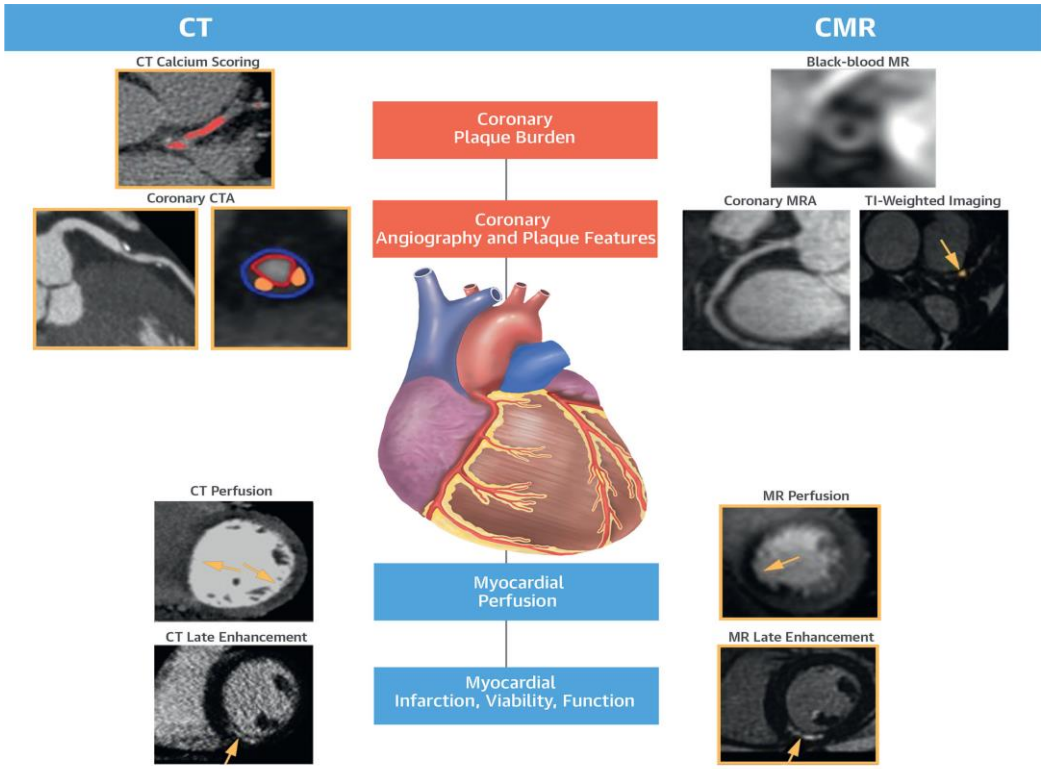

CORONARY PLAQUE BURDEN:

Assessments of coronary plaque burden remain valuable in recognizing subclinical period of infection and provide surprising predictions of opposing cardiovascular actions. Though most cases who are distinguished by imaging as having coronary atherosclerotic plaque do not experience such adverse occasions, extra plaques the subject has, advanced danger, apparently since it rises likelihood that a plaque will be disturbed and cause an occasion. Therefore, imaging of plaque disorders may be of interest both for population screening also for danger stratification in asymptomatic cases. Coronary Artery Supply Channel calcium assessment uses a realistic electro cardio-triggered, non-contracted electrocardiogram (ECG) scanner to provide accurate, baseline estimates of coronary atherosclerotic weight (Figure 1). Specifically, the CAC measures the naturally visible calcium inside those vessels by means of Angaston score.

ADVERSE PLAQUE CHARACTERISTICS

Coronary angiography by CT remains achieved by means of enhanced contrast imaging (Figure 1) and might provide accurate perception and representation of coronary atherosclerotic plaque, through the high degree of understanding in contrast to intravascular ultrasound (Figure 1). The iodine complex is perfused through a fringe cannula, and the imaging is designed to ensure improved differentiation of the coronary vessels. Imminent activation of the ECG or initiation of the revision ECG is used during solitary respiratory arrest. The use of scanners with 66 multifid detectors produces images of heart collected of different segments, while scanners with more identifiers (260 to 326) and a larger Z-hub measurement can obtain images of entire cardiovascular volume during the solitary arrest.

CORONARY ANGIOGRAPHY:

Intrusive angiography proposals unparalleled spatial and mundane objectives. Combined with intravascular ultrasound in addition optical computed tomography for intelligibility, angiography remains the highest quality level for monitoring luminous coronary stenosis. This is confirmed by widespread medical practice and research information that has affirmed dynamic, judgmental decay associated with 1, 2 and 3-vessel coronary artery illness. In addition, it offers remarkable possibility of percutaneous coronary intercession after imaging. In any case, this type of imaging is an increasingly important, invasive and complex asset. Moreover, 62% of symptomatic angiographies neglect to show the expected obstructive coronary artery illness. The use of non-invasive coronary angiography as "gatekeeper" to recover persistent catheter center determination is thus an important intrigue.

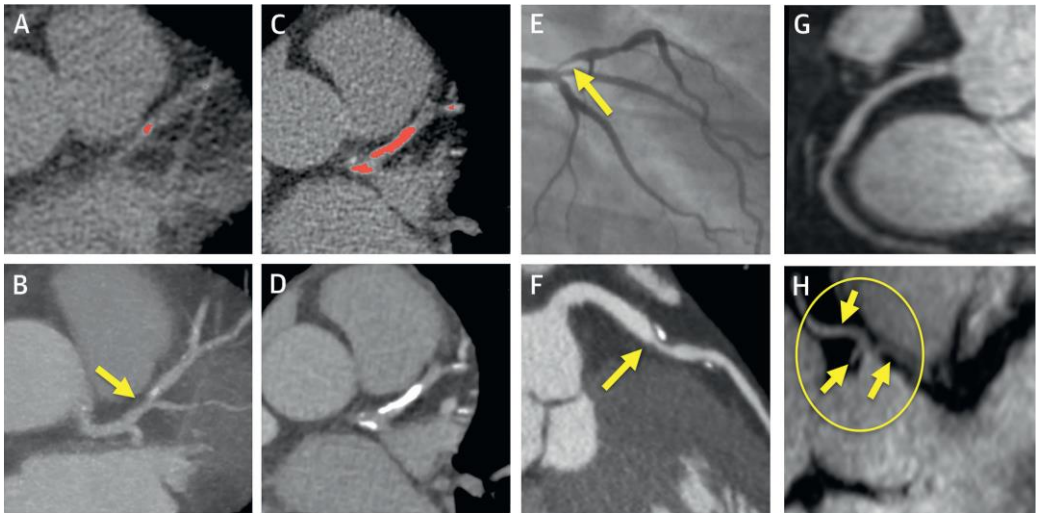

Figure 2:

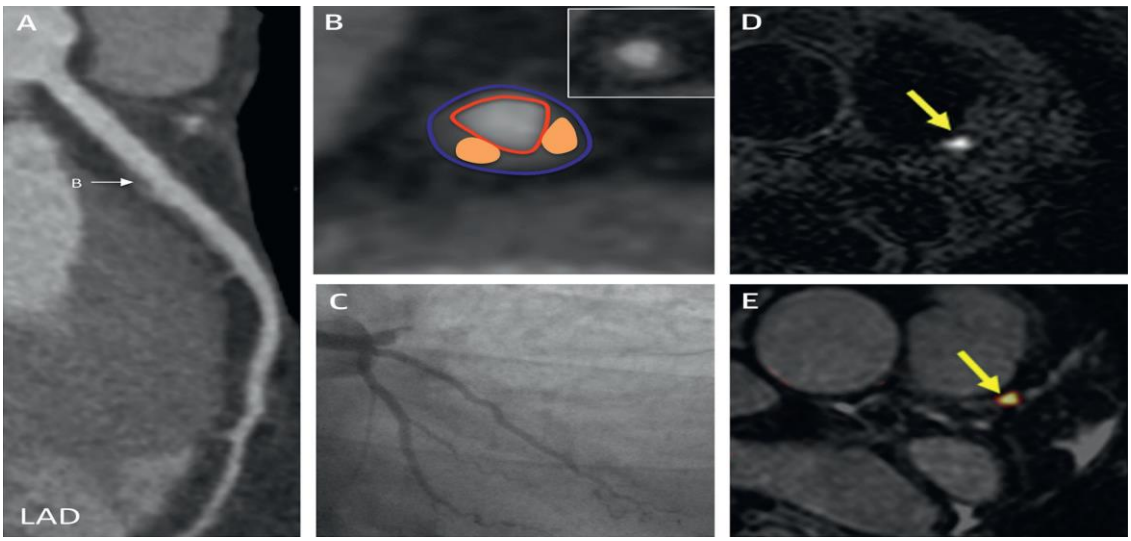

Figure 3: Valuations of High-Danger Plaque Features:

FLOW OBSTRUCTION ANDMYOCARDIAL PERFUSION:

Stenoses of coronary vascular system can restrict blood flow to myocardium, causing ischemia and anginal manifestations throughout periods of increased interest (e.g., training). In any event, the level of coronary stenosis and the degree of myocardial ischemia do not relate well; therefore, non-invasive assessments of myocardial flow control also perfusion play a significant part in cases with those manifestations. CT scanning can offer useful assessments of coronary flow deterrence using two important methodologies: imaging of myocardial perfusion and partial maintenance of flow determined by non-invasive computed tomography (NICT) [6]. CT imaging of myocardial perfusion involves the evaluation of the cross-section of the iodinated differential medium in the myocardium during vasodilatory effort (e.g., adenosine, dipyridamole, or radioneon) (Figure 3). 2 distinct conventions were recognized, namely "preview" also "dynamic" procedures.

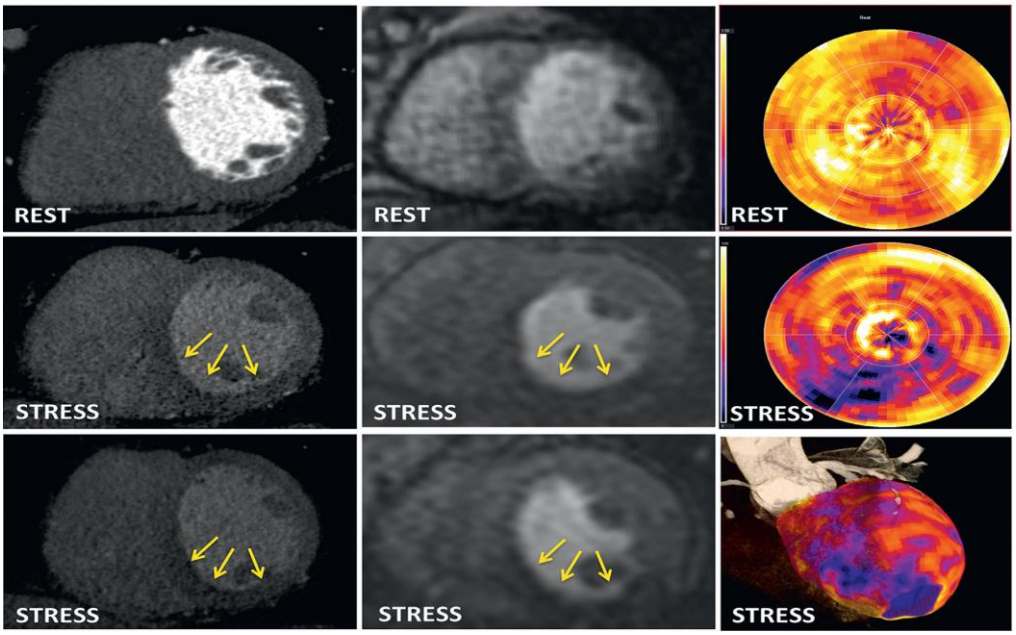

Figure 3: Myocardial Perfusion Imaging:

IMAGING OF MYOCARDIAL INFARCTION, VIABILITY AND FUNCTION:

Proximity of the difference in diligence on late imaging might be applied to distinguish scarring or fibrosis in left ventricular myocardium, by means of CMR and CT scanning. Iodine CT differentiates operators and gadolinium wastes time at locations of fibrosis or myocardial scarring more progressively than territories of ordinary solid myocardium [7]. More extensive signs/constrictions are then detected in those territories if imaging is performed at delayed time foci, thus educating on both proximity and example of myocardial scarring in the left ventricle. The main representation of the location of the infarction using a late update was, in fact, performed by CT scan in 1978. More recently, the late CT update has shown moderate analytical accuracy in infarction recognition (affectability 53% to 79%, exploitation 87% to 100%), with a few methods (e.g., low cylinder tension, dual vitality imaging, and volume of increased complexity) being studied to improve scar perception (Figure 4). In any case, the second-order image quality and the associated radiation presentation imply that the late enhancement procedures at RMC are already appreciated [8].

Barriers to widespread clinical adoption:

CT and CMR scans provide complete and accurate imaging of cases having ischemic coronary artery illness. The prognostic ramifications of these assessments are currently well recognized, with tests under development demonstrating aptitude of those modalities to modify persistent administration and recover medical results just like cardiac opportunity also death. In any event, there remain some limitations to their overall clinical selection. CT imaging is expected to continue to decrease radiation portions, particularly with respect to infusion, reasonableness, and practical valuations [9]. The usage of CT imaging in the crisis division will need ready entree to scanners and accessibility of prepared technologists also correspondents. For patients with stable chest pain, here is presently very extensive choice of non-invasive imaging modalities available, and more research is needed to decide how greatest to consolidate CT scanning into case's examination [10].

CONCLUSION:

CT also CMR imaging of coronary veins in addition left ventricular myocardium offers comprehensive and thorough valuations of ischemic coronary artery illness from its most acute preclinical stages to concluding periods of peak cardiovascular disappointment. These epic imaging modalities are now influencing medical consideration, and further advances are expected to expand their usefulness and work. Specifically, computed tomography has become the non-invasive decisional trial for imaging coronary vascular system, demonstrating clinical viability in many very large RCTs. Paradoxically, CMR is of great interest for evaluating left ventricular myocardium, particularly their skill to explore myocardial perfusion and tissue structure without use of ionizing radiation. With rapid progress and innovation, the clinical utility of mutually methodologies is set to enlarge even

further, despite the fact that their widespread uptake will require other RCTs with better medical results and cost adequacy.

REFERENCES:

1. Forouzanfar MH, Moran AE, Flaxman AD, Roth G, Mensah GA, Ezzati M, Naghavi M, Murray CJ. Assessing the global burden of ischemic heart disease, part 2: analytic methods and estimates of the global epidemiology of ischemic heart disease in 2018.**Glob Heart**. 2012; 7:331–342. doi: 10.1016/j.gheart.2012.10.003CrossrefMedline Google Scholar
2. Braunwald E. Cardiomyopathies: an overview.**Circ Res**. 2018; 121:711–721. doi: 10.1161/CIRCRESAHA.117.311812LinkGoogle Scholar
3. Ferreira VM, Schulz-Menger J, Holmvang G, Kramer CM, Carbone I, Sechtem U, Kindermann I, Gutberlet M, Cooper LT, Liu P, et al.. Cardiovascular magnetic resonance in nonischemic myocardial inflammation: expert recommendations.**J Am Coll Cardiol**. 2018; 72:3158–3176. doi: 10.1016/j.jacc.2018.09.072CrossrefMedlineGoogle Scholar
4. Karamitsos TD, Piechnik SK, Banypersad SM, Fontana M, Ntusi NB, Ferreira VM, Whelan CJ, Myerson SG, Robson MD, Hawkins PN, et al.. Noncontrast T1 mapping for the diagnosis of cardiac amyloidosis.**JACC Cardiovasc Imaging**. 2013; 6:488–497. doi: 10.1016/j.jcmg.2012.11.013CrossrefMedlineGoogle Scholar
5. Maron MS, Maron BJ, Harrigan C, Buros J, Gibson CM, Olivotto I, Biller L, Lesser JR, Udelson JE, Manning WJ, et al.. Hypertrophic cardiomyopathy phenotype revisited after 50 years with cardiovascular magnetic resonance.**J Am Coll Cardiol**. 2009; 54:220–228. doi: 10.1016/j.jacc.2009.05.006CrossrefMedlineGoogle Scholar
6. Smedema JP, Snoep G, van Kroonenburgh MP, van Geuns RJ, Dassen WR, Gorgels AP, Crijns HJ. Evaluation of the accuracy of gadolinium-enhanced cardiovascular magnetic resonance in the diagnosis of cardiac sarcoidosis.**J Am Coll Cardiol**. 2005; 45:1683–1690. doi: 10.1016/j.jacc.2005.01.047CrossrefMedlineGoogle Scholar
7. Bruder O, Schneider S, Nothnagel D, Dill T, Hombach V, Schulz-Menger J, Nagel E, Lombardi M, van Rossum AC, Wagner A, et al.. EuroCMR (European Cardiovascular Magnetic Resonance) registry: results of the German pilot phase.**J Am Coll Cardiol**. 2009; 54:1457–1466. doi: 10.1016/j.jacc.2009.07.003CrossrefMedlineGoogle Scholar
8. Yancy CW, Jessup M, Bozkurt B, Butler J, Casey DE, Drazner MH, Fonarow GC, Geraci SA, Horwich T, Januzzi JL, et al.. 2013 ACCF/AHA guideline for the management of heart failure: executive summary: a report of the American College of Cardiology Foundation/American Heart Association Task Force on practice guidelines.**Circulation**. 2013; 128:1810–1852. doi: 10.1161/CIR.0b013e31829e8807LinkGoogle Scholar
9. Paterson I, Wells GA, Ezekowitz JA, White JA, Friedrich MG, Mielniczuk LM, O'Meara E, Chow B, DeKemp RA, Klein R, et al.. Routine versus selective cardiac magnetic resonance in non-ischemic heart failure - OUTSMART-HF: study protocol for a randomized controlled trial (IMAGE-HF (heart failure) project 1-B).**Trials**. 2013; 14:332. doi: 10.1186/1745-6215-14-332CrossrefMedlineGoogle Scholar
10. Felker GM, Thompson RE, Hare JM, Hruban RH, Clemetson DE, Howard DL, Baughman KL, Kasper EK. Underlying causes and long-term survival in patients with initially unexplained cardiomyopathy.**N Engl J Med**. 2000; 342:1077–1084. doi: 10.1056/NEJM200004133421502CrossrefMedlineGoogle Scholar.