CODEN [USA]: IAJPBB ISSN: 2349-7750

INDO AMERICAN JOURNAL OF
PHARMACEUTICAL SCIENCES
http://doi.org/10.5281/zenodo.3752821

Available online at: http://www.iajps.com *Research Article*

ARTENIMOL-PIPERAQUINE IN CHILDREN WITH UNCOMPLICATED IMPORTED FALCIPARUM MALARIA FEVER: THE EXPERIENCE OF AN IMMINENT COMPANION

[1]Dr Afsah Javaid, [2]Dr. Khawar Majeed, [3]Dr. Iman Bashir
[1]THQ Khushab
[2]Incharge Medical Officer, BHU Chak 55/NP
[3]WMO at BHU Siddique Abad, Kufri Khushab

Article Received: February 2020 **Accepted:** March 2020 **Published:** April 2020

Abstract:
Background: *Regardless of the fact that intestinal diseases remain one of the major threats to overall prosperity among tropical regions, pediatricians in addition emergency experts in non-endemic nations have a partial understanding of introduced wilderness fever in offspring, often due to misdiagnosis and lack of treatment. In addition, the usual medicines (atovaquone-proguanil, quinine, mefloquine) are incomplete either through long-term cured or through responses. Since 2016, World Health Organization has approved the use of oral artemisinin-based mixtures for the treatment of basic Plasmodium falciparum intestinal diseases universal. The assistances of atenolol-piperaquine in young people have been approved in widespread nations, but involvement in introduced intestinal diseases is limited.*
Methods: *This routine pediatric observational assessment took place in the crisis ward of Mayo Hospital, Lahore, from August 2018 to July 2019. The obstruction and appropriateness of atenolol-piperaquine in children was evaluated, taking into account the WHO fuse comparison criteria: P. falciparum positive on a tinny or dense blood slur; also non-investment grade - severity.*
Results: *Of the 85 children selected for this audit, cured through atenolol-piperaquine remained effective in 824 offspring (97.6%). None of cases were Spartan and altogether remained measured mild cases without critical medical effect. This also applies to cases of cardiovascular opposition, with little consideration given to the baseline increase in mean QTc interval after treatment.*
Conclusion: *Artemio-piperaquine has a satisfactory range and profile of opposition as the first-line cure for children with uncomplicated introduced falciparum stomach disease and requires only three oral administrations of drug once daily. Further investigation against artemether-lumefantrine or atovaquone-proguanil could remain useful to highlight outcomes of the current audit.*
Keywords: *Introduced malaria, Offspring, Artemio–piperaquine, QTc interval.*

Corresponding author:
Afsah Javaid,
THQ Khushab

QR code

Please cite this article in press Afsah Javaid et al, ***Artenimol-Piperaquine In Children With Uncomplicated Imported Falciparum Malaria Fever: The Experience Of An Imminent Companion.,*** *Indo Am. J. P. Sci, 2020; 07(04).*

INTRODUCTION:

Intestinal disease is a febrile condition caused by the protozoan parasite Plasmodium, transmitted to humans through the bite of infected female Anopheles mosquitoes. The basic species known to contaminate individuals are Plasmodium falciparum, which causes the most scandalous cases, Plasmodium Ivax, the intestinal infection Plasmodium, Plasmodium ovule and Plasmodium know lesi. Wood fever remains one of the main threats to the general prosperity of tropical regions. Although the incidence of wood fever has decreased since 2010, there is no decisive breakthrough in the reduction of intestinal disease cases for the period 2015-2017. Safety against artemisinin is an important test and the neutralization movement is still far from yielding lasting benefits. In the middle of the 21st century, artemisinin-based mixtures were known in Africa to extend the protection of P. falciparum against the common opponent of antimalarial drugs and to improve the adequacy of treatment. Qinghao has been used for some time by Chinese botanists for the treatment of fever and the dynamic part of the plant was cleaned in China in 1976. Artemio-piperaquine (AP) was approved for clinical use in adult and pediatric patients in France in 2015. Although Artemio-piperaquine has been approved in endemic countries for young people, its use in imported intestinal diseases is still limited, with little creation in adults and none in children. It is striking that two cases of disillusionment in the treatment of African swine fever have recently been discovered in adults. The possible results of long-term treatment of children with imported falciparum wild fever, without confusion with fowl fever, are currently under investigation.

METHODOLOGY:

This inevitable routine pediatric observation assessment took place in the crisis ward of Mayo Hospital in Lahore from August 2018 to July 2019. All children with fever, or with a history of fever, returning from a country where intestinal disease is endemic in the last 34 months, were screened for wild type fever (thin and thick blooded and spreading). The WFU was represented by fever or a background marked by fever, a thin or thick blood smear positive for P. falciparum, and the absence of the World Health Organization (WHO) - which described its severity. Control of parasitemia > 5%, when it was a separate outcome, was not considered a severity paradigm, as proposed in the 2009 French recommendations. At the time of leaving the clinical center, the mentors received the rest of the treatment in vain, in order to control it in their youngsters at home for 3 days, at regular intervals, on an unfilled stomach. A 13-lead electrocardiogram was performed before the onset of BP and at the first follow-up visit. The QTc interval was monitored by a practicing cardio-hymnologist. A consolidated T-test was performed to determine if there was a large real difference in mean QTc interval near the start of BP treatment. After treatment, the initial focus was on facilities and research (counting both slight and large differences) between days 4 and 9, with a second time on day 30. Caregivers were trained in the examination and gave their consent.

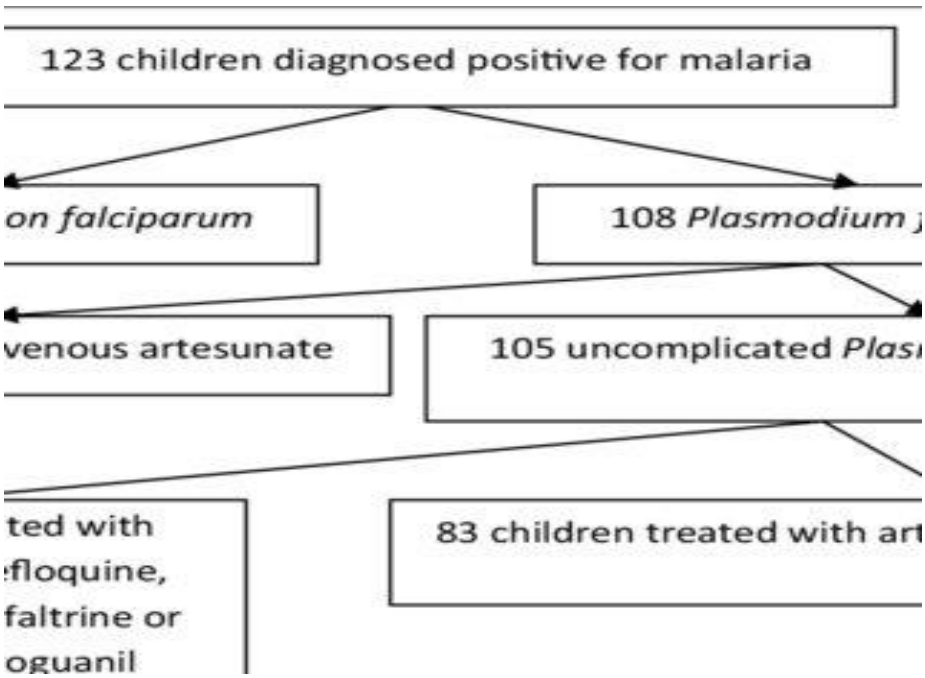

Fig. 1: Flow chart of offspring presenting with malaria at Mayo Hospital:

RESULTS:

During the evaluation period, intestinal disease occurred in 132 young people, of whom 5 had extreme wild fever and 17 did not have wild fever of the falciparum type. 25 young people with UFD were treated with drugs other than AR and were excluded from the evaluation (Fig. 1). A total of 85 young people, including 40 young women and 45 young men, met the assertion criteria and were included in the last evaluation. The normal age was 10.5 years (14 months-17.9 years). The average load of the population examined was 35.6 kg, with an interquartile range (IQR) of [23.26-49 kg]. All patients were from sub-Saharan Africa and had visited their families in their country of origin, usually Côte d'Ivoire (43%) and Mali (31%). One young person experienced a setback on day 23. His mother announced that he had expelled the two donated pieces on the third and fourth day at home, but this was not reported on the next visit on the fourth day, when the young person's parasitemia was negative. The youth received 3 added segments of AP by nasogastric tube in facility, and subsequent minute evaluations at 3 days and 30 days were negative. An adolescent from Côte d'Ivoire returned home before the 28-day registration. In a telephone conversation two months after treatment, guards officially certified that the child had been clinically well without a feverish scene. The average hemoglobin level was 11.75 g/dL (temporary conviction 12.34-12.17; region 6-14.6) and 11.67 g/dL (temporary insurance 11.4-14.2) at the time of the announcement and at D32, independently. Nine children (12.86%) went out after one of the parties; each of them accepted the PA as shown in the show without spitting again. It is absurd to expect to be able to choose whether the lifting was due to an unfriendly drug response or a sign of wild fever, or a mixture of both. Six patients who underwent QTc pre-treatment (less than 450 ms), had QTc interval prolongation at 460 ms in 5 cases and 490 ms in one case, with no response. This should remain distinguished that none of 85 children selected for this review were taking any drug other than paracetamol also consequently threat of a match through atenolol piperaquine could remain ruled out.

DISCUSSION:

To date, in France, a course of AP has been successful in 83/84 young people (97.83%) with uncomplicated wild P. falciparum fever. One young person experienced a recrudescence, probably recognized by the rapid rejection of two regulated parties at home, and remained thus relieved afterwards accepting three added parts of AP [6]. Taking this into account, the AP reached the WHO recommended sufficiency (>96%) at the present time. Unpleasant events were rare and switching to another sedating antimalarial drug was not necessary in young people [7]. Aryl-amino fluid mixtures, including piperaquine, can bring out the QTc interval. All but one of the children were tried between days 24 and 59. None of the young people had clinically perceptible cardiovascular problems [8]. One of the youths returned to Africa prior to the D28 test, but the guardians officially stated that the youth was clinically healthy three months after treatment. The issue of satisfactory interim prolongation of the treatment-activated QTc interval is still outstanding [9]. It is heartening to note that, in a progressive meta-examination of children accepting sporadic preventive treatment of wood fever by AP, Gutman et al. found that manifestations of real enmity remained a lesser amount of common through AP than with various medicines otherwise false treatment; and that here remained not any substantial useful rise in QTc interval prolongation with expanded treatments of AP [10].

CONCLUSION:

Imported wood fever in young people is an extraordinary disease, the basic organization of which by the two pediatricians and the general specialists is sporadically risky, requiring simple and long-lasting treatment. Oral artemisinin-based mixtures have significantly improved the treatment of intestinal diseases in young people living in otherwise travelling to endemic states in addition are currently main situation medicines.

REFERENCES:

1. Centers for Disease Control and Prevention. CDC – DPDx – Malaria [Internet]. [cited 30 Mar 2019]. Available from: https://www.cdc.gov/dpdx/malaria/index.html
2. Monge-maillo B, López-vélez R. Migration and malaria in Europe. Mediterr J Hematol Infect Dis. 2012;4(1):e2012014.PubMedPubMedCentralCrossRefGoogle Scholar
3. La Hoz RM, Morris MI. Tissue and blood protozoa including toxoplasmosis, Chagas disease, leishmaniasis, *Babesia*, *Acanthamoeba*, *Balamuthia*, and *Naegleria* in solid organ transplant recipients – guidelines from the American Society of Transplantation Infectious Diseases Community of Practice. Clin Transpl. 2019;33(9):e13546. Available from: https://onlinelibrary.wiley.com/doi/abs/10.1111/ctr.13546Google Scholar
4. Elsharif M, Imam M, Elsharif E, Malik E, Omran M. Malaria incidence among kidney-transplanted recipients in an endemic malaria area, Sudan. Saudi J Kidney Dis Transplant. 2012;23(5):1099. Available from: http://www.ncbi.nlm.nih.gov/pubmed/22982935CrossRefGoogle Scholar

5. WHO. WHO | WHO malaria terminology [Internet]. WHO. World Health Organization; 2019 [cited 5 Jun 2019]. Available from: https://www.who.int/malaria/publications/atoz/malaria-terminology/en/
6. Pierrotti LC, Levi ME, Di Santi SM, Segurado AC, Petersen E. Malaria disease recommendations for solid organ transplant recipients and donors. Transplantation. 2018;102(2S Suppl 2):S16–26. Available from: http://www.ncbi.nlm.nih.gov/pubmed/29381574PubMedCrossRefPubMedCentralGoogle Scholar
7. Grossi PA, Fishman JA. Donor-derived infections in solid organ transplant recipients. Am J Transplant. 2009;9(Suppl 4):S19–26.PubMedCrossRefPubMedCentralGoogle Scholar
8. Martín-Dávila P, Fortún J, López-Vélez R, Norman F, De Oca MM, Zamarrón P, et al. Transmission of tropical and geographically restricted infections during solid-organ transplantation. Clin Microbiol Rev. 2008;21(1):60–96. Available from: http://www.pubmedcentral.nih.gov/articlerender.fcgi?artid=2223841&tool=pmcentrez&rendertype=abstractPubMedPubMedCentralCrossRefGoogle Scholar
9. Kute VB, Vanikar AV, Shah PR. Postrenal transplant Plasmodium vivax malaria: neglected and not benign. Parasitol Res. 2013;112(4):1791–3.PubMedCrossRefPubMedCentralGoogle Scholar
10. Kurth F, Develoux M, Mechain M, Malvy D, Clerinx J, Antinori S, et al. Severe malaria in Europe: an 8-year multi-centre observational study. Malar J. 2017;16(1):57. Available from: http://malariajournal.biomedcentral.com/articles/10.1186/s12936-016-1673-zPubMedPubMedCentralCrossRefGoogle Scholar.