



CODEN [USA]: IAJPBB

ISSN: 2349-7750

**INDO AMERICAN JOURNAL OF
PHARMACEUTICAL SCIENCES**<http://doi.org/10.5281/zenodo.846838>Available online at: <http://www.iajps.com>

Research Article

**HISTOPATHOLOGICAL INVESTIGATION ON HIGH FAT
DIET INDUCED DEFORMATIES IN RAT LIVER AND HEART:
ROLE OF *RHINACANTHUS NASUTUS* (L) KURZ
METHANOLIC LEAF EXTRACT IN ALLEVIATION OF
TISSUE DEFECTS****B. Suman., M. Venkataswamy., B.J. Divya., B.Eswari and K. Thyaga Raju***

Department of Biochemistry, Sri Venkateswara University, Tirupati, Andhra Pradesh, India.

Abstract:

Rhinacanthus nasutus (L) belongs to Acanthaceae family, widely distributed in some parts of sub-continent, in the region of Southeast Asia and China, and it is cultivated particularly as a medicinal plant which has been used in treatment and prevention of diverse diseases as folklore medicine. Different parts of R.nasutus are also used in traditional medicine for the treatment of eczema, pulmonary tuberculosis, herpes, hepatitis, diabetes, hypertension and skin diseases. The aim of present study was to analyze the histological changes of rat liver and heart by inducing high fat diet and HFD+RN active principle extract in dosage and time dependent manner. The results has indicated that HFD+RN showed infiltration, recovered sinusoids space and increased size of hepatocytes, Orlistat+High fat diet(OL+HFD) treatment, as control suppressed formation of lipid droplets and necrosis, when compared with high-fat diet fed rats and in heart the HFD group has caused the necrosis due to excess feed and inflammation. The OL+hfd treated group found to contain damage to cardiac myocytes and interstitium. The present study conclude that the high fat diet+ R.nasutus (HFD+RN) rat group showed recovery from the damage of infiltration, sinusoids and necrosis in liver and heart tissues.

Key Words: *Rhinacanthus nasutus, Liver, Heart, Histology, High Fat Diet***Corresponding Author:****K. Thyaga Raju***

Department of Biochemistry,

Sri Venkateswara University,

Tirupati, Andhra Pradesh, India.

E-mail : thyagarajuk_1999@yahoo.com

QR code



Please cite this article in press as K. Thyaga Raju et al, *Histopathological Investigation on High Fat Diet Induced Deformaties in Rat Liver and Heart: Role of Rhinacanthus Nasutus (L)Kurcz Methanolic Leaf Extract in Alleviation of Tissue Defects*, Indo Am. J. P. Sci, 2017; 4(08).

INTRODUCTION:

The widespread use of herbal remedies and health care preparations, as those described in ancient texts such as Bible and the Vedas, and obtained from commonly used traditional herbs and medicinal plants, has been traced to the occurrence of natural products with medicinal properties. Medicinal plants are the oldest health-care products have importance depending on the ethnological, medical and historical background of each country. These are used in pharmacological research for drug development, and are used directly as therapeutic agents, depending on their active compounds. The plants contain both organic and inorganic constituents and are found to be rich in one or more individual elements, to serve as medicine. Over three-quarters of the world population relies mainly on plants and plant extracts for health care. Isolated and purified compounds, in contrast may lose their biological activity or fail to behave in the same way as in the complex matrix that the original item of food represents. Trace elements play a very important role in the formation of the active, chemical constituents present in medicinal plant. The drugs are derived from the whole plant or from different parts like leaves, stem, bark, root, flower, seed, etc [1].

In our study the medicinal plant chosen is *Rhinacanthus nasutus*, it belongs to *Acanthaceae* family. *R.nasutus* is widely distributed in some parts of sub-continent, in the region of Southeast Asia and China [2]. The *R.nasutus* (Nagamalle) is cultivated as a medicinal plant for treatments and prevention of diverse folklore diseases such as medicines eczema, pulmonary tuberculosis, herpes, hepatitis, diabetes, hypertension and several skin diseases [3]. It also has potential effects in treatment of diseases like cancer, liver disorders, skin diseases, peptic ulcers, helminthiasis, scurvy, inflammation and obesity [4,1].

Histology is the study of tissues which gives the insight into the functioning of tissues and organs and is the study of changes in cell environment anatomy. This study pave a way to understand the pathological conditions of the animal and gives a clear picture in understanding how the drugs could cause injury to the tissue. These studies, shall measure cell-size, mean cell size and total cell number, for characterization of the adipose tissue growth.

Histopathological studies would help in assessing the effect of drug toxicity at the initiation stage in organs of an organism. The food in oxidation is converted to oxidized trace compound, which may induce modification of tissues such as liver, kidney, heart, lung, brain and pancreas in avians and rodents [5,6]. Similar to it upon exposure of molecular oxygen to PUFA convert it into various oxidized molecules.

The aim of the present study was to study the histological changes of rat liver and heart upon on treatment of HFD and RN active compound with dosage and time dependent manner.

MATERIALS AND METHODS:

Animals

Male Wistar rats (110 - 130 gm) obtained from Sri Venkateswara Animal Agency, Bangalore, India. The animals were made to acclimatize to laboratory conditions and were fed with pellet diet and water *ad libitum*. (12 h light/dark, temp. 26 ± 2 °C; relative humidity $60 \pm 10\%$). Rats were housed throughout the experiment period in polypropylene cages containing paddy husk (procured locally) as bedding. All the animals were sacrificed after completion of every treatment by the Institutional animal ethical committee guidelines SV University, Tirupati (Resolution No: 41/2012-13/(i)/a/CPCSEA/IAEC/SVU/ KTR-BS dt 08-07-2012).

Plant material and Preparation of extract

Fresh leaves of *R. nautus* were collected from Tirupati and Tirumala hills, A. P., India. The plant was botanically authenticated by Taxonomist of the Department of Botany, Sri Venkateswara University, Tirupati, AP., India. A voucher number SVUBH/579 and specimen was deposited in the department of Botany for future reference.

Fresh plant material were washed under running tap water, and dried under shade dry. Leaves of *R.nasutus* were shade dried and milled to fine powder using a mechanical grinder. The powdered plant material was macerated with methanol. The extract was then filtered filter paper (WhatmanNo.1) spread on funnel and under reduced pressure concentrated using rota evaporator at 40°C using a circulatory water bath. The concentrate was obtained to a dark molten mass then layered on glass bottle and was freeze dried at 4°C for further study.

Experimental design

After acclimatization the animals were divided into four groups of six rats each

- Group I: Control rats pellet ad libitum with water
- Group II : High Fat Diet fed (HFD)
- Group III:High Fat Diet +Standard (Orlistat) fed(HFD+OL)
- Group IV : HFD+ RN fraction fed.

The orlistat at 25mg/kg body weight and RN fraction extract 200mg/kg body weight were administered for 6 weeks, once a day, to the respective treatment groups. The dose was suspended in distilled water and given orally using a gastric gavage. For the

present study the dose was fixed at 25 mg/kg body weight based on the existing literature in the field [7].

Histopathological analysis

The liver and heart were isolated from control and treated rats and they were gently rinsed with physiological saline to remove blood and debris adhering to them. They were fixed in Bouin's solution until processing. The tissues were washed with running tap water, overnight to remove Bouin's solution. After dehydrating through a graded series of alcohols, the tissues were cleared in methyl benzoate and embedded in paraffin wax. Sections were cut at 6 μ thickness and stained with haematoxylin [8]. Histological examinations of the tissues were followed according to Humason 1972[9] and the specimens were observed under the light microscope.

RESULTS:

The feeding of high-fat diets induced obese rat's histological analysis of liver and heart tissues was (haematoxylin and eosin staining) showed

architecture in the normal diet rats. The high-fat diet rats showed more profound steatosis with macro vesicular fat accumulation and necrosis. HFD alone showed hepatocytes with centrally placed prominent nucleus, sinusoids and with central vein (Fig-1 B). Histological analysis of liver tissues of rat treated with orlistat+HFD showed severe condition of central vein, hyperplastic nuclei, more granularity of the cytoplasm, cloudy swelling changes (Fig-1C). HFD+RN of rat liver tissue showed infiltration, recovered sinusoids space and increased size of hepatocytes (Fig-1 D). RN+HFD and OL+HFD treatment rats suppressed formation of lipid droplets and necrosis, when compared with high-fat diet fed rats.

In heart the HFD group is caused the damage to the tissue due to excess feed causes the necrosis and inflammatory cell. The OL+HFD group causes the damage to cardiac myocytes and interstitium. The HFD+RN group shows and recovered the damage of infiltration, sinusoids (Fig-2A-D).

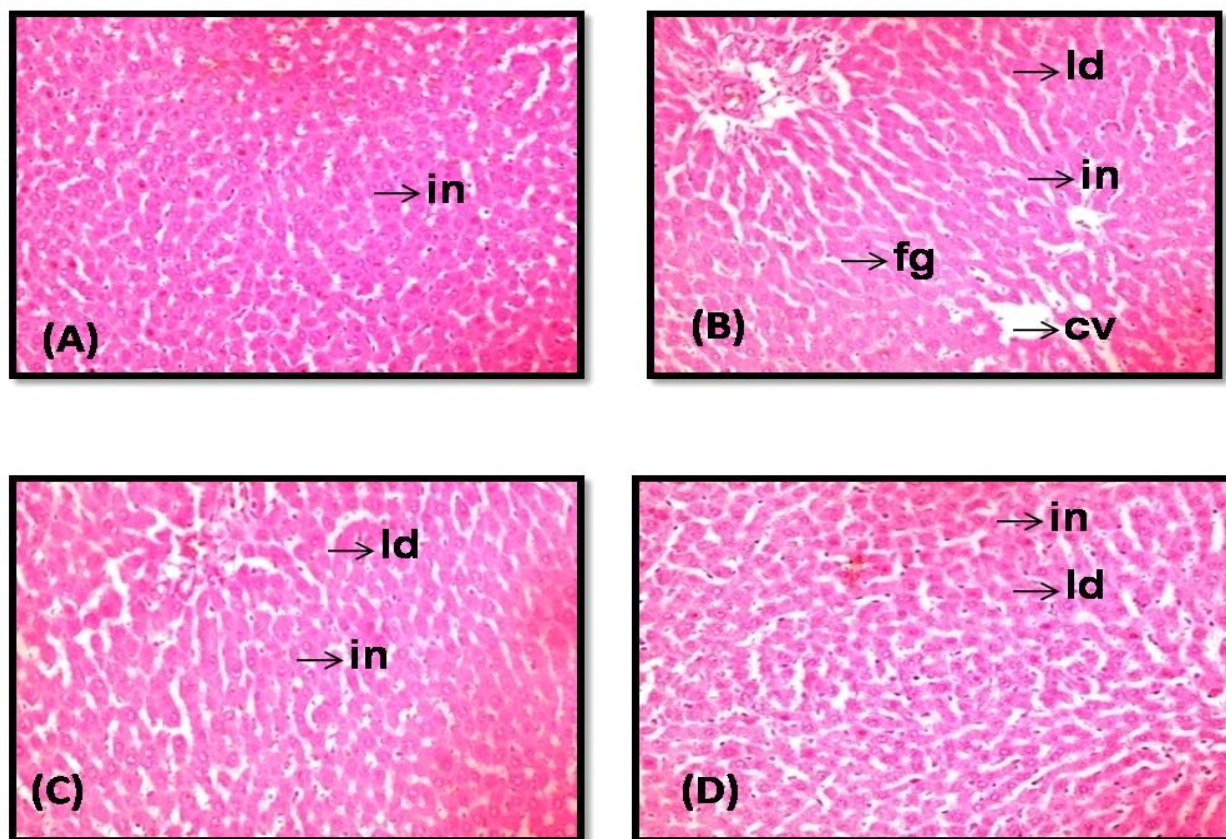


Fig-1: Effect of *R.nasutus* on the histological morphology of liver using hemotoxylin and eosin staining

(A)Control group (B) HFD (C) Orlistat + HFD (D) HFD + RN
(cv-central vein; in-inflammatory cell infiltration; id- lipid droplets; fg- fatty granule)

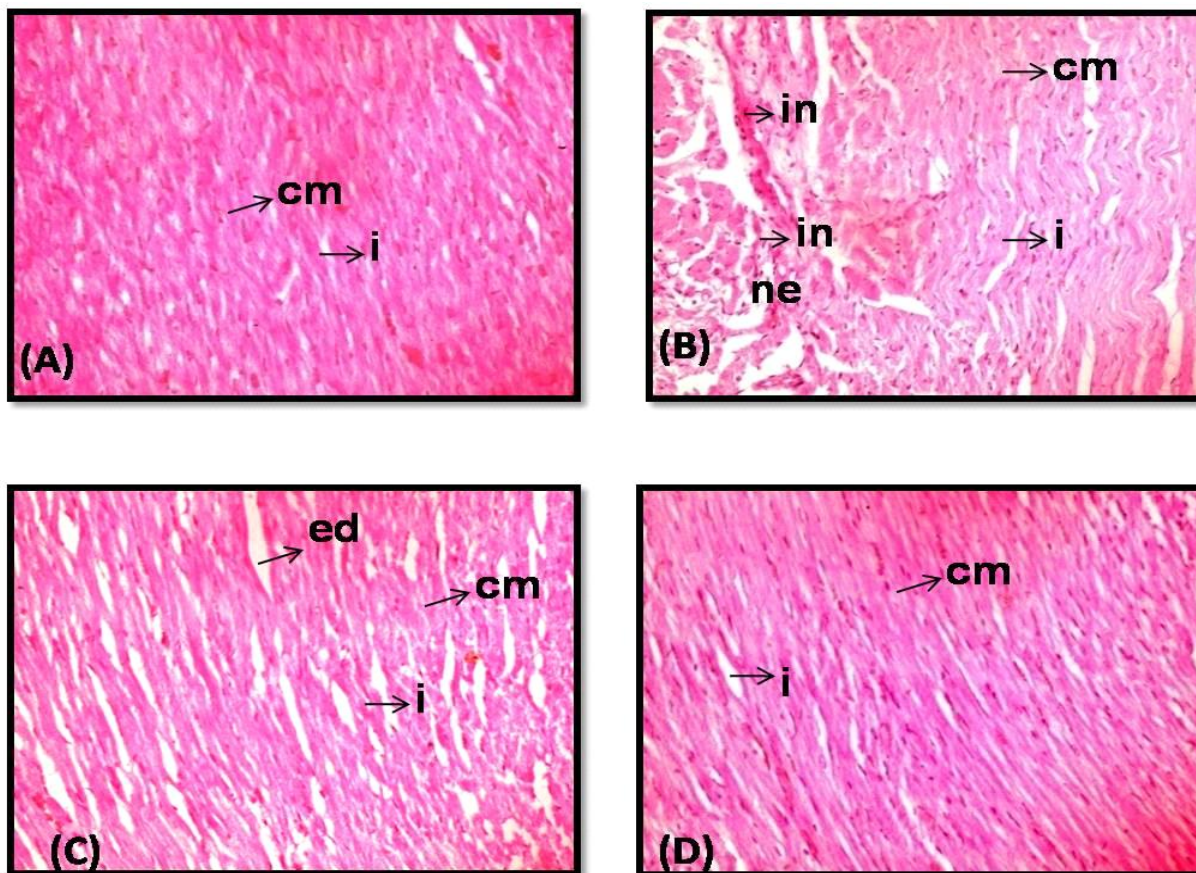


Fig-2: Effect of *R. nasutus* on the histological morphology of heart using hemotoxylin and eosin staining.

(A)Control group (B) HFD (C) Orlistat + HFD (D) HFD + RN

(cm-cardiomyocytes; in-inflammatory cell infiltration; ne- necrosis; i- interstitial spaces)

DISCUSSION:

Histological analysis of high-fat diet fed rats reveals development of pathologic abnormalities in liver and heart tissue. The liver as the first organ shall metabolize the ingested cholesterol and induce oxidative stress to make an imbalance between the production of free radicals and effectiveness of antioxidant defense systems [10]. A decrease in calorie intake, especially from fat consumption, is one of the essential steps in the treatment of obesity. A lipase inhibitor which reduces fat digestion is one of widely accepted approaches in decreasing calorie intake [11]. HF diet shall contribute the migration of obesity parallel to the change of body weight, and vital organs than in normal group. The consumption of high cholesterol diet leads to hypercholesterolemia for human and animals. Ingestion of high-fat diet may lead to fatty acid accumulation, inflammation and hepatic cell damage [12]. High fat diet affects the cell death and steatosis [13]. Prolonged steatosis can often lead to activation of inflammatory cells in the liver. NAFLD, which is recognized as the hepatic

manifestation of metabolic syndrome, is thought to occur in a two-hit manner with lipid accumulation followed by chronic inflammation, or obesity. Kupffer cells are resident liver macrophages and for primary source of liver inflammatory cytokines. Several groups have recently demonstrated that Kupffer cell activation is necessary to produce hepatic insulin resistance. Large Kupffer cells are thought to localize in the periportal zone and exhibit higher phagocytosis, protease activity, and inflammatory potential than smaller Kupffer cells in midzonal and pericentral regions. Our results (Fig-1 and 2(A-D)) indicate that normal diet rats have healthy livers and hearts with no steatosis or inflammation and histologically good in architecture. Hepato steatosis, formation of fat droplets and necrosis was developed in HFD diet livers. The treatment with RN+HFD and HFD+OL suppressed hepatocytes fat accumulation and necrosis. Our results suggest that the imbalance between oxidative stress generation and antioxidants formation could occur after high fat diet fed, and RN fraction could

prevent this pathological process, indicating its therapeutic and preventive effect on liver and heart induced by high fat ingestion. The *R.nasutus* on rat liver and heart concludes that *R.nasutus* can protect liver and heart from a foreign agent induced damage.

CONCLUSION:

Histological analysis of liver and heart tissues of rat treated with orlistat+HFD showed severe condition of central vein, hyperplastic nuclei, more granularity of the cytoplasm, cloudy swelling changes. HFD+RN of rat liver and heart tissue showed infiltration, recovered sinusoids space and increased size of hepatocytes OL+HFD treatment rats suppressed formation of lipid droplets and necrosis, when compared with high-fat diet fed rats. In heart the HFD group is caused the damage to the tissue due to excess feed causes the necrosis and inflammatory cell. The OL+HFD group causes the damage to cardiac myocytes and interstitium. The HFD+RN group shows and recovered the damage of infiltration, sinusoids.

ACKNOWLEDGMENTS

We are grateful and thankful to University Grants Commission, New Delhi for providing financial support to Dr. B.Suman and M.Venkataswamy as UGC-PDFs.

REFERENCES:

- 1.Suman Bukke, Raghu PS, Sailaja G and Thyaga Raju Kedam.,The study on Morphological, Phytochemical and Pharmacological aspects of *Rhinacanthus nasutus*. (L) Kurz (A Review) Journal of Applied Pharmaceutical Sciences, 2011; 01 (08): 26-32.
- 2.Farnsworth NR., Bunyapraphatsara N. (1992).Thai Medicinal Plant: Recommended for Primary Health Care System. Prachachon Company, Bangkok. Thailand: Prachachon Co., Ltd.
- 3.Siripong P., Yahuafai J., Shimizu K., Ichikawa K., Yonezawa S., Asai T., *et al.*, Antitumor activity of liposomal naphthoquinone esters isolated from Thai

medicinal plant: *Rhinacanthus nasutus* Kurz. *Biol Pharm Bull.*,2006; 29(11): 2279-83

- 4.Suja SR., Lath PG., Pushpangadan P., Rajasekharan S, (Evaluation of hepatoprotective effects of *Rhinacanthus nasutus* root extracts, Ethnomedicine and Ethnopharmacology Division, Trop. Bot. *Garden and Res. Doc.* 2003;4: 151-157.
- 5.Ruxana Begum SK, Thyagraju Kedam . Effect of acrylamide on chick embryo liver GSTs. *Med J Nutr and Met*,2010; 3(1): 31-38.
6. Venkataswamy M, Divya K, Pallavi C, Thyaga Raju K,. Characterization of glutathione-s-transferases-suppression Of antioxidant enzymes by acrylamide in developing chick Embryonic brain. *Int J Pharm Bio Sci*,2013; 4(3): (B) 668 – 677.
- 7.Pushpa Latha B, Vijaya T, Rama Manohar Reddy I, Ismail M and Dattatreya Rao S, Therapeutic efficacy of *Achyranthes aspera* saponin extract in high fat diet induced hyperlipidaemia in male wistar rats. *African Journal of Biotechnology*,2011; 10(74): 17038-17042.
- 8.Harris HR. On the rapid conversion of haematoxylin into haematein in staining reactions. *J. Appl. Microsc.* 1900;3, 777-780.
- 9.Humason GL.(1972) Animal tissue techniques-3rd Ed (Co. San Fransisco: W.H. Freeman.
- 10.Lum H. and Roebuck KA. Oxidant stress and endothelial cell dysfunction. *Am. J. Physiol. Cell Physiol.*2001; 280: 719-741.
- 11.Mozes S and Sefcikova Z *et al.* Obesity and changes of alkaline phosphate activity in the small intestine of 40 and 80 old day rats subjected to early postnatal over feeding or monosodium glutamate. *Physiol Res*,2004; 53:177-186.
- 12.Araya J., Rodrigo R., Videla LA., Thielemann L and Orellana M. *et al.*, Increase in long-chain polyunsaturated fatty acid n-6/n-3 ratio in relation to hepatic steatosis in patients with nonalcoholic fatty liver disease. *Clin. Sci*2004; 106:6:635-43.
- 13.Mei S., HM Ni, Manley S, Bockus A and Kassel KM *et al.* Differential roles of unsaturated and saturated fatty acids on autophagy and apoptosis in hepatocytes. *J. Pharmacol. Exp. Ther.* 2011;339: 487-498.

Abbreviation : C=Control; HFD=High fat diet; HFD+RN=High fat diet+ *Rhinacanthus nasutus*; HFD+OL= High fat diet+ Orlistat