



CODEN [USA]: IAJPBB

ISSN: 2349-7750

**INDO AMERICAN JOURNAL OF  
PHARMACEUTICAL SCIENCES**<http://doi.org/10.5281/zenodo.1404203>Available online at: <http://www.iajps.com>**Research Article****ANALYSIS OF DENTAL PULP CHANGES OBSERVED AFTER  
THE LONG TERM USE OF CORTICOSTEROID DRUGS IN  
LOCAL PATIENTS OF PAKISTAN****Dr. Amna Yaqoob<sup>1</sup>, Dr. Saad Saleem<sup>2</sup>, Hafiza Sobia Ramzan<sup>3</sup>**<sup>1</sup>Siddiqui Sadiq Memorial Trust Hospital<sup>2</sup>Services Institute of Medical Sciences<sup>3</sup>Research Assistant

Source(s) of support in the form of grants, equipment, drugs, or all of the above: None.

**Abstract:**

**Introduction:** Corticosteroids are the class of drugs which contain steroid hormones which is naturally produced in the adrenal cortex of animals and analogues of these hormones are also prepared in the laboratory. They involved in a different processes like physiologic processes, stress and immune response, metabolism of carbohydrates and proteins and regulation of inflammation reaction. **Objectives of the study:** The main purpose of this present study is to analysis of dental pulp changes observed after the long term use of corticosteroid drugs in local patients of Pakistan. **Methodology of the study:** The study groups were divided into two groups for the collection of data. One group was considered to be as the normal group and control group and the second one was the group of patients who received corticosteroid drugs during the treatment of dental pulp. The data was collected from both the groups for further analysis. Histopathologies of these two groups were also done for further clarification. Results and analysis: Results shows the percentage of vascular pulp area in relation to the total pulp area recorded in the groups. Group I presented significantly higher values ( $p=0.01$ ) than Group II and Group III, which means a significantly larger vascular area. **Conclusion:** Under the tested experimental conditions, corticosteroids applied on the dentin proved to reduce the vascular phase of pulp inflammation regarding vessel diameter and number of blood vessels.

**Corresponding author:**

**Dr. Amna Yaqoob,**  
Siddiqui Sadiq Memorial Trust Hospital,  
Pakistan.

QR code



Please cite this article in press Amna Yaqoob et al., *Analysis of Dental Pulp Changes Observed After the Long Term Use of Corticosteroid Drugs in Local Patients of Pakistan.*, Indo Am. J. P. Sci, 2018; 05(08).

**INTRODUCTION:**

It has been found that prolonged treatment with hormone leads to disorders affecting the electrolyte balance in the body, the dental literature contains a number of reports in which effects of cortisone on dental pulp have been studied. Corticosteroids are the class of drugs which contain steroid hormones which is naturally produced in the adrenal cortex of animals and analogues of these hormones are also prepared in the laboratory. They involved in a different processes like physiologic processes, stress and immune response, metabolism of carbohydrates and proteins and regulation of inflammation reaction. Corticosteroids are the drugs which are used for the treatment of stressful situation like surgery and dentistry [1].

In the pulp tissue, the first stage of potentially reversible inflammation is known as pulpal hyperemia, clinically characterized by provoked, temporary, localized, low-intensity pain. Given that this tissue is closely related to the dentin, forming the dentin-pulp complex, the pulp can be affected by aggressions to the dentin [2]. Moreover, due to the intimate relation between these tissues and the dentinal permeability, molecules of medications, such as corticosteroids, applied on the exposed dentin, diffuse through the dentinal tubules, with the potential to provide a therapeutic effect, alleviating the painful symptom [3].

The therapeutic effect of corticosteroids is based on their action on the synthesis of lipocortin and vasocortin, inhibiting the formation of edema and A<sub>2</sub> phospholipasis enzymes, respectively. By inhibiting this enzyme, membrane phospholipids cannot be converted into aradonic acid. Therefore, the synthesis of prostaglandins and prostacyclins (the cyclooxygenase route) as well as the synthesis of leukotrienes (the lipoxygenase route) that should follow are blocked<sup>4</sup>. Moreover, corticosteroids will act on histamine, heparin, and bradecinin, which are important chemical mediators in the initial phases of acute inflammation. The activation of the cinin system results in the release of bradecinin norpeptide. This vasoactive agent can induce arteriolar dilatation, increase venule permeability and cause pain [5].

All the dendritic cells present in the dental pulp are covered by Schwann cells. The nerve fibrils have a rounded myelin sheath [4,5]. The plasma membrane of the cell also constitutes typical mesaxons. Basement of these cells consist of amyelinated nerve sheath, which is the part of pulp chamber. Myelinated fibrils can also loose the myelin sheath of cells [6].

According to Srisawasdi and Pavasant (2007) [7], corticosteroids promote fibronectin synthesis and suppress nerve growth factor secretion, suggesting that this reagent could be used clinically to reduce pain and promote dental pulp tissue healing. In the present study the inflammatory components of the inflammation were not investigated because that 10-min period between application of betamethasone and euthanasia of the animals is not long enough to allow for cell margination and exudation of the inflammatory cell components from the blood vessels. However, the medication acts on the vascular phase of the inflammation and can cause the inflammatory symptoms to subside for all of the following phases. The efficacy of betamethasone can be verified by its penetration into the dentinal tubules, having a favorable action on vascular response.

**Objectives of the study**

The main purpose of this present study is to analysis of dental pulp changes observed after the long term use of corticosteroid drugs in local patients of Pakistan.

**MATERIAL AND METHODS:**

The study was conducted according to the ethics and rules and regulations of Siddiqui Sadiq Memorial Trust Hospital and SIMS, Lahore. For this study we collect the data from 100 patients during September 2017 to February 2018. The data was collected from the patients having treatment of dental pulp in the age of 20 to 50 years. Patients above 50 years of age keeping in mind the inclusion and exclusion criteria the subject selected for the study were on long-term steroid therapy.

**Data Collection**

The study groups were divided into two groups for the collection of data. One group was considered to be as the normal group and control group and the second one was the group of patients who received corticosteroid drugs during the treatment of dental pulp. The data was collected from both the groups for further analysis. Histopathologies of these two groups were also done for further clarification.

**Statistical analysis**

Student's t-test was performed to evaluate the differences in roughness between groups. Two-way ANOVA was performed to study the contributions. A chi-square test was used to examine the difference in the distribution of the fracture modes (SPSS 19.0 for Windows, SPSS Inc., USA).

**RESULTS:**

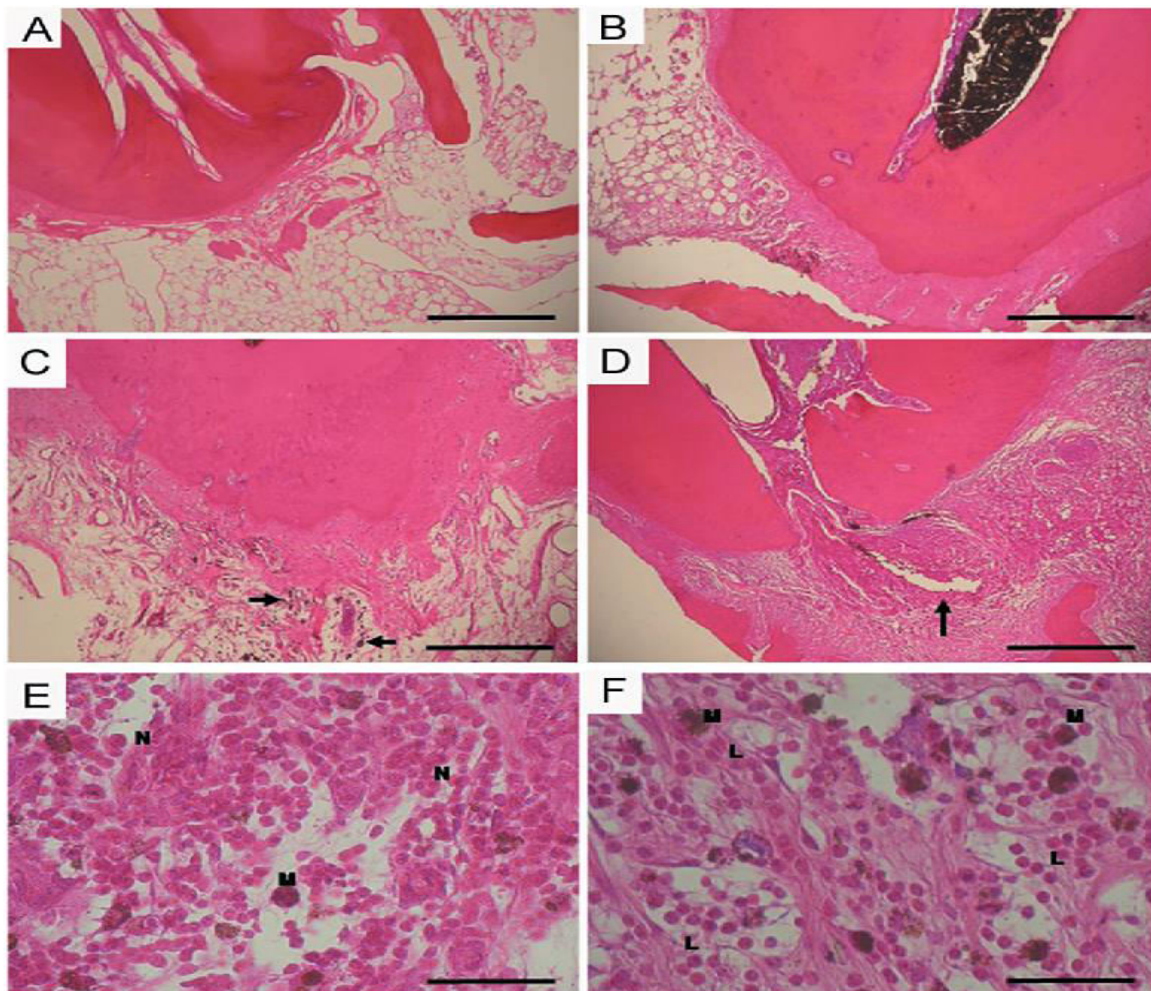
Table 1 presents the percentage of vascular pulp area in relation to the total pulp area recorded in the groups. Group I (no dexamethasone) presented

significantly higher values ( $p=0.01$ ) than Group II (control) and Group III (dexamethasone after cavity preparation), which means a significantly larger vascular area.

**Table 1:** Total pulp area recorded in different groups

Group	n	Standard deviation	p
No medication	30	17.21	$\leq 0.01$
Control group	30	8.11	
Group containing corticosteroid drugs (dexamethasone)	30	3.01	

Images from microscopic slides of specimens from Group II were closer in quality to those from Group III and presented a higher percentage of the area occupied by loose connective tissue. [Figure 1](#) shows histological images of the pulp tissue in Groups I, II and III. The only region that was positively immunostained was the dental pulp (Figure 1). The positively stained part was almost at the center of the dental pulp. In this region, darkly stained bead-like nerve fibers were observed. No nerve fiber terminals were visible.



**Figure 1:** Histological images of the pulp tissue. A slide shows the normal group and control group. B, C, D, E and F shows the histological section of the group which was treated with different corticosteroid drugs (dexamethasone).

methasone).

#### DISCUSSION:

Corticosteroids are widely used in the treatment of diseases, disorders and conditions affecting the oral and maxillofacial area and the adjacent and associated structures. The diseases of the oral and maxillofacial area might be either neighborhood or the appearance of a fundamental issue. Corticosteroids have their most extensive application in the administration of intense and unending conditions which have an unfavorably susceptible, immunologic, or fiery premise [8]. In this way, a gathering of corticosteroids which have predominantly a glucocorticoid movement and practically no mineralocorticoid activity, for example, betamethasone, dexamethasone, triamcinolone, and prednisolone are utilized [9].

In spite of the fact that corticosteroids have incredible potential in the treatment of different diseases and conditions influencing oral and maxillofacial area, they likewise convey the danger of numerous side effects. Subsequently, benefits from corticosteroids ought to dependably be weighed against their potential risks. Side effects of corticosteroids differ contingent upon the sort and measurement of the drug, defeat of organization, and length of treatment. Noteworthy unfriendly effects are well on the way to happen in patients utilizing oral corticosteroids for a drawn out stretch of time [10,21,23]. These may incorporate weight increase, impeded development, adrenal deficiency, electrolyte variations from the norm, and expanded vulnerability to disease, myopathy, osteoporosis, osteonecrosis, waterfall, glaucoma, mental issues, cracks, hypertension, a sleeping disorder, moon face, diabetes, and peptic ulcer. Information of the standards of the calming activity of corticosteroids has demonstrated that these specialists are equipped for controlling the advancement of fiery procedures from the irrigative stage by repressing the creation of arachidonic corrosive and subsequently the generation of prostaglandins, which have a critical part in initiating vasodilatation and expanding vascular porousness. Along these lines, the vascular provocative occasions have a tendency to decrease [11-13,25].

Estimating the size of dilatation (vascular territory) and tallying the quantity of veins have been utilized as a part of a past study that looked at the vascular status of deciduous and lasting teeth by methods for PC supported examination. Those creators watched an expansion in vascularization that was identified with caries movement and was not trailed by an increment in the quantity of veins. In the present

examination, these estimations were additionally gotten carefully, which awards precision to the information [14].

It is realized that the temperature of the mash expands a touch of amid depression readiness. Mash response can be reduced if legitimate agent procedure and cooling conditions. Be that as it may, because of the specific attributes of the mash dentin complex, there will be a fiery reaction to the animosity, which is converted into an expansion in action of the sensory tissue, veins and the insusceptible system [15]. The way that microbial specialists and some remedial materials can cause fiery responses may add to irritate the scenario. Along these lines, as some sort of mash reaction is normal, endeavors ought to be coordinated at keeping the incendiary conditions from exacerbating by exploiting the dentinal porousness and the private connection amongst mash and dentin. In a comparable way, Ciarlone and Pashley (1992) in an audit of the writing, proposed that it is conceivable to utilize the dentinal porousness with helpful purposes. They also suggested using anesthetics to avoid pain from disseminating, using painkillers to control pain, and using antibiotics to treat infection [16-20].

#### CONCLUSION:

Under the tested experimental conditions, corticosteroids applied on the dentin proved to reduce the vascular phase of pulp inflammation regarding vessel diameter and number of blood vessels.

#### REFERENCES:

1. Gibson N, Ferguson JW. (2004). Steroid cover for dental patients on long-term steroid medication: proposed clinical guidelines based upon a critical review of the literature *British Dental Journal*. 197 (11): 681–685.
2. Grover VK, Babu R, Bedi SPS. (2007). Steroid Therapy – Current Indications in Practice. *Indian Journal of Anaesthesia*. 51 (5): 389-393.
3. Alexander RE, Thronson RR (2000). A review Of Perioperative Corticosteroid use In Dentoalveolar Surgery, *Oral Surg Oral Med Oral Path*. 90:406-15.
4. CAHEN, P.M., and FRANK, R.M.: Microscopie electronique de la pulpe dentaire humaine normale, *Bull Group Int Rech Sci Stomatol* 13: 421-443, 1970.
5. Accorinte ML, Loguercio AD, Reis A, Costa CA. Response of human pulps capped with different self-etch adhesive systems. *Clin Oral Investig*. 2008;12(2):119–127.

6. Büyükgürül B, Cehreli ZC. Effect of different adhesive protocols vs calcium hydroxide on primary tooth pulp with different remaining dentin thicknesses: 24-month results. *Clin Oral Investig*. 2008;12(1):91–96.
7. Ciarlone AE, Pashley DH. Medication of dental pulp: a review and proposals. *Endod Dent Traumatol*. 1992;8(1):1–5.
8. Cotran RS, Kumar V, Collins T. Robbins' pathologic bases of disease. Philadelphia: WB Saunders; 2004.
9. Fachin EVF, Zaki AE. Histology and lysosomal cytochemistry of the postsurgically inflamed dental pulp after topical application of steroids. I. Histological study. *J Endod*. 1991;17(9):457–460.
10. Fry AE, Watkins RF, Phatak NM. Topical use of corticosteroids for the relief of pain sensitivity of dentine and pulp. *Oral Surg Oral Med Oral Pathol*. 1960;13(5):594–597.
11. Hume WL, Massey WL. Keeping the pulp alive: the pharmacology and toxicology of agents applied to dentine. *Aust Dent*. 1990;35(1):32–37.
12. Love RM, Jenkinson HF. Invasion of dentinal tubules by oral bacteria. *Crit Rev Oral Biol Med*. 2002;13(2):171–183.
13. Manchikanti L. Role of neuraxial steroids in interventional pain management. *Pain Physician*. 2002;5(2):182–199.
14. Mjor IA, Ferrari M. Pulp-dentin biology in restorative dentistry. Part 6: Reactions to restorative materials, tooth-restoration interfaces and adhesive techniques. *Quintessence Int*. 2002;33(1):35–63.
15. Mjor JH, Levik T. Pulp healing subjacent to corticosteroid-covered and amalgam-covered dentin. *Oral Surg Oral Med Oral Pathol*. 1975;40(6):789–795.
16. Mosteller JH. Use of prednisolone in the elimination of postoperative thermal sensitivity: a clinical study. *J Prosthet Dent*. 1962;12(6):1176–1179.
17. Negm MM. Intracanal use of a corticosteroid-antibiotic compound for the management of posttreatment endodontic pain. *Oral Surg Oral Med Oral Pathol Oral Radiol Endod*. 2001;92(4):35–39.
18. Nakanishi T, Shimizu H, Matsuo T. An immunological study on cyclooxygenase-3 in human dental pulp. *J Endod*. 2001;27(6):385–388.
19. Pashley DH. Dynamics of the pulpo-dentin complex. *Crit Rev Oral Biol Med*. 1996;7(2):104–133.
20. Rittner HL, Back A, Stein C. Pro-algesic versus analgesic actions of immune cells. *Curr Opin Anaesthesiol*. 2003;16(5):527–533.