



CODEN [USA]: IAJPB

ISSN: 2349-7750

**INDO AMERICAN JOURNAL OF
PHARMACEUTICAL SCIENCES**<http://doi.org/10.5281/zenodo.1407494>Available online at: <http://www.iajps.com>

Research Article

**PCI VERSUS CABG: INTERVENTIONAL CARDIOLOGISTS
CHOICE TO TREAT LMCA DISEASE IN A BETTER, SAFER
AND ACCEPTABLE WAY**¹Dr. Muhammad Numan Butt, ¹Dr. Fareha Shahzad, ²Amna Naeem¹Lahore General Hospital Lahore²Independent Medical College Faisalabad**Abstract:**

Objective: Interventional cardiologists have always faced the issue of LMCA critical stenosis. Conventionally, CABG is carried out in the management of patients; but, more frequent use of PCI (Percutaneous Coronary Intervention) have been observed but scarce literature is available about the utilization of PCI. We aimed to determine the rate of technical success and safety of the stenting of percutaneous LMCA.

Methods: We studied 53 patients in our research at Services Hospital, Lahore in the timeframe of February 2016 to March 2017. We included all the patients who experienced coronary angiogram and diagnosed with an isolated LMCA or coexisting ostial LAD artery disease. All the cases having any previous surgical management of CAD and dialysis cases (renal disorders) were not made a part of this research. Patients were briefed about the CABG and PCI regarding their benefits and shortcomings. We considered all those cases who opted PCI and managed all these patients for stenting of percutaneous LMCA with or without the help of stenting of ostial LAD stenting.

Results: A total of 72 patients were diagnosed with the disease of LMCA in the course of angiogram; whereas, only 15 patients chose CABG, inclusion criteria were not fulfilled by four patients, therefore, our final research sample was restricted to 53 patients. Patients were observed with a mean age of (55.45 ± 10.275) years. Acute coronary syndrome and stable angina were reported in respectively 29 and 22 patients. All patients had technically successful PCI with stenting. Only one mortality was reported after three months of PCI and no other death case was reported.

Conclusion: PCI has better, safer and acceptable outcomes with a better technical success to LMCA critical stenosis.

Keywords: CABG (Coronary Artery Bypass Graft), LMCA (Left Main Coronary Artery). CAD (Coronary Artery Disease), PCI (Percutaneous Coronary Intervention) and LAD (Left Anterior Descending).

*** Corresponding author:**

Dr. Muhammad Numan Butt,
Lahore General Hospital,
Lahore

QR code



Please cite this article in press Muhammad Numan Butt et al., *PCI versus CABG: Interventional Cardiologists Choice to Treat Lmca Disease in a Better, Safer and Acceptable Way.*, Indo Am. J. P. Sci, 2018; 05(08).

INTRODUCTION:

All the cases who experienced coronary angiography were reported 3% – 5% of LMCA disease and in the patients, who experienced bypass surgery the incidence was reported about 10% – 30% [1 – 4]. The high cardiovascular risk is posed because of critical LMCA stenosis which can jeopardize the myocardium and related disease of the multivessel coronary artery; therefore, it is a vital prognosis lesion. In the available guidelines, CABG is standard procedure for non-protected LMCA patients due to its long-term beneficial surgical revascularization outcomes better than the medical interventions [5 – 10].

However, due to related features and anatomic accessibility, PCI is a choice for the interventional cardiologist to treat LMCA. The literature review also favours the short and mid-term effectiveness along with feasibility. Limited use of PCI is carried out in the LMCA for high-risk surgical patients, protected LMCA patients or used as bailout process for the patients having the complication of angioplasty. Recent improvements in the strategies and adjunctive pharmacology have replied surgical stenosis wisdom about LMCA [11 – 13].

Coronary stenting has introduced the reassessment PCI role in the LMCA pragmatic treatment because of the availability of DES (Drug Eluting Stents) to treat LMCA, it has also reduced PCI utilization instead of CABG [14 – 18]. LMCA and PCI clinical experience involves a wide range of angiographic and clinical patient's sub-categories. However, long-term efficacy and safety evaluation of PCI with LMCA disease stenting have not been studied in any of the randomized trials in order to compare CABG with PCI in a large sample [19]. In this research, a review has been made about the status of surgical treatment against the percutaneous treatment of LMCA keeping in view the focus that whether CABG is better or PCI as an alternative [20]. We aimed to determine the rate of technical success and safety of the stenting of percutaneous LMCA.

METHODS:

We studied 53 patients in our research at Services Hospital, Lahore in the timeframe of February 2016 to March 2017. We included all the patients who experienced coronary angiogram and diagnosed with an isolated LMCA or coexisting ostial LAD artery disease. All the cases having any previous surgical management of CAD and dialysis cases (renal disorders) were not made a part of this research. Patients were briefed about the CABG and PCI regarding their benefits and shortcomings. We considered all those cases who opted PCI and managed all these patients for stenting of percutaneous LMCA with or without the help of stenting of ostial LAD stenting. Single operator carried out all the procedures who had a vast experience. Patients were managed with DES and PCI. Patients were detained in CCU (Coronary Care Unit) before procedures and ECG monitoring was also carried out along with hemodynamics. Clopidogrel and Aspirin were given as dual antiplatelet treatment to all the patients. Tirofiban (an antiplatelet agent) was given to acute coronary syndrome patients. Patients were discharged after moving to the cardiology ward in case of stable condition for a period of twenty-four hours. Follow up of the patients was carried out for one year on monthly basis in cardiology OPD.

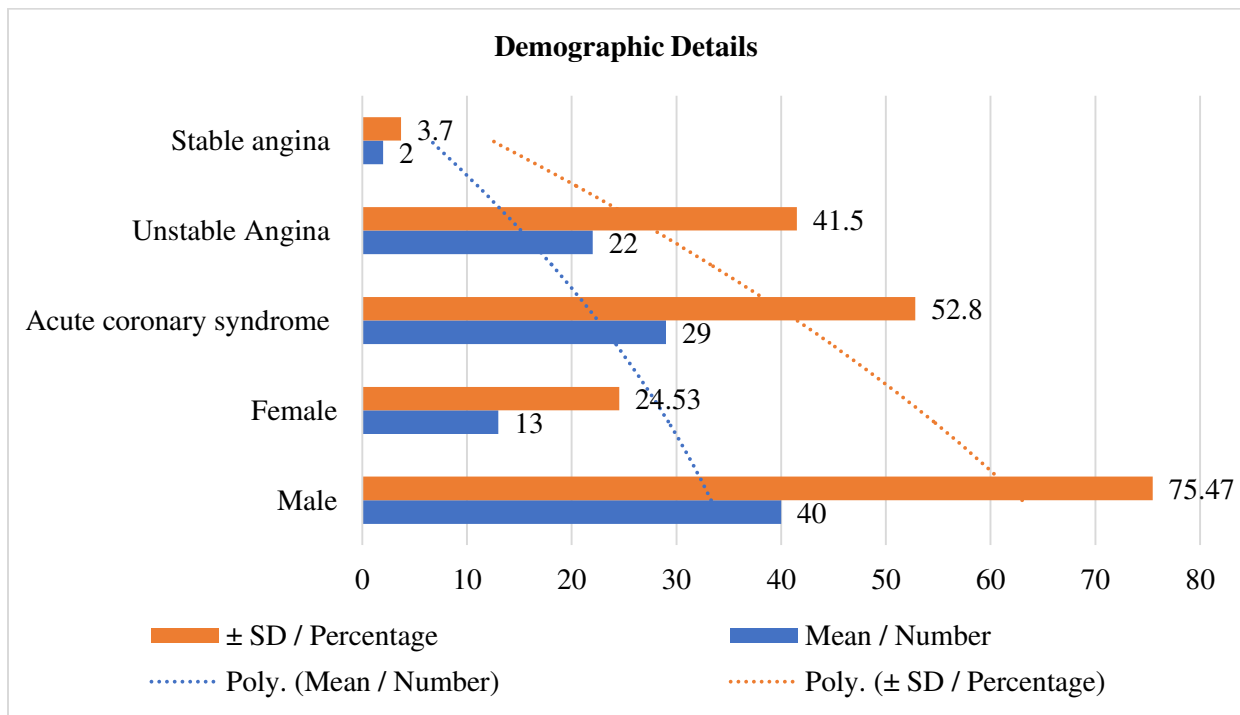
Data analysis was carried out on SPSS. Quantitative variables were presented in Mean and SDD; whereas, frequency and percentage for qualitative variables.

RESULTS:

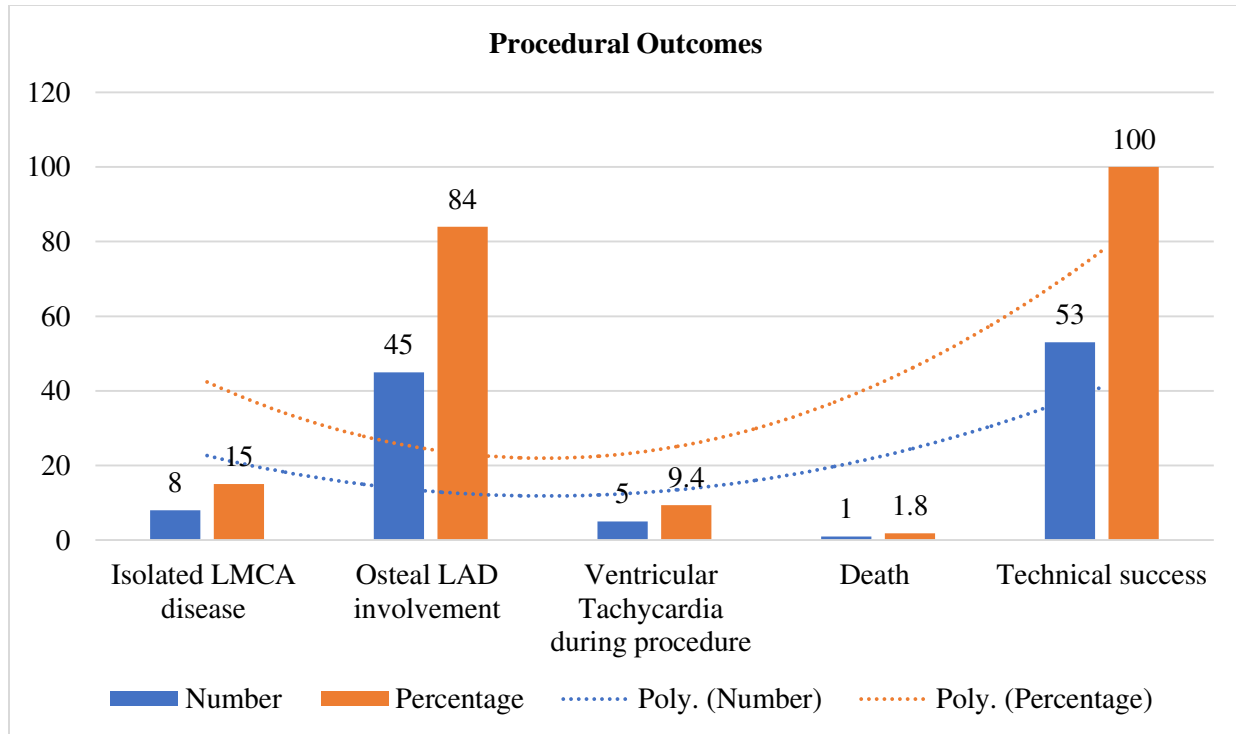
A total of 72 patients were diagnosed with the disease of LMCA in the course of angiogram; whereas, only 15 patients chose CABG, inclusion criteria were not fulfilled by four patients, therefore, our final research sample was restricted to 53 patients. Patients were observed with a mean age of (55.45 ± 10.275) years. Acute coronary syndrome and stable angina were reported in respectively 29 and 22 patients. All patients had technically successful PCI with stenting. Only one mortality was reported after three months of PCI and no other death case was reported. Demographic data of the patients and procedural outcomes have been given in detail in Table – I and II respectively with graphical presentation.

Table – I: Demographics of the study subjects

Demographic Detail	Mean / Number	± SD / Percentage
Age (Years)	55.45	10.275
Male	40	75.47
Female	13	24.53
Acute coronary syndrome	29	52.8
Unstable Angina	22	41.5
Stable angina	2	3.7

**Table – II:** Procedural Outcomes

Variables	Number	Percentage
Isolated LMCA disease	8	15
Ostial LAD involvement	45	84
Ventricular Tachycardia during procedure	5	9.4
Death	1	1.8
Technical success	53	100



DISCUSSION:

Heart blood flow is seventy-five percent in the LMCA disease which is a highly risky lesion. Coronary angiography patients have a reported prevalence of LMCA in the range of 2.5% – 10%, its coexistence is observed with the narrowing of the coronary tree. LMCA disease has a higher rate of mortality in the course of treatment [7, 21]. Poor long-term prognosis has been reported in the previous research studies about the medical management of LMCA disease having a fifty percent survival rate for three years [11].

In a traditional way LMCA is commonly treated with CABG; whereas, PCI is used in the surgically poor cases. As the advancements are in action and strategies have been improved with the advent of DES which has given an emergence to the PCI to treat LMS stenosis. Mean age of the patients diagnosed with LMCA and treated with PCI intervention was (55.45 ± 10.275) years. An advanced age was reported in various other research studies [23]. It highlights disease progression and higher disease burden in the subcontinent which is also higher in the global perspective [22].

We found the baseline outcomes of the unstable angina patients in 22 patients (43.1%), same has been reported in a research conducted by Lee as he reported 46% unstable angina cases [23]. Mortality rate as observed in the third month is also comparable

with other studies [24]. Another author reported eleven deaths in his research as one during hospitalization and remaining deaths after a period of thirty days after being discharged from the hospital [4]. No adverse effects were reported in our setting during a follow-up routine in this research after PCI, same has been observed in other research studies as adverse effects were much lower than expected [24]. Long-term follow-up was missing as it counts a limitation of our research.

CONCLUSION:

PCI has better, safer and acceptable outcomes with a better technical success to LMCA critical stenosis. Studies are to be conducted on large scale and include multiple centres to assess the treatment of LMCA disease.

REFERENCES:

1. Cheng CI, Wu CJ, Fang CY, Youssef AA, Chen CJ, Chen SM et al. Feasibility and safety of trans radial stenting for unprotected left main coronary artery stenosis. *Circ J.*2007;71(6):855-861.
2. Jiang WB, Zhao W, Huang H, Li CL, Zhang JH, Wang Y, et al. Meta-analysis of effectiveness of first-generation drug-eluting stents versus coronary artery bypass grafting for unprotected left main coronary disease. *Am J Cardiol.*2012;110(12):1764-1772.
3. Patel JV, Dwivedi S, Hughes EA, Lip GY. Premature coronary artery disease: an inferred

- cardiovascular variant or a South Asian genetic disorder? *Thromb Haemost.*2008;99(6):991-992.
4. Lee MS, Kapoor N, Jamal F, Czer L, Aragon J, Forrester J, et al. Comparison of Coronary Artery Bypass Surgery with Percutaneous Coronary Intervention with Drug-Eluting Stents for Unprotected Left Main Coronary Artery Disease. *J Am Coll Cardiol.* 2006;47(4):864-870.
 5. Capodanno D, Stone GW, Morice MC, Bass TA, Tamburino C. Percutaneous Coronary Intervention Versus Coronary Artery Bypass Graft Surgery in Left Main Coronary Artery Disease. *J Am Coll Cardiol.* 2011;58(14):1426-1432.
 6. Ferrante G, Presbitero P, Valgimigli M, Morice MC, Pagnotta P, Belli G. Percutaneous coronary intervention versus bypass surgery for left main coronary artery disease: a meta-analysis of randomized trials. *Euro Intervention.*2011;7(6):738-746.
 7. Garner WL, Stoler RC, Laible EA, Kang MJ, Choi JW. Percutaneous coronary artery stenting of unprotected left main coronary artery disease using drug-eluting stents: the initial Baylor University Medical Center experience. *Proc (Bayl Univ Med Cent).* 2007;20(4):339-343.
 8. Chieffo A, Stankovic G, Bonizzoni E, Tsalgou E, Iakovou I, Montorfano M, et al. Early and mid-term results of drug-eluting stent implantation in unprotected left main. *Circulation.* 2005;111(6):791-795.
 9. Price MJ, Cristea E, Sawhney N, Kao JA, Moses JW, Leon MB, et al. Serial angiographic follow-up of sirolimus eluting stents for unprotected left main coronary artery re-vascularization. *J Am Coll Cardiol.* 2006;47(4):871-877.
 10. Hokken RB, Foley D, van Domburg R, Serruys PW. Left main coronary artery dissection during percutaneous coronary intervention treated by stenting. *Neth Heart J.*2002;10(10):395-398.
 11. Ragosta M, Dee S, Sarembock IJ, Lipson LC, Gimple LW, Powers ER. Prevalence of unfavorable angiographic characteristics for percutaneous intervention in patients with unprotected left main coronary artery disease. *Catheter Cardiovasc Interv.* 2006; 68:357.
 12. Serruys PW, Morice MC, Kappetein AP, Colombo A, Holmes DR, Mack MJ, et al. Percutaneous coronary intervention versus coronary-artery bypass grafting for severe coronary artery disease. *N Engl J Med.* 2009; 360:961.
 13. Fajadet J, Chieffo A. Current management of left main coronary artery disease. *Eur Heart J.* 2012;33(1):36-50.
 14. Kandzari DE, Colombo A, Park SJ. Revascularization for unprotected left main disease: Evolution of the evidence basis to redefine treatment standards. *J Am Coll Cardiol.*2009;1576-1588.
 15. Buszman PE, Kiesz SR, Bochenek A. Acute and late outcomes of unprotected left main stenting in comparison with surgical revascularization. *J Am Coll Cardiol.*2008;538-545.
 16. Pandya SB, Kim YH, Meyers SN, Davidson SJ, Flaherty JD, Park D et al. Drug-Eluting Stents versus Bare Metal Stents in Unprotected Left Main Coronary Artery Stenosis: a Meta-Analysis. *JACC Cardiovasc Interv.* 2010;3(6):602-611.
 17. Awan MA, Khan A, Siddiqi TA, Hussain A, Rabbi F, Tasneem H. Early effects of coronary artery bypass grafting on left ventricular regional wall motion abnormalities. *J Coll Physicians Surg Pak.* 2007;17(1):3-7.
 18. Biondi-Zoccai GG, Lotrionte M, Moretti C, Meliga E, Agostoni P, Valgimigli M, et al. A collaborative systematic review and meta-analysis on 1278 patients undergoing percutaneous drug-eluting stenting for unprotected left main coronary artery disease. *Am Heart J.* 2008;155(2):274-283.
 19. White AJ, Kedia G, Mirocha JM, Lee MS, Forrester JS, Morales WC, et al. Comparison of coronary artery bypass surgery and percutaneous drug-eluting stent implantation for treatment of left main coronary artery stenosis. *JACC Cardiovasc Interv.* 2008; 1:236-245.
 20. El-Menyar AA, Al Suwaidi J, Holmes JDR. Left main coronary artery stenosis: state-of-the-art. *Curr Prob Cardiol.*2007;32:103-193.
 21. Eagle KA, Guyton RA, Davidoff R, Edwards FH, Ewy GA, Gardner TJ, et al. ACC/AHA 2004 guideline update for coronary artery bypass graft surgery: a report of the American College of Cardiology/American Heart Association Task Force on Practice Guidelines (Committee to Update the 1999 Guidelines for Coronary Artery Bypass Graft Surgery). *Circulation.* 2004;110: e340-e437.
 22. Smith SC Jr, Feldman TE, Hirschfeld JW Jr, Jacobs AK, Kern MJ, King SB III, et al. ACC/AHA/SCAI 2005 guideline update for percutaneous coronary intervention: a report of the American College of Cardiology/ American Heart Association Task Force on Practice Guidelines (ACC/AHA/SCAI Writing Committee to Update 2001 Guidelines for Percutaneous Coronary Intervention). *Circulation.*2006; 113: e166-e286.
 23. Ng W, Lundstrom R, McNulty E. Impact of stenting technique and bifurcation anatomy on

long-term outcomes of PCI for distal unprotected left main coronary disease. *J Invasive Cardiol.* 2013;25(1):23-27.

24. Naik H, White AJ, Chakravarty T, Forrester J, Fontana G, Kar S, et al. A meta-analysis of 3,773 patients treated with percutaneous coronary intervention or surgery for unprotected left main coronary artery stenosis. *J ACC Cardiovasc Interv.* 2009;2(8):739-747.