



CODEN [USA]: IAJPBB

ISSN: 2349-7750

**INDO AMERICAN JOURNAL OF
PHARMACEUTICAL SCIENCES**<http://doi.org/10.5281/zenodo.1407506>Available online at: <http://www.iajps.com>**A CASE REPORT****A CASE REPORT ON SPIRONOLACTONE INDUCED BILATERAL
GYNECOMASTIA****Purushothama Reddy K^{1*}, Dr. Rajesh Asija², Dr. M. Purushothaman³, Vaseem. D⁴,
Dr. S. Arshiya Banu⁵, M. Divijasri⁶**^{*1}Associate Professor, Department of Pharmacy Practice, Rao's College of Pharmacy, Nellore, A P – 524 320.²Professor, Department of Pharmaceutics, Sunrise Pharmacy College, Sunrise University, Alwar, Rajasthan, India.³Principal & Professor, Department of Pharmaceutics, Scient Institute of Pharmacy, Ibrahimpatnam, R R District – 501 506, Hyderabad, Telangana, India.⁴Pharm. D 4th Year, Department of Pharmacy Practice, Narayana Pharmacy College, Nellore, A P – 524 320, India.⁵Assistant Professor, Department of Pharmacy Practice, P. Rami Reddy Memorial College of Pharmacy, Kadapa, A P – 516 003, India.⁶Pharm. D 4th Year, Department of Pharmacy Practice, Rao's College of Pharmacy, Nellore, A P – 524 320, India.**Abstract:**

Gynecomastia is benign enlargement of male breast, drug induced gynecomastia accounts for about 25 %. We are reporting a case of spironolactone induced bilateral gynecomastia. A 42 year old male patient receiving antihypertensive drug presented with Portal vein hypertension and umbilical cord hernia and referred for surgery. 2 years back patient was a known alcoholic and admitted with chronic alcoholic liver diseases and presence of portal vein hypertension so prescribed with spironolactone with a dose of 25 mg once in a day. Investigations revealed that presence of hyperkalemia at present so; he was advised to stop spironolactone. The patient improved symptomatically but developed painful swelling of the breast after treatment which was suspected to be spironolactone induced gynecomastia. Within a month of stopping the drug, pain in the right breast subsided followed by decrease in size of swelling. Literature search indicates bilateral gynecomastia by spironolactone, but when clinician encounters unilateral presentation, they should consider the possibility of drug induced etiology. Patients should be educated about this while prescribing and eplerenone can be a safe alternative.

Keywords: Drug induced bilateral gynecomastia, spironolactone, Hyperkalemia, eplerenone as safe alternative.**Corresponding author:****Purushothama Reddy. K,**Associate Professor, Department of Pharmacy Practice,
Rao's College of Pharmacy, Nellore, A P – 524 320.**Mobile:** 91 + 9618266403.**Email:** redlypharma6@gmail.com**QR code**

Please cite this article in press Purushothama Reddy K et al., A Case Report on Spironolactone Induced Bilateral Gynecomastia., Indo Am. J. P. Sci, 2018; 05(08).

INTRODUCTION:

Gynecomastia is clinically defined as benign enlargement of male breast due to proliferation of glandular component with deposition of fat [1]. It is derived from Greek words “gynae” meaning woman and “mastos” which means breast. This clinical condition can occur at all ages and involve one or both breasts [2]. Normally, estrogen stimulates the proliferation of breast epithelial cells, and androgens have an inhibitory effect. Gynecomastia usually results due to imbalance between actions of estrogen and androgen on the breast tissue. The causes for gynecomastia can be either physiological (neonatal, pubertal or involutional) or pathological conditions (drug induced endocrine disorders such as testicular, adrenocortical or pituitary tumors, hyperthyroidism and non-endocrine causes such as cirrhosis, starvation, stress and renal failure) [1-3].

The 1st report from France was published in 1953 and the second report on it was from Italy in 1957. In the literature, only one case report from India is available in English and elsewhere this finds mention in the long list of drugs causing gynecomastia. The rarity of such an extent prompted us to report this case. Drug induced gynecomastia accounts for about 20 % – 25 % of all new cases in adults. Gynaecomastia is one of the most common breast problems in men and was first described by Paulus Aegineta (AD 625 - 690), who thought it was due to formation of fat. It can occur due to numerous causes which include developmental gynecomastia, congenital causes like Klinefelter syndrome, hermaphroditism, enzyme defects of testosterone production, acquired causes like trauma, infection, torsion (twisted testicles), radiation, mumps, chemotherapy, malignancies like bronchogenic carcinoma, alcoholism, systemic causes like congenital Adrenal hyperplasia, cirrhosis, renal failure, thyrotoxicosis and drugs.

Drugs associated with gynecomastia are Bicalutamide, Flutamide, Nilutamide, Leuprolide, Goserelin, Metronidazole, Ketoconazole, Isoniazid, Minocycline, Digoxin, Spironolactone, Amlodipine, Nifedipine, Verapamil, Captopril, Enalapril, Amiodarone, Methyldopa, Minoxidil, Methotrexate, Vincristine, Diazepam, Phenytoin, Androgens, Anabolic Steroids, Estrogen, Theophylline, D - Penicillamine, Cimetidine and Metoclopramide. ^{1, 2} Spironolactone, which is a potassium sparing diuretic, has antiandrogen action and causes bilateral gynecomastia, we are also observed the same bilateral gynecomastia patient.

CASE REPORT:

A 42 year old male, known smoker and alcoholic, was on Tab. Spironolactone 25 mg OD, Tab. Lasix 40 mg BID, T. UCDA 300 mg BID, Tab. Propranolol 40 mg BID and Syp. Lactulose 15 ml TID for control of alcoholic liver disease induced portal vein hypertension along with peripheral oedema hypertension. After a year of taking the above medications, he presented to his physician with Umbilical hernia, muscle weakness and easy fatigability. On examination, his vital parameters including blood pressure were normal, but serum potassium was high. This was attributed to tablet Spironolactone and persistently patient was with an Umbilical hernia for surgery. He was advised to stop the above mediations at right now and prescription was revised with the other antihypertensives. In spite of this, the patient's symptoms persisted and hence tablet Propranolol 40 mg BID was added to the existing medications. After 12 months of treatment, muscle weakness and fatigability reduced but he developed painful swelling of the breast on both sides.

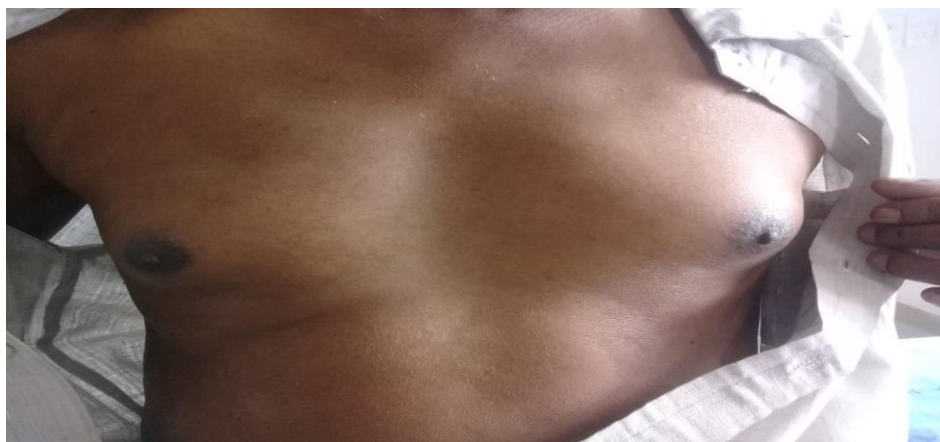


Figure 1: Frontal view of the patient showing Gynaecomastia developed during Spironolactone based

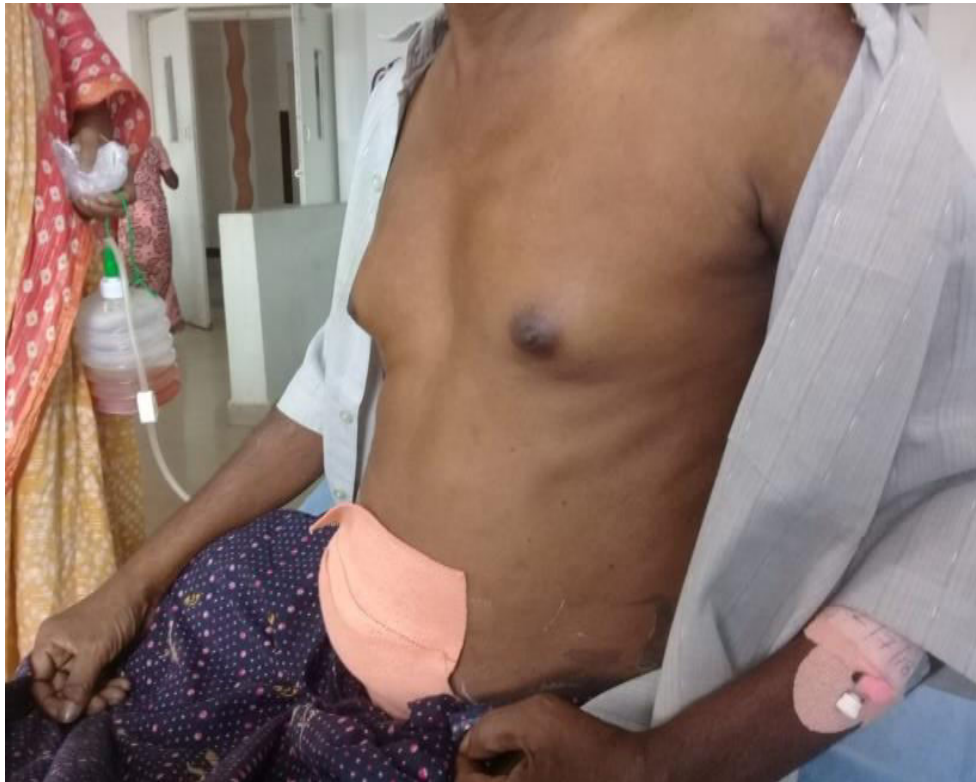antihypertensive treatment

Figure 2: Lateral view of the patient showing Gynaecomastia

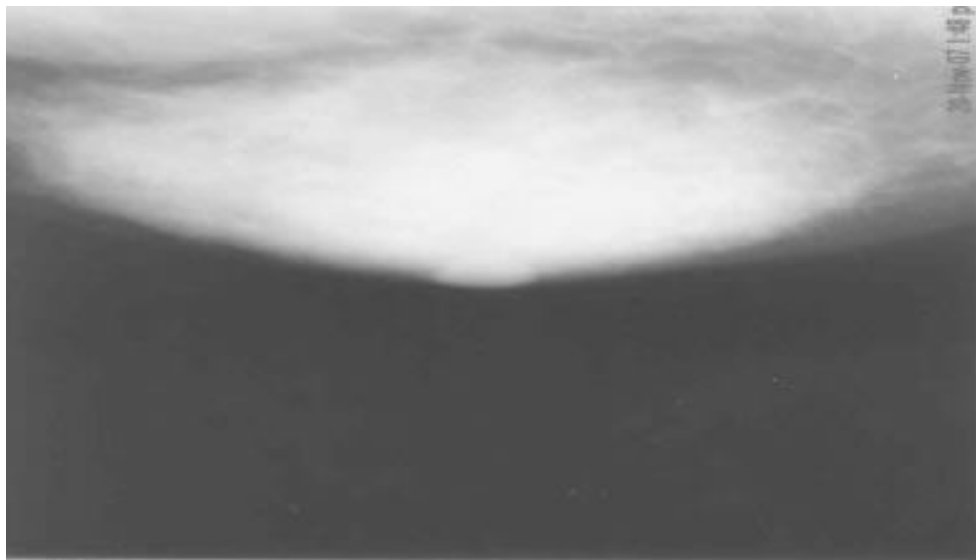


Figure 3: Mammogram of the patient showing glandular hypertrophy indicating true gynecomastia

On examination, tender mobile lump was palpable in the both the breast. Fine needle aspiration cytology of the breast done was normal. It was suspected to be spironolactone induced gynecomastia and the drug

was withdrawn (dechallenge) while other regular medications were continued. On dechallenge, pain in the breasts were subsided drastically within a month followed by decrease in the size of the swelling.

After 3 months, swelling and pain in the breast had reduced completely.

Limitation of the study: Exposing the patient to spironolactone again may lead to recurrence which is not ethical and hence rechallenge was not carried out.

Discussion: Gynecomastia was 1st described by Paulus Aegineta in 625 – 690 AD and he had explained it to be due to the formation of fat.³ Pain and swelling are the cardinal features of gynecomastia which are the effects of hormonal imbalance affecting the breast tissue. Spironolactone can cause gynecomastia by multiple mechanisms. It blocks the androgen receptors and prevents the binding of testosterone and dihydrotestosterone. It decreases testosterone production from testes by inhibiting enzymes 17 α - hydroxylase and 17, 20 - desmolase. In addition it displaces testosterone from sex hormone binding globulin and enhances the metabolic clearance of testosterone. It increases the levels of estrogen by enhancing peripheral conversion of testosterone to estradiol [4-6]. The antiandrogen action of spironolactone responsible for the development of gynecomastia depends on the dose and duration of treatment and is usually bilateral [6-8]. A study conducted by Rose *et al.*, has reported that 6 out of 16 patients with hypertension treated with spironolactone developed gynecomastia. They also found low blood testosterone levels and higher estradiol levels among these patients compared to a control which confirms hormonal imbalance as the causative factor for spironolactone induced Gynecomastia [9] Bowman *et al.*, mention that there were 63 reports of spironolactone induced gynecomastia as per US Food and Drug Administration Adverse Event Reporting System database [10]. Engbaek *et al.*, reported 5.2 % patients manifested with gynecomastia [11] Deepinder and Braunstein *et al.*, observed 10 % of 1663 heart failure patients who received 25 mg/day of spironolactone for 24 months had developed gynecomastia [12].

Differentiating true gynecomastia from lipomastia or pseudogynecomastia is difficult. The glandular tissue on palpation is a disc of firm tissue and is concentric with the nipple areolar complex in case of true gynecomastia but tissue is not of the same texture in pseudogynecomastia.

However, ultrasound of breast is recommended as 1st line investigation, followed by mammography to confirm the diagnosis. In most of the patients, stopping the offending agent is sufficient, but in those with severe pain, psychological discomfort and for cosmetic reasons, danazol, selective estrogen receptor modulator such as tamoxifen and aromatase inhibitor such as anastrozole are used.² Eplerenone, selective

aldosterone antagonist, has greater selectivity for mineralocorticoid receptors compared to spironolactone.¹³ It is about 370 times less potent in blocking dihydrotestosterone activating androgen receptors and hence lesser incidence of gynecomastia. Surgery is indicated only in long standing symptomatic cases and failure of medical management.

CONCLUSION:

Spironolactone causing bilateral gynecomastia is well established but the same bilateral presentations reported are rare/few. Eliciting proper history and performing examination can result in correct diagnosis. Stopping the offending agent resolves the problem and thereby can save the patient from embarrassment, anxiety, physical discomfort of investigations and surgical procedure. Patients should be informed about this side effect while prescribing this drug and alternatively eplerenone can be used.

Declaration of patient consent: The authors certify that they have obtained all appropriate patient consent forms. In the form the patient(s) has/have given his/her/their consent for his/her/their images and other clinical information to be reported in the journal. The patients understand that their names and initials will not be published and due efforts will be made to conceal their identity, but anonymity cannot be guaranteed.

REFERENCES:

1. Braunstein G D, Clinical practice, Gynecomastia, New England Journal of Medicine, 2007; 357: 1229- 37.
2. Barros A C, Sampaio Mde C *et al.*, Gynecomastia: Physiopathology, evaluation and treatment, Sao Paulo Medical Journal, 2012, 130: 187- 97.
3. Qutob O, Elahi B, Garimella V, Ihsan N, Drew P J, Minimally invasive excision of gynaecomastia – A novel and effective surgical technique, Ann R Collative Surgery of England, 2010, 92: 198-200.
4. Cuhaci N, Polat S B, Evranos B, Ersoy R, Cakir B, Gynecomastia: Clinical evaluation and management, Indian Journal of Endocrinology and Metabolism, 2014, 18:150- 8.
5. Loriaux D L, Menard R, Taylor A, Pita J C, santen R, Spironolactone and endocrine dysfunction, Annals of Internal Medicine, 1976, 85: 630- 6.
6. Haynes B A, Mookadam F, Male gynecomastia, Mayo Clinical Process, 2009, 84: 672.
7. Cuculi F, Suter A, Erne P, Spironolactone induced gynecomastia, CMAJ 2007, 176: 620.
8. Kauser M M, Myreddy K J, Kumarswamy R C, Manojkumar M, Jagadeesh K V, Spironolactone/Digoxin induced gynecomastia,

World J Pharm Res 2014;3:1014-8.

9. Rose L I, Underwood R H, Newmark S R, Kisch E S, Williams G H, Pathophysiology of spironolactone induced gynecomastia, *Annal Internal Medicine*, 1977; 87: 398- 403.
10. Bowman J D, Kim H, Bustamante J J. Drug induced gynecomastia, *Pharmacotherapy* 2012, 32: 1123- 40.
11. Engbaek M, Hjerrild M, Hallas J, Jacobsen I A, The effect of low dose spironolactone on resistant hypertension, *Journal of American society Hypertens* 2010, 4: 290- 4.
12. Deepinder F, Braunstein G D, Drug induced gynecomastia: An evidence based review, *Expert Opinion on Drug Safety*, 2012, 11:779- 95.
13. Pitt B, Remme W, Zannad F, Neaton J, Martinez F, Roniker B et al., Epleronone, a selective aldosterone blocker, in patients with left ventricular dysfunction after myocardial infarction, *New England Journal Medicine* 2003, 348: 1309 - 21.