



CODEN [USA]: IAJPBB

ISSN: 2349-7750

**INDO AMERICAN JOURNAL OF
PHARMACEUTICAL SCIENCES**<http://doi.org/10.5281/zenodo.1400680>Available online at: <http://www.iajps.com>

Research Article

**TREATMENT WITH SEMECARPUS ANACARDIUM EXTRACT
CURTAILS CISPLATIN INDUCED NEPHROTOXICITY AND
OXIDATIVE STRESS IN MICE**Lekshmi R^{1*}, Rajakrishnan R², Benil PB³, Alfarhan AH², Thomas J²¹ Department of Botany and Biotechnology, MSM College, Kayamkulam, Kerala, India² Department of Botany and Microbiology, College of Science, King Saud University, P.O. Box 2455, Riyadh, Saudi Arabia³ Dept. of Agadatantra, Vaidyaratnam P.S Varier Ayurveda College, Edarikode P.O., Kottakkal, Kerala, India**Abstract:**

The nephroprotective evaluation of fruits of Semecarpus anacardium has not been reported so far. It is mostly evaluated for their anti-inflammatory, hepatoprotective and anticancer activities. The present study was focused on the effect of hydroalcoholic extracts of S. anacardium (HASA) against cisplatin induced nephrotoxicity in mice. Administration of cisplatin in mice has resulted in acute renal injury which is evident from the biochemical and histological studies. Pretreatment with higher doses (400mg/kg) of HASA significantly reversed the adverse effect of cisplatin on kidney weight, serum urea, creatinine and uric acid indicating their nephro-protective effect. HASA have exhibited significant effect on the regulation of K⁺ ions in cisplatin administered mice. The antioxidant effect of HASA is evident from their significant effect on CAT, GSH-px and lipid peroxidation activities. The histopathological studies revealed that HASA has good protective effect to overcome the cisplatin induced structural damages on kidney.

Keywords: Cisplatin, Histopathology, Nephroprotective, Oxidative stress, Toxicity**Corresponding Author:****Lekshmi R,**Dept. of Botany and Biotechnology,
MSM College, Kayamkulam,
Kerala.

QR code



Please cite this article in press Lekshmi R et al., *Treatment with Semecarpus Anacardium Extract Curtails Cisplatin Induced Nephrotoxicity and Oxidative Stress in Mice.*, Indo Am. J. P. Sci, 2018; 05(08).

INTRODUCTION:

End organ toxicity is one of the major contributors in mortality from non-communicable diseases. Over the past many years, it has become increasingly obvious that human kidney is affected by an array of chemicals. Nephrotoxicity induced renal failures rank first amongst the common kidney problems affecting human kind and it mainly occurs due to the over exposure of a drug or a toxin. It is estimated that currently, there are over one million people worldwide who are alive on dialysis or with a functioning graft. Cisplatin (cis-[Pt(NH₃)₂(Cl)₂]) is an important anticancer chemotherapeutic drug used mainly against the cancers affecting head, neck, lung, testis, ovary, breast etc and it is well known that the main dose-limiting side effect of cisplatin is nephrotoxicity [1]. Even though nephrotoxicity of cisplatin has been reported since its introduction over 25 years ago, it still remains as a standard prescribed drug for the treatment of many malignancies [2]. It has been reported that acute renal injury occurs in about 21–31.5% of patients receiving cisplatin containing chemotherapy [3]. Several mechanisms including renal vasoconstriction, oxidative stress, inflammatory responses and activation of apoptotic pathways are involved in cisplatin nephrotoxicity [4]. There is a continuous search for natural renal protective agents which provide protection against kidney damage caused by cisplatin. Many plant materials have shown apparent anti-nephrotoxic activity and may provide the basis for strategies following the adverse effects of cisplatin. The medicinal properties of *Semecarpus anacardium* L. belonging to family Anacardiaceae has been mentioned in Susrutha Samhita as well as Charaka Samhitha. The milk extract of *S. anacardium* nut was reported to have significant effect against adjuvant-induced arthritis at the dose level of 150mg/kg body weight in albino Wistar rats [5]. The increased level of inflammatory cytokines like TNF- α , IL-6 and C-reactive proteins in rats was significantly brought down to normal on treatment with the nut milk extract of *S. anacardium* [6]. The effect of *S. anacardium* on carbohydrate metabolism and energy production in diabetic rats was also studied and reported [7]. The present study is an attempt to screen the nephroprotective efficacy as well as toxicity testing of the hydroalcoholic extract of the fruits of *Semecarpus anacardium* L (HASA) in Swiss albino mice.

MATERIALS AND METHODS:

Preparation of extract:

The fruits of *S. anacardium* were collected from Pathanamthitta district, Kerala, dried under shade and subjected to shodhana process for purification and

detoxification. The dried fruits of *S. anacardium* were first rubbed with brick powder to remove the acrid toxic principles present in the rind, washed with warm water and dried in shade [8]. The purified fruits were pulverized and finely sieved. Weighed quantity of coarse powders of the drugs was soaked in ethanol (99.9%) / water (1:1) in a percolator for 24 hrs. The soluble portion was filtered through a filter paper and dried on water bath in a weighed evaporating dish. The extracts were dried under vacuum and stored in desiccator until use for further analysis.

Toxicity testing:

Acute oral toxicity study:

The acute oral toxicity study of HASA was carried out in Swiss Albino mice of either sex. Approval for the experimental protocol used for study was made from the institutional animal ethical committee. Animals were housed in poly propylene cage with stainless steel top grill. All the selected animals were acclimatized for one week prior to dosing. The mice were fasted overnight and provided with water *ad libitum*. The oral formulation was prepared with suspension of HASA using 0.5% carboxy methyl cellulose. It was assessed for single dose acute toxicity by employing OECD guidelines 425 using AOT software. The mice were observed for fourteen days, for general appearance, cage side behaviour including increased or decreasing motor activity, convulsions, straub's reaction, catatonia, muscle spasm, spasticity, hyperesthesia, muscle relaxation, arching and rolling, lacrimation, salivation, diarrheal, writhing movement, mode of respiration and changes in skin colour etc.

Cell cytotoxicity study:

The cytotoxicity of HASA was tested by MTT assay according to a standard procedure [9]. The cell lines used in the study include a malignant cell line-SiHa and a non-malignant cell line-HEK-293 which were obtained from National Centre for Cell Sciences (NCCS), Pune.

Nephroprotective study:

Swiss albino mice weighing 25-30 g body weight were procured from animal house attached to Pharmacology laboratory at SDM Centre for research in Ayurveda and Allied Sciences, Udipi, Karnataka. Before the experimental study, approval of Institutional Animal Ethical Committee was taken.

Experimental design:

The animals were grouped into four different categories as mentioned below.

Group I- Normal control group

Group II- Negative control (Cisplatin 20mg/kg)

Group III- Test group I (Cisplatin 20mg/kg + HASA 200mg/kg)

Group IV- Test group II (Cisplatin 20mg/kg + HASA 400mg/kg)

For ten consecutive days the group specific drugs were administered. On eighth day, after an hour of drug administration a single dose of cisplatin (20mg/kg body weight) was injected intraperitoneally to all the experimental groups except normal control group. Then on 10th day, an hour after test drug administration the animals were sacrificed and blood was collected from retro-orbital puncture. The blood was allowed to clot and the serum was separated for biochemical estimations. The kidney was dissected out, kept in 10% formalin and used for antioxidant and histopathological studies.

Assessment of renal function

The serum was separated by centrifugation at 10000 rpm for 10 min and analyzed for the evaluation of renal function. Renal parameters such as weight of kidney, serum urea, serum creatinine, serum uric acid, serum sodium as well as potassium were estimated [10, 11, 12, 13]. To study oxidative stress, antioxidant parameters such as catalase activity [14], glutathione peroxidase activity [15] and lipid peroxidation [16] were analyzed.

Histopathological studies

Sections of kidney tissue were histopathologically examined to study the nephroprotective effect of HASA. The tissues were fixed in 10% formalin and processed according to a standard protocol [17]. The survived at such a higher concentration.

slides were examined microscopically for pathomorphological changes such as glomerular congestion, glomerular hypercellularity, interstitial oedema, necrosis, tubular casts and hemorrhage.

Statistical analysis

The experimental data were expressed as Mean± SEM. Statistical analysis was carried out by one way analysis of variance followed by Dunnet's T3 multiple comparison test. IBM SPSS Statistics Version 22 was used for the analysis of data.

Results

Acute oral toxicity studies

Acute toxicity testing of HASA in Swiss albino mice at doses of 175 mg/kg, 550 mg/kg and 2000 mg/kg by oral gavage did not reveal any signs of toxicity. Fourteen days observational study also did not reveal any drug related issues or mortality. Accordingly, the acute oral LD50 of the extractives was concluded to exceed 2000 mg/kg body weight, the highest dose tested in the study and hence 1/10th and 1/5th of 2000mg/kg was selected for the present study.

Cell cytotoxicity studies by MTT assay

The cytotoxicity of HASA was tested against malignant SiHa cells and non-malignant HEK-293 cells and tabulated (Table 1). Results showed that HASA exhibits very less cytotoxic activity against the cell lines studied. The IC 50 value of HASA against SiHa cells was 648.96µg/ml. In the case of HEK-293 cells, even the highest tested concentration (1000 µg/ml) of HASA was not toxic as more than 50% of the cells

Table 1: Cytotoxic effect of HASA on HEK-293 and SiHA celllines

Cell lines	Concentration of HASA (µg)						
	10	20	50	100	200	500	1000
	% Viability						
HEK 293	88.41±2.62	82.77±1.86	79.81±3.57	73.29±4.95	67.80±2.44	63.86±2.41	53.45±6.67
SiHA	80.56±1.51	76.38±3.00	72.75±3.73	64.20±5.18	57.73±4.05	47.73±3.09	43.31±2.47

Nephroprotective studies

To study the protective activity of HASA against cisplatin induced nephrotoxicity, weight of kidney, serum urea, creatinine, uric acid as well as serum electrolytes were estimated (Table 2).

Kidney weight

There is a significant increase in the weight in cisplatin administered group in comparison to normal control group. HASA administered at 200mg/kg has shown an insignificant decrease in kidney weight while at 400mg/kg has shown considerable

significant decrease in the weight of kidney in comparison to cisplatin control group.

Serum urea

In cisplatin administered group there was a remarkable significant increase in the serum urea level in comparison to the normal control group. The results indicated that the drug showed a dose dependent significant reduction in the serum urea level towards normal range.

Serum creatinine

In cisplatin administered group there was a significant increase in the serum creatinine level (3.0 ± 0.19 mg/dl) in comparison to normal control group (0.7 ± 0.05 mg/dl). HASA administered at a dose of 200mg/kg & 400mg/kg have shown considerable decrease in the serum creatinine level.

Serum uric acid

The concentration of serum uric acid was increased significantly by in cisplatin control group when compared to normal control group. Even though administration of HASA at both dose levels has increased the serum uric acid level in treated mice when comparison to cisplatin control group, the effect of higher dose alone was statistically significant.

Serum sodium and potassium

There was only a small insignificant increase in serum sodium level in the cisplatin administered group in comparison to normal control group. Both doses of HASA administered groups showed a minor reduction in the serum sodium level when compared to cisplatin control group and the changes were statistically insignificant. Serum potassium level was significantly decreased in the cisplatin administered group in comparison to normal control group. HASA has shown dose dependent significant increase in the serum potassium concentration when compared to cisplatin control group.

Table 2: Effect of HASA on changes in the renal parameters

Groups	Kidney weight (mg)	Urea (mg/dl)	Uric acid (mg/dl)	Na ⁺ (mmol/L)	K ⁺ (mmol/L)
Normal Control	318.00 ± 7.92	40.67 ± 1.58	2 ± 0.13	146.00 ± 2.26	5.18 ± 0.26
Cisplatin control	479.00 ± 5.68 ^{###}	133.67 ± 2.06 ^{###}	3.63 ± 0.23 [#]	148.5 ± 1.04	3.50 ± 0.24 [#]
HASA 200mg/kg	394.29 ± 9.79	47.83 ± 2.81 ^{***}	2.90 ± 0.22	148.00 ± 0.89	5.03 ± 0.17 [*]
HASA 400mg/kg	330.00 ± 10.80 ^{**}	45.20 ± 2.73 ^{***}	1.53 ± 0.35 [*]	147.00 ± 0.70	5.08 ± 0.14 [*]

Data: MEAN ± SEM, ^{###}P<0.001 in comparison to normal control group, [#]P<0.01 in comparison to normal control group, [#]P<0.05 in comparison to normal control group, ^{***}P<0.001 in comparison to cisplatin control group, ^{**}P<0.01 in comparison to cisplatin control group, ^{*}P<0.05 in comparison to cisplatin control group

In vivo effect of HASA on Kidney tissue oxidative stress markers

To investigate the antioxidant potential of HASA and its impact on cisplatin induced nephrotoxicity, oxidative stress enzyme markers such as catalase and glutathione peroxidase as well as lipid peroxidation were estimated (Table 3).

The mean concentration of catalase (CAT) in the kidney tissue of normal control rats was 98.34 ± 1.37 which was significantly reduced to 16.63 ± 2.48 in cisplatin treated rats. HASA showed a dose dependent significant increase in catalase activity when compared to the cisplatin control group.

Glutathione peroxidase (GHX-px) concentration in the kidney tissue of cisplatin control mice was $3.08 \pm$

$0.63 \mu\text{mol}/\text{mg}$ protein, whereas in normal control mice $12.04 \pm 0.65 \mu\text{mol}/\text{mg}$ protein, which indicate a significant reduction in glutathione peroxidase activity in nephrotoxic animals. Treatment with higher dose of HASA significantly increased the level of glutathione peroxidase towards the normal level.

Malondialdehyde (MDA) levels in kidney tissue, used as an index of lipid peroxidation was significantly higher (160.99 ± 8.78) in cisplatin treated group when compared to normal control group (26.98 ± 3.05). Treatment with HASA at both doses significantly decreased the MDA level when compared to the cisplatin control group.

Table 3: Effect of HASA on antioxidant parameters

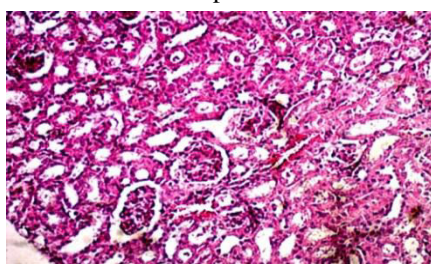
Groups	Catalase (μM of H_2O_2 consumed/min/mg protein)	Glutathione peroxidase (μM of GSH oxidized/min/mg protein)	Lipid peroxidation (μM of MDA formed/g wet tissue)
Normal Control	98.34 \pm 1.37	12.04 \pm 0.65	26.98 \pm 3.05
Cisplatin control	16.63 \pm 2.48 ^{####}	3.08 \pm 0.63 ^{##}	160.99 \pm 8.78 ^{####}
HASA 200	70.84 \pm 3.20 ^{**}	6.58 \pm 0.83	42.16 \pm 1.52 ^{**}
HASA 400	80.18 \pm 2.96 ^{**}	12.22 \pm 2.20 [*]	38.84 \pm 4.24 ^{***}

Data: MEAN \pm SEM, #### P<0.001 in comparison to normal control group, ## P<0.01 in comparison to normal control group, *** P<0.001 in comparison to cisplatin control group, ** P<0.01 in comparison to cisplatin control group, * P<0.05 in comparison to cisplatin control group

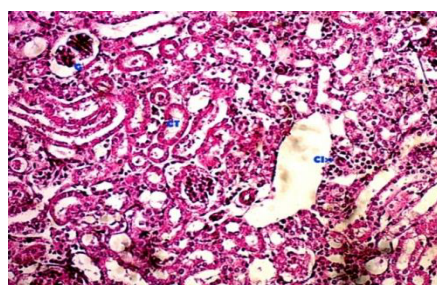
Histopathological examination of kidney tissue

Microscopic examination of the kidney sections from normal control group mice exhibited normal intact cytoarchitecture in both cortex and medulla. Glomeruli were numerous and well developed. Convoluted tubules and their epithelial lining were normal. Microscopic examination of sections of kidney from cisplatin only injected control group showed significant degenerative changes in both cortex and medulla. Cellularity of the glomeruli was decreased as well as epithelial lining of convoluted tubules showed erosion and necrotic changes. Oedematous changes were visible in the interstitial tissue, focal cell infiltration was observed at certain places, hemorrhage and degenerative changes were detected in the medulla. Microscopic examination of

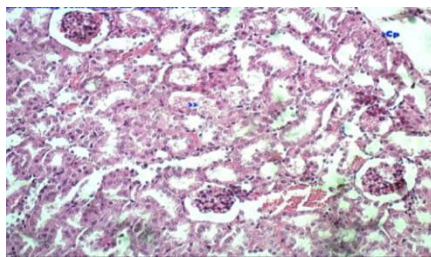
sections of kidney from cisplatin injected and HASA 200 mg/kg dose receiving mice exhibited moderate protection in comparison to cisplatin only control group. The degenerative changes in tubular epithelium were less; cell infiltration and interstitial oedema were also less. However, hemorrhage was observed in few sections. Microscopic examination of sections of kidney from cisplatin injected and HASA 400 mg/kg dose receiving mice exhibited moderate to good protection in comparison to cisplatin only control group. The degenerative changes in tubular epithelium were less; no cell infiltration could be observed in the scanned section and interstitial oedema was much less. However, hemorrhage was observed in few sections.



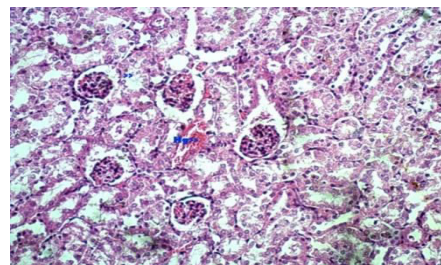
A



B



C



D

Fig. 1. Histopathological examinations in the kidney tissue sections of mice
A: Normal control; B: Cisplatin treated; C: HASA 200mg/kg treated; D: HASA 400mg/kg treated

DISCUSSION:**Toxicity studies:**

Acute oral toxicity studies revealed that HASA did not produce any mortality up to the dose of 2000mg/kg in Swiss albino mice. At the dose level studied, the drugs did not produce any observable toxic effect except for mild increase in motor activity, Straub's reaction, auditory response, irritability and rearing activity in animals who received the dose 550mg/kg and 2000mg/kg. Thus the study confirmed that test drugs are safe without any toxic potential even at the dose of 2000mg/kg in animals. *In Vitro* cytotoxicity study of HASA was made against malignant (SiHa) as well as non-malignant (HEK-293) cultured cells. The results clearly indicated the non-cytotoxic nature of HASA against the cell lines studied. Therefore HASA can be utilized for the isolation of phytochemicals with potential health protective effects and can be considered as a safe drug for other disorders.

Nephroprotective studies:

The present study demonstrated that cisplatin induced renal injury is evident from the increased kidney weight, high values of creatinine, urea and uric acid in serum, elevated concentration of malondialdehyde (MDA) and decreased level of catalase and glutathione peroxidase in kidney tissue of the experimental animals. There are many reports that weight of kidney increases by the intake of cisplatin [18, 19]. In agreement with the previous reports, the present study also revealed that there is significant increase in kidney weight in cisplatin treated experimental organisms. Weight gain of the kidney after cisplatin administration is possibly due to the renal cell injury caused by inflammation. The higher dose of HASA has shown significant effect on reducing the kidney weight in treated animals which might be due to their anti-inflammatory action.

Increased levels of urea, creatinine and uric acid in serum is associated with renal damage and considered as an index of kidney function. Among these three parameters, creatinine concentration is prior importance than the levels of urea and uric acid in the first phase of any kidney disease [20]. In the present study, administration of HASA successfully prevented cisplatin induced renal damage in mice by significantly reducing the elevated levels of urea, creatinine and uric acid in serum. The regulation of electrolytes is extremely important for the maintenance of body homeostasis and kidney plays an important role in the regulation of electrolytes. Higher doses of drugs, toxins, infectious agents, chemicals etc. can cause kidney damage and ultimately lead to electrolyte imbalance [21]. The

concentration of serum sodium did not show a significant change (only less than 2% increase) in cisplatin treated group when compared to the normal group. Similar results, however, have been reported with respect to changes in serum sodium after cisplatin treatment [22]. The present study revealed a significant decrease in potassium level after the administration of cisplatin. It is previously reported that hypokalemia, a common electrolyte abnormality occurred during cisplatin treatment due to increased renal reabsorption capacity observed in response to decreased intestinal absorption of potassium [23]. The administration of higher doses of HASA significantly increased the potassium concentration towards normal values in cisplatin treated groups, which indicates the potential to overcome potassium imbalance.

Anti-oxidant activity:

Cisplatin is a potent antitumor drug used in the front-line therapy against several human malignancies. Previous reports [24, 25] as well as the present study confirm that cisplatin administration leads to the damage of renal proximal tubules which affects the normal functioning of kidneys. The role of oxidative stress in cisplatin-induced nephrotoxicity is also reported by many researchers. Studies have demonstrated that cisplatin induces the formation of radical oxygen species in renal epithelial cells primarily by decreasing the activity of antioxidant enzymes [26]. It was reported that oxidative stress upon cisplatin administration is characterized by increased lipid peroxidation and altered non-enzymatic and enzymatic antioxidant systems [27]. Previous studies suggested that cisplatin affects the activities of antioxidant enzymes such as glutathione peroxidase and catalase [28, 29]. In this study, oxidative stress induced by the administration of cisplatin is evidenced by the reduced catalase and glutathione peroxidase levels as well as increased lipid peroxidation.

The reduction in the activity of catalase in the cisplatin treated group results in decreased ability to scavenge toxic hydrogen peroxide, further contributing to oxidative stress. HASA at both the doses showed significant dose dependent increase in catalase levels showing its capability to protect the renal parenchyma from chemical induced insult. The activity of glutathione peroxidase enzyme also got decreased following cisplatin administration. HASA showed dose related increase in the glutathione peroxidase concentration when compared to the normal control group. Administration of HASA normalizes the activities of catalase and glutathione peroxidase enzymes which might be due to the presence of free radical scavenging activity of

flavonoids present in these drugs [30, 31]. The membrane lipid peroxidation, the primary event in the tissue damage, which was found to be elevated in cisplatin control group was significantly reduced and brought towards normal by the administration of both HASA. This shows the capability of HASA to reverse the membrane damages induced by cisplatin. The results clearly indicated the antioxidant potential of HASA.

Histopathological studies:

The kidney, a vital organ for various metabolic processes and involved in the removal of many toxic components, serves as a key area of attack by various chemical agents including cisplatin. It was reported that the toxic effect of cisplatin in kidney can be clearly explained by observing the cytotoxic injury which ranges from mild sub-lethal variations to necrotic death [32]. Histopathological studies in mice kidney after cisplatin administration revealed acute tubular necrosis which confirms irreversible injury to kidney [33]. In the present study, the histopathology of kidney sections from cisplatin control group revealed necrotic changes in the tubular epithelium, oedematous changes in the interstitial tissue and focal cell infiltration. The changes observed in the present study justify the reports of other researchers [34, 35, 36]. The higher dose of HASA provide moderate to good protection by preventing the degenerative changes in tubular epithelium, cell infiltration and interstitial oedema.

Conflict of interest

The authors declare that they have no conflict of interest.

ACKNOWLEDGEMENTS:

Authors are grateful to the Director, SDM Centre for Research in Ayurveda and Allied Sciences, Udipi for providing facilities. The authors would also like to extend their sincere appreciation to the Deanship of Scientific Research, Research Centre, College of Science, King Saud University, Riyadh, Saudi Arabia.

REFERENCES:

1. Rajakrishnan R, Lekshmi R, Benil PB, Thomas J, AlFarhan AH, Rakesh V, Khalaf S. Phytochemical evaluation of roots of *Plumbago zeylanica* L. and assessment of its potential as a nephroprotective agent. Saudi Journal of Biological Sciences. 2017; 24(4): 760-766.
2. Crona DJ, Fasob A, Nishijimad TF, McGrawe, KA, Galskyf MD, Milowsky MI. A Systematic Review of Strategies to Prevent Cisplatin-Induced Nephrotoxicity, The Oncologist. 2017; 22: 609-619.
3. Sato K, Watanabe S, Ohtsubo A, et al. Nephrotoxicity of cisplatin combination chemotherapy in thoracic malignancy patients with CKD risk factors. BMC Cancer. 2016; 16: 222.
4. Peres LA, da Cunha AD Jr. Acute nephrotoxicity of cisplatin: molecular mechanisms, J Bras Nefro 2013; 35: 332-40.
5. Vijayalakshmi T, Muthulakshmi V, Sachdanandam P. Effect of the milk extract of *Semecarpus anacardium* nut on adjuvant arthritis - A dose dependent study in Wistar albino rats. Genetical Pharmacology. 1996; 27(7): 1223-1226.
6. Khan HB, Vinayagam KS, Moorthy BT, Palanivelu S, Panchanatham S. Anti-inflammatory and anti-hyperlipidemic effect of *Semecarpus anacardium* in a high fat diet: STZ-induced type 2 diabetic rat model. Inflammo pharmacology. 2013; 21(1): 37-46.
7. Aseervatham J, Palanivelu S, Panchanatham S. *Semecarpus anacardium* (Bhallataka) alters the glucose metabolism and energy production in diabetic rats. Eviden Base Complem Altern Med. 2011; <http://dx.doi.org/10.1155/2011/142978>.
8. Ilanchezhian R, Roshy JC, Acharya R. Importance of media in shodhana (purification/processing) of poisonous herbal drugs. Anc Sci Life. 2010; 30: 54-57.
9. Mosmann, T. 1983. Rapid colorimetric assay for cellular growth and survival: application to proliferation and cytotoxicity assays. J Immunol Met. 65(1-2): 55-63.
10. Tietz NW. 1976. Textbook of Clinical Chemistry, Philadelphia: W.B Saunders.
11. Cook JG. Factors influencing the assay of creatinine. Ann Clin. Biochem.1975; 12 (6), 219-232.
12. Fossati P, Prencipe L, Berti G. Use of 3,4-dichloro-2-hydroxybenzenesulfonic acid/ 4 aminophenazone chromogenic system in direct enzymic assay of uric acid in serum and urine. Clin Chern. 1980; 26 (2): 227-231.
13. Chuang FS, Sarbeck JR, Winefordner JD. Flame spectrometric determination of sodium, potassium and calcium in blood serum by measurement of microsamples. Clinical Chemistry. 2005; 21: 16-23.
14. Sinha KA. Colorimetric assay of catalase. Anal Biochem. 1972; 47: 389- 394.
15. Rotruck JT, Pope AL, Ganther HE, Swanson AB, Hafeman DG., Hoekstra WG. Selenium: biochemical role as a component of glutathione peroxidase. Science. 1973; 179:

- 588-590.
16. Ohkawa H, Ohishi N, Yagi K. Assay for lipid peroxides in animal tissues by thiobarbituric acid reaction. *Anal Biochem.* 1997; 95: 351-358.
 17. Bancroft JD, Stevens A. Theory and Practice of histological techniques. *Journal of the American Medical Association.* 1977; 238: 2730-2730.
 18. Shimeda Y, Hirotsu Y, Akimoto Y, Shindou K, Ijiri Y, Nishihori, T. Protective effects of capsaicin against cisplatin-induced nephrotoxicity in rats. *Biol Pharm Bull.* 2005; 28: 1635-1638.
 19. Ravindra DA., Kulkarni SS, Padmanabha V, Chitra Y, Dhume KU. Cisplatin induced histological changes in renal tissue of rat. *J Cell Anim Biol.* 2010; 4: 108-111.
 20. Tavafi M, Ahmadvand H, Toolabi P. Inhibitory effect of olive leaf extract on gentamicin-induced nephrotoxicity in rats. *Iranian Journal of Kidney Diseases.* 2012; 6(1): 25-32.
 21. Shimmi SC, Jahan N, Sultana N. Effects of ashwagandha (*Withania somnifera*) root extract against gentamicin induced changes of serum electrolytes in rats. *J Bangladesh Soc Physiol.* 2012; 7(1): 29-35.
 22. Vijayan FP, Rani VK, Vineesh VR, Sudha KS, Michael MM, Padikkala J. Protective effect of *Cyclea peltata* Lam on cisplatin-induced nephrotoxicity and oxidative damage. *J Basic Clin Physiol Pharmacol.* 2007; 18(2): 101-114.
 23. Arunkumar PA, Viswanatha GL, Radheshyam N, Mukund H, Belliyappa MS. Science behind cisplatin induced nephrotoxicity in humans: A clinical study. *Asian Pac J Trop Biomed.* 2012; 2(8): 640-644.
 24. Langerak AD, Dreisbach LP. 2001. *Chemotherapy Regimens and Cancer Care.* Landes Bioscience, Georgetown, Tex, USA.
 25. Hanigan MH, Devarajan P. Cisplatin nephrotoxicity: molecular mechanisms. *Cancer Therapy.* 2003; 1: 47-61.
 26. Ozbek E. Induction of oxidative stress in kidney. *International Journal of Nephrology.* 2012. doi:10.1155/2012/465897.
 27. Hawkins CL, Brown BE, Davies M.J. Hypochlorite and hypobromite mediated radical formation and its role in cell lysis. *Arch Biochem Biophys.* 2001; 395: 137-145.
 28. Husain K, Morris C, Whitworth C, Trammell GL, Rybak LP, Somani SM. Protection by ebselen against cisplatin induced nephrotoxicity: antioxidant system. *Mol Cell Biochem.* 1998; 178: 127-133.
 29. Sahreen S, Khan MR, Khan RA. Evaluation of antioxidant activities of various solvent extracts of *Carissa opaca* fruits. *Food Chem.* 2010; 122: 1205-1211.
 30. Sanz MJ, Ferrandiz ML, Cejudo M, Terencio MC, Gil B, Bustos G, Ubeda A, Gunasegaran R, Alcaraz M.J. Influence of a series of natural flavonoids on free radical generating systems and oxidative stress. *Xenobiotica.* 1994; 24: 689-699.
 31. Nile SH, Khobragade CN. Antioxidant activity and flavonoid derivatives of *Plumbago zeylanica*. *Journal of Natural Products.* 2010; 3: 130-133.
 32. Dobyn DC, Levi J, Jacobs C, Kosek J, Weiner MW. Mechanism of cisplatin nephrotoxicity: Morphologic observations, *J Pharmacol Exp Ther.* 1980; 213: 551-556.
 33. Pratibha R, Dayanand AB, Sameer K, Padmanabh VR, Chitra YD. Cisplatin induced histological changes in renal tissue of rat. *J Cell Ani Bio.* 2010; 4(7): 108-111.
 34. Devipriya S, Shyamala D. Protective effects of quercetin in cisplatin-induced cell injury in the rat kidney. *Ind J Pharmacol.* 1999; 3: 422-426.
 35. Shirwaikar A, Malini S, Kumari SC. Protective effect of *Pongamia pinnata* flowers against cisplatin and gentamicin induced nephrotoxicity in rats. *Int J Expt Biol.* 2003; 4: 58-62.
 36. Subal D, Nilesh B, Manjunath YS, Mallareddy V, Pabba P, Hariprasath K. Nephroprotective evaluation of ethanolic extract of the seeds of papaya and pumpkin fruit in cisplatin-induced nephrotoxicity. *Jour Pharma Sci Techn.* 2010; 2(6): 241-246.