



CODEN [USA]: IAJPBB

ISSN: 2349-7750

**INDO AMERICAN JOURNAL OF
PHARMACEUTICAL SCIENCES**<http://doi.org/10.5281/zenodo.1401429>Available online at: <http://www.iajps.com>

Research Article

**INCIDENCE OF BRAIN HEMORRHAGE VERSUS CEREBRAL
INFARCTION IN PATIENTS WITH CEREBRO-VASCULAR
ACCIDENTS BY COMPUTED TOMOGRAPHY (CT) SCAN**¹Nighat Naz, ²Syed Amir Gilani, ³Raham Bacha¹University Institute of Radiological Sciences & MIT (UIRSMIT)²Institute of Radiological Sciences & MIT (UIRSMIT)³University Institute of Radiological Sciences & MIT (UIRSMIT)**Abstract:**

Objective: To compare the hemisphere which is more affected by brain hemorrhage versus cerebral infarction on computed tomography.

Materials and methods: This was a comparative cross-sectional study. The study was conducted at Radiology Department Shalamar Hospital, Lahore. The duration of the study was nine months. Total 50 patients who came to Radiology Department, from OPD and wards of hospital were taken for this study. Siemens (Somatom Sensation) 64 slices CT scan machine was used to scan the patients. Report was done by radiologist and data was collected on predesigned data collection sheets.

Result: Total 50 individuals were enrolled in the study to know about the incidence of brain hemorrhage versus cerebral infarction in patients with cerebro-vascular accidents by computed tomography scan and the mean age of the patients was 60 years with a range of 36-90 ± 13.87 years. Among 50 patients 20 (40%) were females and 30 (60%) were males. Out of 50 patients 29 (58.0%) belongs middle class, 15 (30.0%) were poor and 6 (12.0%) were rich socio-economically. In 42 (84.0%) patients no brain hemorrhage was seen while in 8 (16.0%) patients brain hemorrhage was seen on CT scan. On the other hand, in 45 (90.0%) patients no cerebral infarction was noted while cerebral infarction was noted in 5 (10.0%) patients during CT scan. The incidence rate of brain hemorrhage was 16.0% while the incidence of cerebral infarction in right hemisphere was 10.0% and 24.0% in left hemisphere.

Conclusion: It is concluded from this research that Computed Tomography is reliable scanning technique for the diagnosis of brain hemorrhage and cerebral infarction. The incidence of brain hemorrhage and cerebral infarction in patients with cerebral vascular accidents was seen more in men as compared with women. The incidence was high in left hemisphere as compared with right hemisphere and brain hemorrhage.

Corresponding author:**Nighat Naz,**

University Institute of Radiological Sciences & MIT (UIRSMIT)

QR code



Please cite this article in press Nighat Naz et al., *Incidence of Brain Hemorrhage versus Cerebral Infarction in Patients with Cerebro-Vascular Accidents by Computed Tomography (CT) Scan.*, Indo Am. J. P. Sci, 2018; 05(08).

INTRODUCTION:

The human brain is at the center of the human nervous system and is a very complex organ. It can be compared to a computer because of the information that can grow and maintain, but the human brain is complicated and functional. It has a common layout similar to the brain of mammals, but it is five times larger than the normal brain of mammals of the same size. Stroke or cerebral vascular accident is a medical term used to describe an unexpected failure of nerve professional, longer than 24 hours, caused by the distortion of blood flow to the brain (1).

This is the third most important cause of death; two types of strokes are bleeding and a lack of blood. Stroke due to stroke has 20% of CVAs (2). Stroke due to clogging and obstruction of the brain involves 80% of international exposure, with significant damage among survivors. CT analogy is a common way to distinguish between two types of stroke, but not all hospitals and emergency services, which can lead to a loss of gold time. According to this number, there are many clinical findings, especially nervous system symptoms and symptoms, and some of them representing the formula for distinguishing between types of strokes based on clinical assessment. These features include non-pole or negative signs or negative or positive signs and sudden or severe start-ups, leading to a major stroke in the Department of Emergency Medical Care that leads to early diagnosis and treatment (3).

Diagnosis and immediate treatment can significantly reduce the degree of damage to the nervous system in patients after the spinal cord and the different types of stroke play a decisive role in the treatment and treatment of patients. Although a non-opaque computer scan (NCT scan) is a widely used way to remove the presence of bleeding in stroke victims due to their ability to show bleeding in the first hour after the onset of the stroke (4). Early diagnosis is important for patients with stroke. Medical discovery can be useful in dividing the type of stroke (5). Because we see ischemia in CT is that the ischemia develops the cytotoxic swelling that develops as a result of failure of a pond. They failed due to insufficient ATP supply. Increasing the amount of

brain fluid to 1% will cause a decrease in CT tolerance of 2.5 HU (6).

MATERIAL AND METHODS:

Study was conducted after approval from Institutional Review Board (IRB). Written informed consent was signed from all the participants. Information was kept confidential and patients' identification was not published. This was a comparative cross-sectional study. The study was conducted at Radiology Department Shalamar Hospital, Lahore. The duration of the study was nine months. Total 50 patients who came to Radiology Department, from OPD and wards of hospital were taken for this study. Inclusion criteria were patients with neurological problems having symptoms related cerebro-vascular accident was included in this study whereas patients without presenting symptoms of cerebro-vascular accidents was excluded from study. Data was tabulated and analyzed by SPSS version 20. The quantitative data (age, frequency etc.) was presented in form of mean and S.D and for qualitative data percentage was calculated and bar charts or pie charts was drawn.

RESULTS:

Total 50 individuals were enrolled in the study to know about the incidence of brain hemorrhage versus cerebral infarction in patients with cerebro-vascular accidents by computed tomography (CT) scan and the mean age of the patients was 60 years with a range of $36-90 \pm 13.87$ years (figure # I). Among 50 patients 20 (40%) were females and 30 (60%) were males (figure # II). Out of 50 patients 29 (58.0%) belongs middle class, 15 (30.0%) were poor and 6 (12.0%) were rich socio-economically (figure # III).

In 42 (84.0%) patients no brain hemorrhage was seen while in 8 (16.0%) patients brain hemorrhage was seen on CT scan (table # I). On the other hand, in 45 (90.0%) patients no cerebral infarction was noted while cerebral infarction was noted in 5 (10.0%) patients in right hemisphere during CT scan (table # II). However, in 38 (76.0%) patients no cerebral infarction was seen while in 12 (24.0%) cerebral infarction was seen in left hemisphere during CT scan (table # III). The incidence rate of brain hemorrhage was 16.0% while the incidence of cerebral infarction in right hemisphere was 10.0% and 24.0% in left hemisphere.

TABLES AND GRAPHS

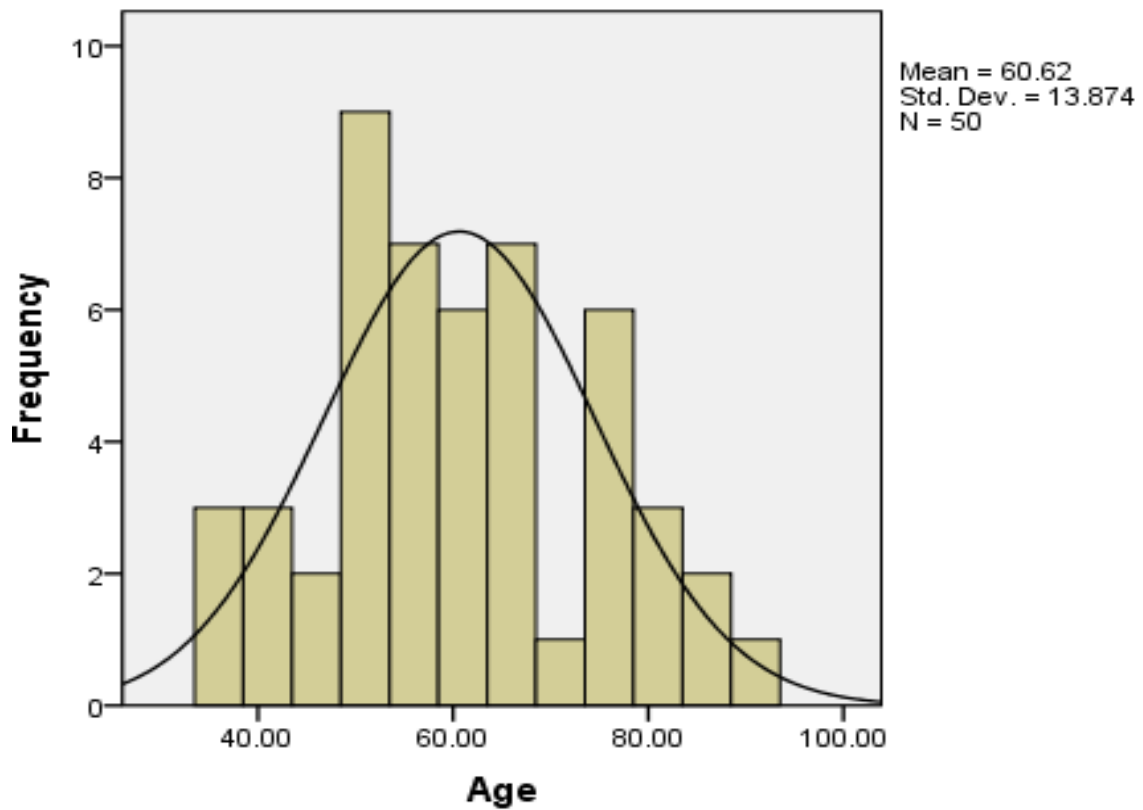


Figure-I: Age distribution of research participants

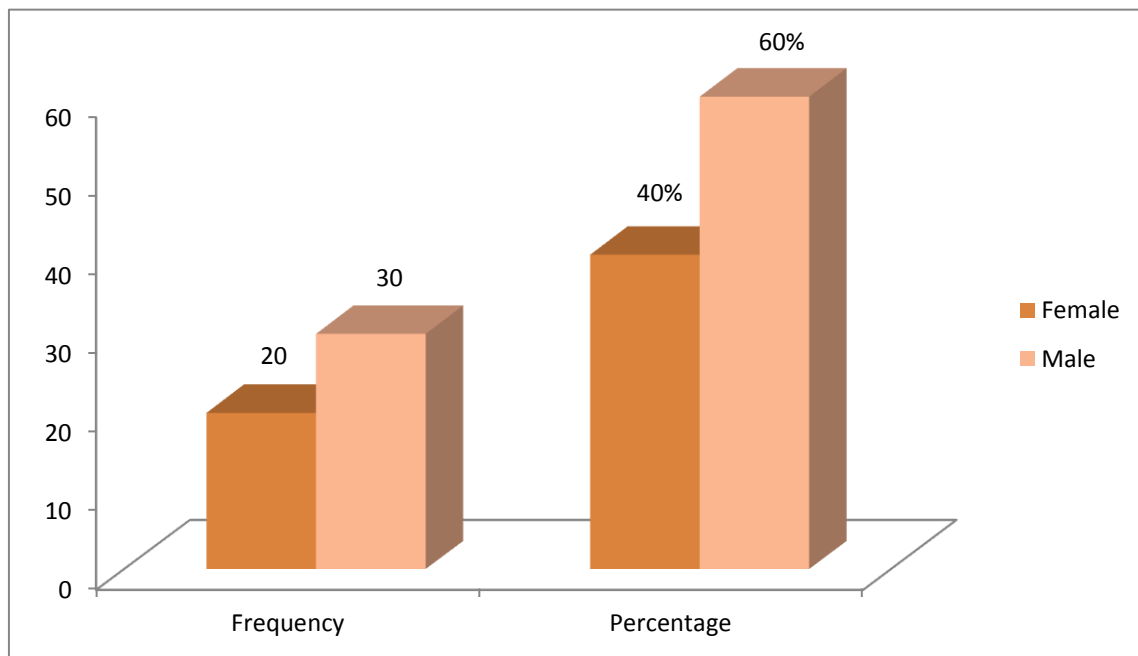


Figure-II: Frequency of gender.

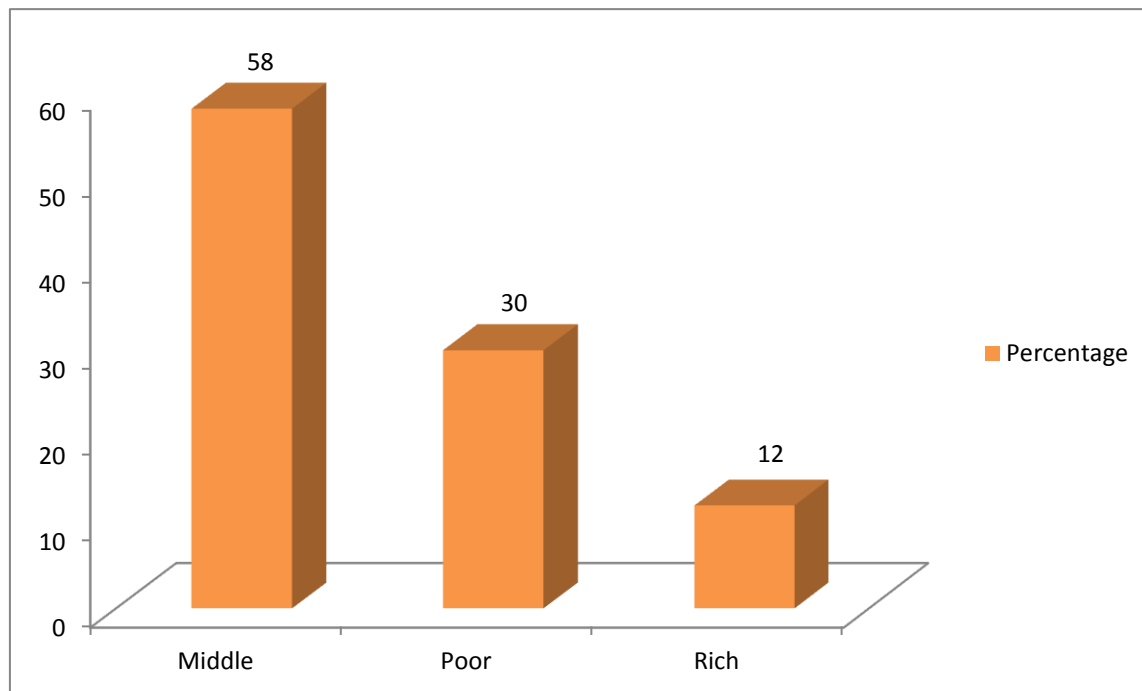


Figure-III: Frequency of socio-economic status.

Table-I: Brain hemorrhage.

| | Frequency | Percentage |
|-----|-----------|------------|
| No | 42 | 84.0 |
| Yes | 8 | 16.0 |

Table-II: Cerebral infarction in right hemisphere.

| | Frequency | Percentage |
|-----|-----------|------------|
| No | 45 | 90.0 |
| Yes | 5 | 10.0 |

Table-III: Cerebral infarction in left hemisphere.

| | Frequency | Percentage |
|-----|-----------|------------|
| No | 38 | 76.0 |
| Yes | 12 | 24.0 |

DISCUSSION:

The 2nd cause of death world widely is stroke and results in disability. And intracerebral hemorrhage is the 2nd most common subtype of the stroke and affects approximately about 10-20% of all strokes (7). Many elderly patients who have headache present to clinicians primarily concerned about the possibility of a cerebrovascular accident (CVA). Although headache is a relatively uncommon symptom of ischemic CVA, it can occur in up to 17% of patients. The headache seen in patients who have had a CVA can result from a variety of mechanisms. Current theories suggest the headache is produced by the dilatation of cerebral vessels by the embolus, dilatation of pain-sensitive collateral vessels, or irritation of vessel walls by the release of vasoactive substances. Headaches seen with CVA usually are described as dull or throbbing, with the severity of pain ranging from mild to severe. The headache can be diffuse or unilateral and commonly is associated with vomiting. In 10% of patients who have ischemic CVA, a "premonitory headache" may precede the onset of neurologic abnormalities, highlighting the importance of close follow-up and observation for any elderly patient who has a headache (8).

CT scanning is the first investigation if subarachnoid hemorrhage is suspected. The ability to detect subarachnoid hemorrhage is dependent on the amount of subarachnoid blood, the interval after symptom onset, the resolution of the scanner, and the skills of the radiologist. A false positive diagnosis of subarachnoid hemorrhage is sometimes made, especially in diffuse brain swelling, when hyperdense material in the subarachnoid space represents blood in congested subarachnoid blood vessels (9). Many studies have been published previously which shows that CT scan has high sensitivity and specificity in the early diagnosis of intracerebral hemorrhages and infarction. And systematic review was published by Henriette E et al, 2011, and the purpose of the study was to calculate the accuracy of CT angiogram in the detection of cerebral aneurysm in patients present with subarachnoid hemorrhage. And according the results the pooled sensitivity of CT was 98% and specificity is 100% (10). Most past researches have detailed defective affectability for CT scan when it is completed over a more drawn out time window. According the results of the study of Boesiger and Shiber 100% sensitivity in which 177 patients were enrolled with undifferentiated cerebral pain, yet another cohort study included just six instances of subarachnoid haemorrhage (11). Other researchers have had reflectively evaluated sensitivities of 93-98% (12, 13, 14). A meta-analysis surveyed the sensitivity of CT scan for subarachnoid hemorrhage

in view of two researches and found that the sensitivity of head CT scan for subarachnoid hemorrhage was 93%. According to another study, using CT scan, found a general sensitivity of head CT scan for subarachnoid hemorrhage of 90.5% within 24 hours of the onset of headache; be that as it may, when it was limited to patients who were neurologically in place, the sensitivity was just 80%. At last, Cortnum and associates completed a review investigation of patients with affirmed subarachnoid haemorrhage. They distinguished just a single patient who did not have positive outcomes on CT scan. This patient had deferred imaging (five days after the beginning of cerebral pain) and required lumbar puncture. The results of my research match with the results of previous studies.

CONCLUSION:

It is concluded from this research that Computed Tomography is reliable scanning technique for the diagnosis of brain hemorrhage and cerebral infarction. The incidence of brain hemorrhage and cerebral infarction in patients with cerebral vascular accidents was seen more in men as compared with women. The incidence was high in left hemisphere as compared with right hemisphere and brain hemorrhage.

REFERENCES:

1. Piliszek A, Witkowski G, Sklinda K, et.al. "Comprehensive imaging of stroke-looking for gold standard". *Neurol Neurochir Pol.* July, 2016; 50(4)241-50
2. Ojaghihaghghi S, Vahdati S S, Mikaelpour A, et.al. "comparison of neurological clinical manifestation in patients with hemorrhagic and ischemic stroke" *World J emerg med* (2015;8(1)34-38
3. Donnan GA, Fisher M, Macleod M, Davis SM. "Stroke". *The Lancet* 371 (9624). May (2014), 1612-1623.
4. Mathers CD, Boerma T, Ma Fat D, "Global and regional causes of death." *British medical bulletin* 2015;65:180-100
5. Reeves & Swenson "Disorder of Nervous system" *Cerebrovascular disorders: Ch # 27*
6. Liebeskind D S. "Hemorrhagic stroke" *Medscape: 2014;60:70-100*
7. Feigin VL, Lawes CM, Bennett DA, Barker-Collo SL, Parag V. Worldwide stroke incidence and early case fatality reported in 56 population-based studies: a systematic review. *The Lancet Neurology.* 2009 Apr 1;8(4):355-69.
8. Dodick DW, Capobianco DJ. Headaches. In: Sirven JI, Malamut BL, editors. *Clinical Neurology of the Older Adult.* Philadelphia:

- Lippincott Williams & Wilkins 2002;176.
9. Boesiger BM, Shiber JR. Subarachnoid hemorrhage diagnosis by computed tomography and lumbar puncture: are fifth generation CT scanners better at identifying subarachnoid hemorrhage?. *Journal of Emergency Medicine*. 2005 Jul 1;29(1):23-7.
 10. Westerlaan HE, Van Dijk JM, Jansen-van der Weide MC, de Groot JC, Groen RJ, Mooij JJ, Oudkerk M. Intracranial aneurysms in patients with subarachnoid hemorrhage: CT angiography as a primary examination tool for diagnosis—systematic review and meta-analysis. *Radiology*. 2011 Jan;258(1):134-45.
 11. Byyny RL, Mower WR, Shum N, Gabayan GZ, Fang S, Baraff LJ. Sensitivity of noncontrast cranial computed tomography for the emergency department diagnosis of subarachnoid hemorrhage. *Annals of emergency medicine*. 2008 Jun 1;51(6):697-703.
 12. Lourenco AP, Mayo-Smith WW, Tubbs RJ, Sidman R. Does 16-detector computed tomography improve detection of non-traumatic subarachnoid hemorrhage in the Emergency Department?. *Journal of Emergency Medicine*. 2009 Feb 1;36(2):171-5.
 13. Gee CA, Phanthavady T, McGuire T, Madsen T. 37: New Generation CT Scanners Demonstrate Higher Sensitivity for Subarachnoid Hemorrhage. *Annals of Emergency Medicine*. 2009 Sep 1;54(3):S12-3.
 14. Cortnum S, Sørensen P, Jørgensen J. Determining the sensitivity of computed tomography scanning in early detection of subarachnoid hemorrhage. *Neurosurgery*. 2010 May 1;66(5):900-3.