



CODEN [USA]: IAJ PBB

ISSN: 2349-7750

INDO AMERICAN JOURNAL OF PHARMACEUTICAL SCIENCES

<http://doi.org/10.5281/zenodo.3365560>

Available online at: <http://www.iajps.com>

Research Article

PRIAPISM FOLLOWING SPINAL ANESTHESIA IN UROLOGICAL PROCEDURES

¹Dr Fozia Saeed, ²Dr Ateeqa Azhar, ³Dr Raja Hassan Talal

¹Woman Medical Officer, Federal Government Polyclinic, Islamabad., ²Woman Medical Officer, Anesthesia Department, Allama Iqbal Memorial Teaching Hospital Sialkot., ³Medical Officer Bashir Hospital Sialkot.

Article Received: June 2019

Accepted: July 2019

Published: August 2019

Abstract:

Objective: To observe that the priapism following spinal anaesthesia in urological procedures.

Place and Time of study: Sir Ganga Ram Hospital, Lahore in 2018.

Methodology: Priapism following spinal anaesthesia for urological methods is an uncommon event. It is an irksome entanglement which may represent a test to the urologist in continuing with the medical procedure or even may result in the undoing of the elective strategy. We present an instance of the event of priapism in a hypertensive patient posted for transurethral resection of prostate after a subarachnoid square and the manner in which we oversaw it. Concentrates in the previous two decades have referenced different strategies of treating this intraoperative inconvenience, for example, the intracorporeal infusion of vasopressors, subcutaneous or intravenous terbutaline and intravenous glycopyrrolate. For our situation, we effectively managed this intricacy with intravenous glycopyrrolate.

Keywords: Priapism; Spinal Anesthesia; Phenylephrine; Glycopyrrolate.

Corresponding author:

Fozia Saeed,

Woman Medical Officer, Federal Government Polyclinic, Islamabad.

QR code



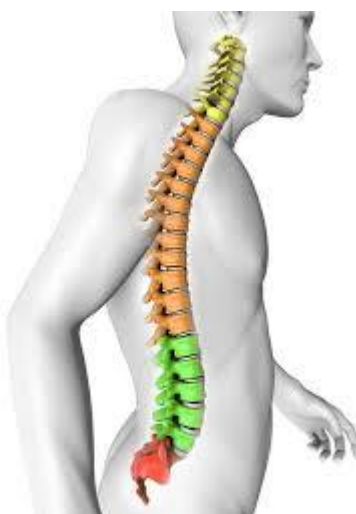Please cite this article in press Fozia Saeed et al., *Priapism Following Spinal Anesthesia In Urological Procedures.*, Indo Am. J. P. Sci, 2019; 06(08).

INTRODUCTION:

Priapism can be defined as a constant penile erection random to sexual excitation which when left unmanaged for over four hours will result in oedema, the danger of the scraped area, tissue drying and putrefaction of the penis [1,2]. The reason for priapism can be essential, optional or idiopathic [3]. Priapism under spinal and epidural anaesthesia is reflexogenic, particularly if the thoughtful bar stretches out over the midthoracic level or it could be both reflexogenic and psychogenic [4]. The reflex improvements may emerge from the incitement of the pudendal nerve by instrumentation before the complete tactile bar. We present an instance of priapism after spinal anaesthesia, which was effectively overseen by us.

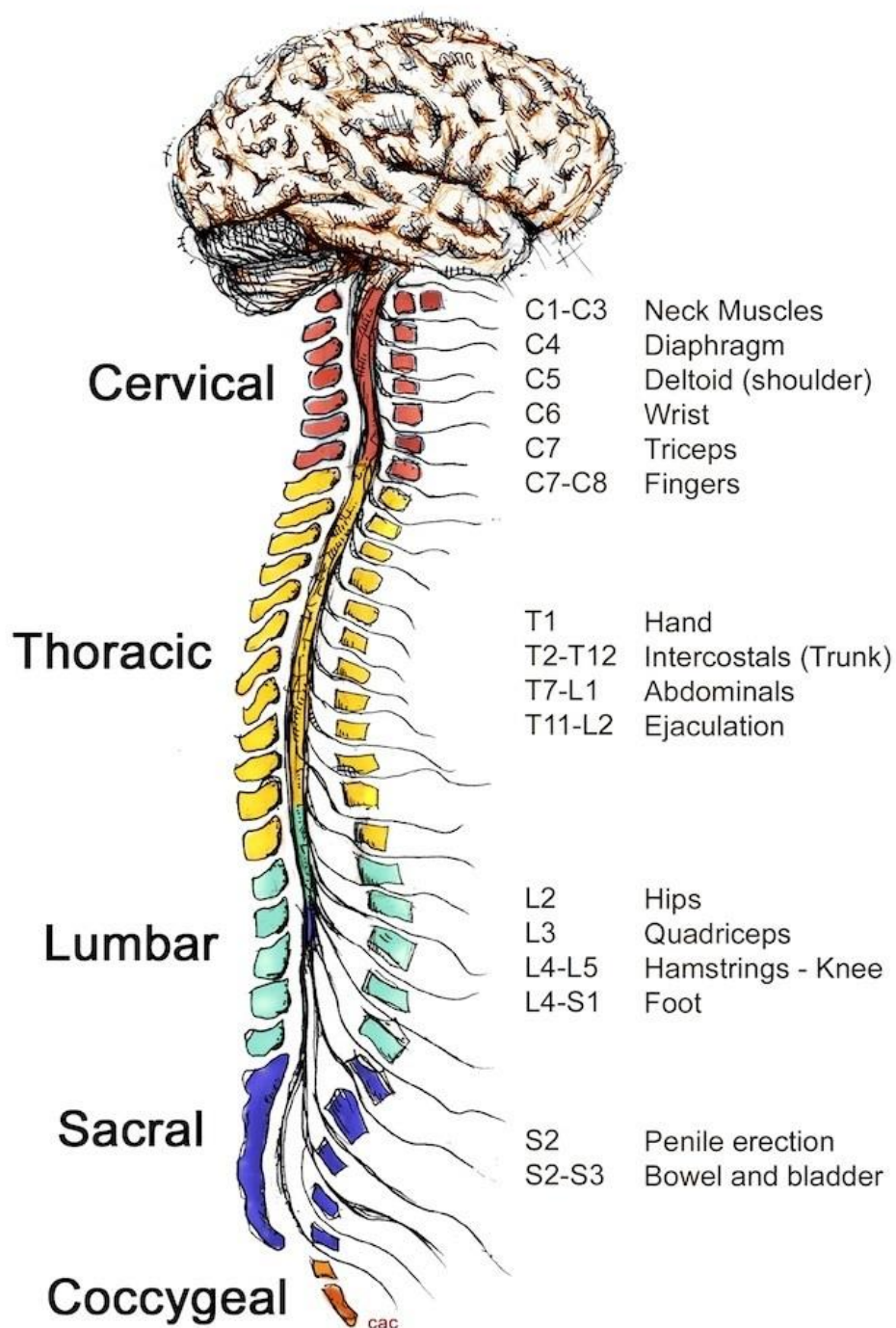
RESULT:

A multi-year old male was admitted to the emergency department of our hospital with amiable prostatic hypertrophy for TURP medical procedure. The routine preoperative assessment uncovered that he was a known hypertensive for a long time, controlled with Tab. amlodipine 5 mg once every day. Lab investigation indicated ordinary blood and pee results. Chest X beam and ECG were likewise typical. He was given spinal anaesthesia with 25 G Quincke spinal needle at L3-4 space with 2.5 ml of bupivacaine 0.5% to accomplish a tangible misfortune up to a dimension of T 10 dermatome.



The patient was situated in lithotomy, prepared and hung. The specialist passed the 26 F urethroscope through the urethra and inside 5 minutes a serious unbending erection created. The urologist couldn't continue further thus the urethroscope was expelled. We hung tight for about 30 minutes for unconstrained

detumescence which did not happen. Injection glycopyrrolate 0.2 mg IV was given. Intracavernosal infusion of phenylephrine was maintained a strategic distance from in view of his known hypertensive status.



An alternative of perineal urethrostomy was given to patient's relatives for which they were not willing. The medical procedure was cancelled and the patient was moved to the recuperation room and checked. He remained torment free all through. Steady unconstrained detumescence happened over the accompanying four hours. The patient was taken up

for medical procedure the following day under general anaesthesia which was uneventful.

DISCUSSION:

Priapism can be defined as an industrious penile erection disconnected to sexual excitation which when left unmanaged for over four hours will result

in oedema, the danger of scraped spot, tissue drying and corruption of penis. The reason for priapism can be essential, auxiliary or idiopathic [3]. Priapism with essential aetiology is not joined by confusion in charge of a drawn-out erection, might be of physical or mental origin. Secondary priapism is brought about by variables legitimately or by implication influencing the penile erection [4]. These might be hematologic for example sickle cell sickness, polycythemia, leukemia and coagulopathies; awful and careful, for example spinal string damage, penile injury or pelvic/ perineal injury; neoplastic for example metastasis, myeloma, prostatic malignant growth or penile disease; neurologic for example herniated lumbar plate, numerous sclerosis or spinal line tumors; infective for example prostates, urethritis, syphilis, intestinal sickness or diabetes mellitus; or pharmacologic for example verapamil, nitroglycerine, heparin, haloperidol, prazosin and numerous more [3]. However, penile erection under spinal and epidural anaesthesia is reflexogenic, particularly if the thoughtful bar stretches out over the midthoracic level or it could be both reflexogenic and psychogenic [1,4]. The reflexogenic improvements emerge because of incitement of the pudendal nerve (S2,3,4) with instrumentation before the beginning of complete tactile barricade. Another conceivable clarification is fragmented barricade of sacral portions of the spinal rope amid spinal anaesthesia [6,8]. While it might be psychogenic being an after effect of misrepresented sound-related sensation amid the second phase of anaesthesia [4]. The instrument of penile erection is an extremely mind-boggling marvel. In the flaccid express, the arterioles are halfway shut, while the venules and the arteriovenous channels stay open, giving an unhampered seepage of the blood vessel inflow [1]. Any reflexogenic or psychogenic upgrades will result in incitement of sacral parasympathetic outflow, causing unwinding of the corporal arterioles and incomplete conclusion of the venules and arteriovenous shunts with ensuing engorgement of the corpora prompting erection [1,7]. The impacts of the thoughtful and parasympathetic sensory system on the male sexual organ is integral. Enactment of the alpha 1 adrenergic receptor produces discharge while actuation of the M3 cholinergic receptor type produces an erection. Ordinarily, the erection dies down after thoughtfully intervened arteriolar choking with the decrease of inflow and upgraded venous drainage [1]. Detumescence is interceded by the adrenergic incitement that causes a tightening of penile venous sinusoids, opening emissary's veins and in this way expanding blood drainage [9].

Understanding the component of erection has

reformed the treatment of priapism. Different examinations have portrayed treatment choices for intra operative priapism [11]. Traditional strategies incorporate extending the plane of general anaesthesia with asynchronous acceptance of hypotension, dorsal nerve square, loss of motion, bodily desire with or without shunting methods and ketamine administration [1].

Acceptance of hypotension with sodium nitroprusside or profound general anaesthesia may bring about bringing down of blood vessel circulatory strain in older patients with coronary conduit sickness and can encourage a cardiovascular emergency [12]. The infusion of 8 ml of 0.25% of bupivacaine into the subpubic space to hinder the dorsal nerve of the penis has been observed to be effective [13,14]. Ketamine has been much of the time used to treat penile erection, has a penile loosening up property likely optional to its dissociative impact on the limbic framework, anyway, complete flaccidity happened simply after 25-110 min, speaking to a constraining factor [4,15 – 19].

The goal with a non-heparinized syringe into the base of one of the corpora cavernosa has a triumph rate of around 30% [20]. Aspiration can be joined with flushing the cavernosa with typical saline to clear the sludge blood [11]. Surgical shunts are done just when all the continuous measures come up short. The point of the careful treatment is to give a shunt between corpus cavernosum and glans penis, corpus spongiosum or a vein so that the hindered veno-occlusive system is bypassed [11]. Shunt between corpora cavernosum and glans, for example, the Winter's strategy, is sensible introductory technique, despite the fact that its achievement in keeping up detumescence has been questioned [21]. In fizzled and safe cases, a more definitive shunt like the cavernospongiosum shunt can be performed which has a triumph rate of around 75% [20,22,23]. Intracorporeal infusion of phenylephrine 250 priapism in spinal anaesthesia micrograms has been prescribed by specific creators. Detumescence happened quickly in all patients with a solitary injection [24,25]. These operators produce detumescence by diminishing the blood supply to or increment blood seepage from the corpora cavernosa through the initiation of the adrenergic receptors. The unadulterated alpha 1 agonistic movement needs unfavourable heart impacts, for example, hypertensive emergency or aspiratory oedema [26]. This makes it a more secure medication when contrasted with epinephrine, norepinephrine, metaraminol which has extra beta 1 activity in charge of the antagonistic foundational and cardiovascular

effects [1]. The utilization of terbutaline subcutaneously or intravenously (0.25 – 0.5 mg) have been suggested by specific creators. It is thought to loosen up the whole smooth muscle of the corpora cavernosum bringing about flaccidity of the whole penis and unwinding of the tunica albuginea, along these lines expanding the blood flow in the venules and arteriovenous channels and creates detumescence [4]. Injection of intracavernosal phenylephrine may cause torment, hematoma, disease, fibrosis of the penis and unplanned intravenous infusion may cause an extreme change in the hemodynamic status of the patient, the explanation behind which the medication was kept away from in our patient and glycopyrrolate was utilized. The utilization of intravenous glycopyrrolate to treat intraoperative penile erection in patients getting ceaseless spinal anaesthesia proposes a parasympathetic cholinergic aetiology [28]. The creators who concentrated the utilization of glycopyrrolate have observed it be a protected medication that can be utilized in patients with coronary course malady or in circumstances where cardiovascular dependability is deserved [28]. This was the reason that we wanted to utilize this medication in our patient, with a complete yet moderate beneficial outcome.

CONCLUSION:

Although, intraoperative priapism is an irregular condition, it warrants genuine and critical consideration. Treatment ought to be immediately started to improve the venous waste of the engorged corpora cavernosa, generally drawn out venous stasis prompts thickness and sludging, that may result in irreversible debilitation of the different courses of venous return. Glycopyrrolate created detumescence because of its ant cholinergic property, which might be the aetiology in the above case, and it demonstrated to be protected and dependable even in a hypertensive patient who experienced priapism following spinal anaesthesia.

REFERENCES:

- Walther PJ, Meyer AF, Woodworth BE. Intraoperative management of penile erection with intracorporeal phenylephrine during endoscopic surgery. *J Urol.* 1987; 137:738–739
- Brindley GS. Pilot experiments on the actions of drugs injected into the human corpus cavernosum penis. *Br J Pharmacol.* 1986; 87:495–500
- Mantadakis E, Ewalt DH, Cavender JD, Rogers ZR, Buchanan GR. Outpatient penile aspiration and epinephrine irrigation for young patients with sickle cell anaemia and prolonged priapism. *Blood.* 2000;95:78–82
- Valley MA, Sang CN. Use of glycopyrrolate to treat intraoperative penile erection: case report and review of the literature. *Reg Anesth.* 1994; 19:423–428
- Baltogiannis DM, Charalabopoulos AK, Giannakopoulos XK, Giannakis DJ, Sofi kitis NV, Charalabopoulos KA. Penile erection during transurethral surgery. *J Androl* 2006; 27:376-80.
- Greene NM. *Physiology of spinal anaesthesia.* 3rd ed. Baltimore: William and Wilkins; 1981.
- Pertek JP, Coissard A, Artis M. Dorsal nerve block for intraoperative management. *Reg Anesth.* 1996; 21: 491 -492.
- Shantha TR. Intraoperative management of penile erection by using terbutaline. *Anesthesiology.* 1989; 70: 707 -709
- Valley MA, Sang CN. Use of glycopyrrolate to treat intraoperative penile erection: case report and review of the literature. *Reg Anesth.* 1994;19: 423 -428
- Brindley GS. Pilot experiments on the actions of drugs injected into the human corpus cavernosum penis. *Br J Pharmacol.* 1986;87: 495 -500
- Walther PJ, Meyer AF, Woodworth BE. Intraoperative management of penile erection with intracorporeal phenylephrine during endoscopic surgery. *J Urol.* 1987; 137: 738 -739.
- Benzon HT, Leventham JB, Ovassapian A. Ketamine treatment of penile erection in the operating room. *Anesth Analg.* 1983; 62: 457 -458
- Ravindram RS, Dryden GE, Somerville GM. Treatment of priapism with ketamine and physostigmine. *Anesth Analg.* 1982; 61: 705 -707
- Gale AS. Ketamine prevention of penile tumescence *JAMA.* 1972;219: 1629
- Seftel AD, Resnick MJ, Boswell MV. Dorsal nerve block for the management of intraoperative penile erection. *J Urol.* 1994; 151: 394 -395
- Bosch RJ, Benard F, Aboseif SR, Stief CG, Lue TF, Tanagho EA. Penile detumescence; characterization of three phases. *J Urol.* 1991; 146:867-71
- Van Arsdalen KN, Chen JW, Smith MJ. Penile erections complicating transurethral surgery. *J Urol.* 1983; 12: 374 -376.
- Montague DK, Jarrow J, Broderick GA, Dmochowski RR, Heaton JPW, Lue TF, et al. Guideline on the management of priapism. 49 *Anaesth, pain & intensive care*; vol 16(1) Jan-Apr 2012 case report Linthicum, MD. American Urologic Association Education and Research, Inc., 2003

19. Hossein Sadeghi-Nejad, Alan D. Seftel. Aetiology, diagnosis and treatment of priapism. *Curr urology reports*. 2002; 3:492-498
20. VanderC. Horst, Henrik Stuebenger, Christopher Seifertal. Priapism, Etiology, pathophysiology and management. *Braz J Urol*. 2003; 29:391-400.
21. Weiss HD. The Physiology of human penile erection. *Ann Intern Med*. 1972; 76:707-709
22. Benzon HT, Leventham JB, Ovassapian A. Ketamine treatment of penile erection in the operating room. *Anesth Analg*. 1983; 62:457-458.
23. Ravindram, R.S., Dryden, G.E. & Somerville, G.M. Treatment of priapism with ketamine and physostigmine. *Anesth. Anal* 1982; 61:705-707.
24. Montague DK, Jarrow J, Broderick G A. et al. American Urological Association guidelines on the management of priapism. *J Urol* 2003. 170:1318-1325.
25. Nixon R G, O Connor JL, Milam DF. Efficacy of shunt surgery for refractory low flow priapism: A report on the incidence of failed detumescence and erectile dysfunction. *J Urol* 2003. 170:883-886.
26. Grayhack JT, MC Cullough N, O Connor V, Jr et al. Venous bypass to control priapism. *Invest Urol* 1964. 1:509-513.
27. Quackles R. Cure of a patient suffering from priapism by caverno-spongiosa anastomosis. *Acta Urol Belg* 1964. 3:25
28. McNicholas TA, Thomson H, Rogers HS. Pharmacological management of erections during transurethral surgery. *Br J Urol*. 1989; 64:435-437.