



CODEN [USA]: IAJPB

ISSN: 2349-7750

## INDO AMERICAN JOURNAL OF PHARMACEUTICAL SCIENCES

<http://doi.org/10.5281/zenodo.3365568>

Available online at: <http://www.iajps.com>

Research Article

### A RESEARCH STUDY TO PERFORM STOMA FORMATION AND TO KNOW THE POSSIBLE OUTCOMES AFTER THE PROCEDURE DONE AT TERTIARY CARE HOSPITAL

<sup>1</sup>Dr Muhammad Nabeel Ikram, <sup>2</sup>Dr Muhammad Salman Saleem, <sup>3</sup>Dr Muazzam Ali  
Sanaullah

<sup>1</sup>Faisalabad Medical University Faisalabad.

**Article Received:** June 2019

**Accepted:** July 2019

**Published:** August 2019

**Abstract:**

**Background:** Short term stoma formation is a common technique which is done during laparotomy.

**Objective:** Main aim of this study was to discover how to perform stoma formation and to know the possible outcomes after the procedure done at tertiary care hospital.

**Patients & Methods:** This study was done at Jinnah hospital, Lahore. This research included patients admitted in the hospital from March 2017 to July 2019. Eighty patients were taken in this regard. Stoma formation was being done on them. Age, sex and type of stoma formation was also noted down. Methods for stoma reversal were based on the kind of stoma formation according to standard international protocols. The early postoperative outcome was recorded. Stoma reversal was after 90 days, which has been proved medically that this is the exact time period that ensures resolution of dense abdominal adhesions.

**Results:** Sign of stoma formation was usually typhoid perforations 42 (52.5%), firearm injuries 13(16.25%) and Uterine Dilatation & Curettage 09 (11.25%). Most patients (64) were smoothly recovered. Superficial surgical site infection (SSI) was found in 5 (6.2%) patients and deep SSI in 03 (3.75%). Anastomotic dehiscence effected 02 of them. On one patient of these two, the temporary stoma was re-made, while the other one recovered on conservative management. 6 (7.5%) patients had to face small wound disturbances.

**Conclusion:** In the western world, stoma formation and its signs are different than this region. Attempts should be made to diagnose the disease at an early stage before it reaches the dangerous level.

**Keywords:** Stoma, Formation, Uterine Dilatation, Infection, Surgical, Superficial and Wound.

**Corresponding author:**

**Dr. Muhammad Nabeel Ikram,**  
Faisalabad Medical University Faisalabad.

QR code



Please cite this article in press Muhammad Nabeel Ikram et al., A Research Study to Perform Stoma Formation and to Know the Possible Outcomes after the Procedure Done at Tertiary Care Hospital., Indo Am. J. P. Sci, 2019; 06(08).

**INTRODUCTION:**

Those patients who have abdominal sepsis, injuries in the large intestine and profound shock are commonly treated using a technique of laparotomy called Temporary Stoma formation. Common methods are loop ileostomy and loop colostomy. A doubtful habit is required for early cure purposes. 13% of women who show themselves up to a surgeon with an acute abdomen have gynaecological problems [1]. Similarly, those patients who go to gynaecologist may have surgical problems especially presenting after dilatation and curettage. From all patients, 20 to 40% of patients who showed up at tertiary care hospital after crime was in a need of ileostomy or colostomy [2]. It should be kept in mind that even modern and latest techniques of technology are not free of complications [3]. Obstructing rectal cancer managed by an initial operation such as Hartmann's Procedure or resection and anastomosis and temporary covering colostomy has a high rate of Morbidity and mortality i.e. 39% and 12% respectively [4]. During the post-operative time period, SSIs ranging from common SSIs to organ space infections anastomosis leak and abdominal abscess formation are faced [5]. To describe the indication for stoma formation and to show the early results after its reversal were the prime objectives of this study.

**PATIENTS & METHODS:**

80 patients, admitted in Jinnah hospital, Lahore from March 2017 to July 2019, on whom stoma reversal was carried out were the subjects of our study. This department can manage patients belonging to all groups of ages. All of the patient's early history of diagnosis, previous operation notes and physical examination were recorded. Laboratory investigations including blood profile, urine profile, serum sugar, and serum urea and serum electrolyte and histopathology were performed. Kink, adhesion or missed perforation in distal lumen of gut contrast study (LOOPOGRAM) were done in order to check any obstruction. Every single patient encountered

general anaesthesia with endotracheal intubation and muscle relaxation. The stoma was mobilized and closed as their standard international protocols taking care of aseptic measure. The wound of stoma was eventually closed on the line of Incisional hernia repair. On the will of operating surgeon, skin defects were closed basically but were left open at a time for primary closure. All the patients were followed up in the postoperative period. All of them were included in this study irrespective of the age, sex etc. Age, sex, cause of stoma creation, a technique used for reversal and the early postoperative result were noted down. Stomas of all the patients were reversed after 90 days, which has been proved medically that this is the exact time period which ensures resolution of dense abdominal adhesions. Inter loop and peritoneal adhesions are the cause of stoma dehiscence.

**RESULTS:**

80 subjects were taken for the study. Patients of age from 20-40 were quite effective (Table-1). Just 5 of them were more than 40 years old and only 9 of them less than 10 years old. Stoma formation was done more in male as compared to females (Table-1). 64 patients with reversed stoma were those who had ileostomy while the other 16 had a colostomy. Post typhoid perforation dominated the group of patients with an ileostomy. Colostomy group had firearm injuries in common. Criminal septic abortions causing the uterine and intestinal perforations were the main causes of dilatation and uterine curettage. The heterogeneous group included one case each of Volvulus of sigmoid colon, Idiopathic and Iatrogenic injury. (Table: I). In the loop stomas with an intact mesenteric border of intestine partial anastomosis, in form of enterostomy was performed. End to end anastomosis was needed to do in rest of the cases. We examined the result. When the patient underwent it, without any complication, we called it smooth recovery. These patients were discharged. If due to any complication patient had to stay in the ward for medication or surgical intervention, we noted that down too.

**Table – I:** Demographic, clinical and pathological data for patients who had surgery for stoma reversal

Characteristics	Frequency	
	No. of Patients	%age
<b>Age</b>		
<10	09	11.25%
11-20	18	22.50%
21-30	21	26.25%
30-40	26	32.50%
>40	06	07.50%
Sex ratio (M: F)	55:25	7:3
<b>Type of Stoma</b>		
Loop ileostomy	61	76.25%
Loop colostomy	12	15%
Hartmann procedure	04	5%
End Ileostomy & Mucus Fistula	03	3.75%
<b>Causes/Indications</b>		
Typhoid perforation	42	52.50%
Firearm injury	13	16.25%
Uterine Dilatation & curettage	09	11.25%
Postoperative dense adhesions	04	05%
PSARP*	03	3.75%
Tuberculosis	02	2.50%
Gangrene of Large gut	02	2.50%
Intussusceptions leading to gut gangrene and severe sepsis	02	2.50%
Miscellaneous group	03	3.75%

\* Posterior Sagittal Ano Recto Plasty.

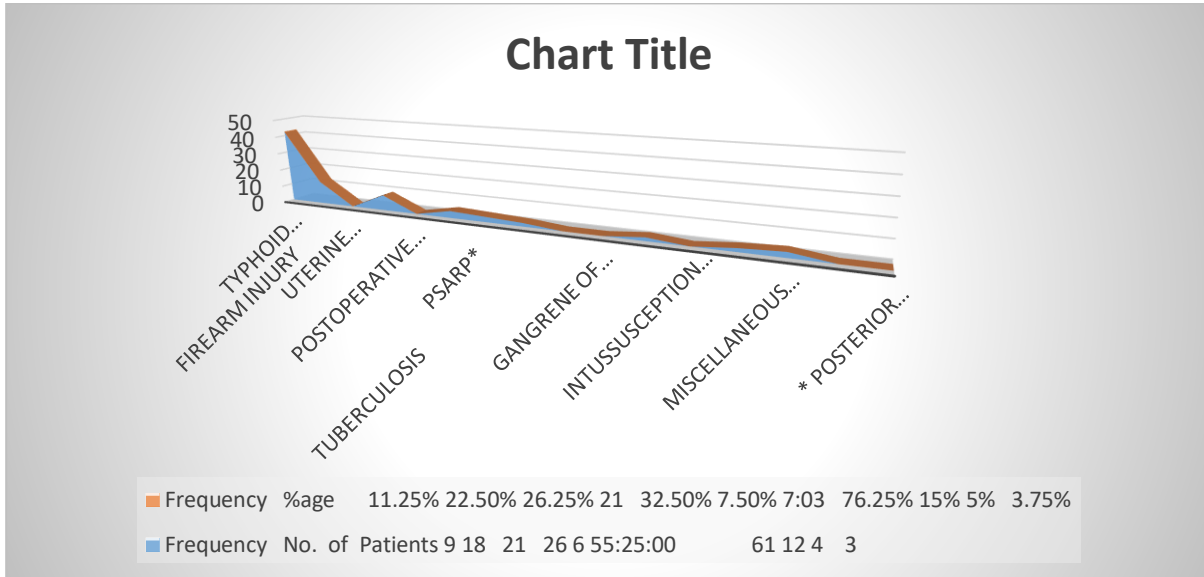
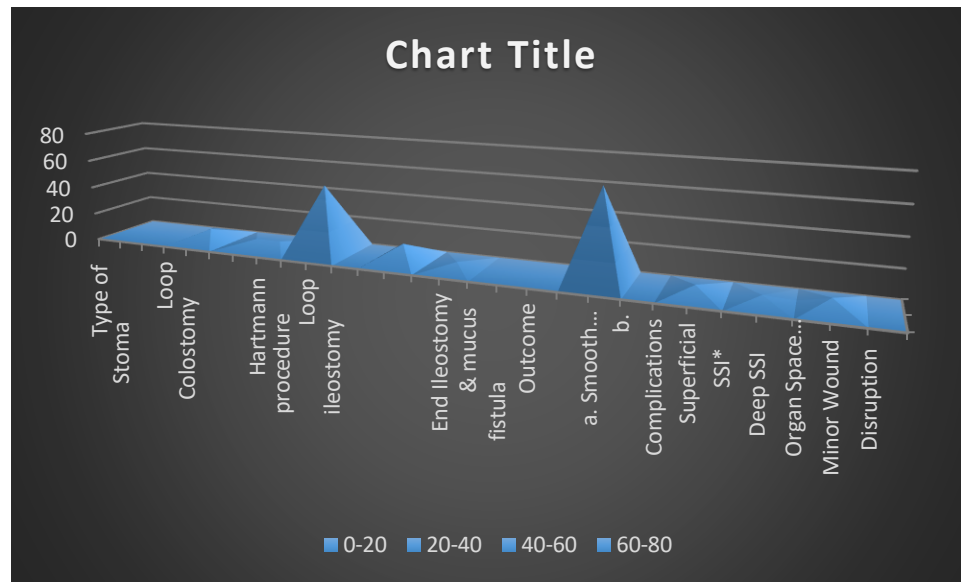


Table – II: Stoma type & outcome of patients

Type of Stoma	Procedure	No.	%age
Loop Colostomy	Reversal of Stoma Enterostomy closure end to end anastomosis	08	10%
		04	05%
Hartmann procedure	Laparotomy, mobilization of stoma and closure	04	05%
Loop ileostomy	Reversal of Stoma Enterostomy closure end to end anastomosis	49	61.25%
		12	15%
End Ileostomy & mucus Fistula	Laparotomy, mobilization of stoma and closure	03	3.75%
<b>Outcome</b>			
a. Smooth recovery		64	80%
b. Complications			
Superficial SSI*		05	6.25%
Deep SSI		03	3.75%
Organ Space infection		02	2.5%
Minor Wound Disruption		06	7.5%



\*Surgical site infections.

Injury caused to the guts unintentionally leading the gut contents to pour outside of the body or in the peritonitis were the main causes of organ infection. The refashioning of stoma of one patient was done and he was asked to do rest for further 90 days. The other patient was kept in continuous care. It was because he had dense adhesion around the gut and a hard stoma mobilization during the operation and that's how this patient was recovered by conservative treatment.

### DISCUSSION:

Our most subjects were 20 to 40 years old. But, with many kinds of prime causation like Ulcerative colitis and Crohn's disease [1]. Crohn's disease is not usually found in Pakistan [6]. Another group, including patients of 60 years of age had colorectal cancer, in the west. But none of them is included in our study. Due to the development of technology, the rate of stoma formation is decreasing in countries like USA and Canada. Abdominoperineal resections have been decreased due to endoluminal techniques. Bacterial load and mortality are being reduced by using helpful operational techniques like planned re-look laparotomy and continuous closed peritoneal lavage [7,8]. The use of temporary loop ileostomies has been enhanced due to surgical methods. These are more difficult to manage [9] and if we take a look at our study, typhoid perforation, firearm injuries and criminal abortions have the most part in stoma formation. A nasogastric tube is not being used as well as recommended [11] even after colorectal

cancer because its use has been compromised [10]. But we have been using it at all patients. In the study, of Ayyub et al, the anastomotic leak was 4.7% and 8.7% in single layer versus and in two layers anastomosis respectively. Missed perforation in our research was 2.5% with no mortality. Wound infection in another study was recorded to be 7.1% as an intra-abdominal abscess. Which is, quite higher as compared to our study [12]. In our study, we found 6.25% and 3.75% of superficial and deep wound infection. Slight wound cleavage was found to be 7.5%. Every single patient was cured at conservative management. This shows that the caring of patients while his stay at the hospital has been increased in Punjab as studied by Akram et al [13]. Our study included all those patients who had a stoma. When compared to colostomy, under controlled conditions, basic fixing of colonic injuries can be beneficial [14]. We have to use a skin closure modification technique in patients of high risk [15]. But, then we have to face hardships in the reconstruction of the intestinal tract and abdominal wall [16]. Resection of gut and colostomy is very much expensive for both the patient and the hospital. Doing resection and primary anastomosis efficiently is quite enough success [17].

### CONCLUSION:

As compared to the western world, we see that the result of stoma formation in Pakistan is quite different. Complications and difficulties in curing these diseases have been decreased in other western

countries because of proper referral, timely diagnosis and management. To save the patients from morbidity and mortality, efforts should be made to improve the diagnosis techniques. Primary, secondary and tertiary systems should be improved for early cur of diseases like typhoid, trauma and perforation etc.

#### REFERENCES:

1. Shah J, Subedi N, Maharjan S. Stoma Reversal, A Hospital-Based Study of 32 cases. The Internet Journal of Surgery- 2010 (V) 22, No. 1: 1528-8242.
2. Khan, R., Abbas, Z., Memon, S., Hamid, S., Shah, H. and Jafri, W. Clinical presentation of Crohn's disease in Pakistan. Journal of Gastroenterology and Hepatology, vol.16 Jan. 2001 21-26
3. Berger D, Buttenschoen K. Management of abdominal sepsis. Langenbeck Archives of Surgery, vol. 383 No 1 March 1998: 35-43
4. Jeffery BA, Sebastian MW, Amin T Et al. Multiple Laparotomies for Severe Intra-Abdominal Infection Wiley Inter-Science, Anz JS. Jan. 2010 (v) 68 issue 2: 139-142
5. Ira J. Kodner, Marigot's Intestinal Stoma. Abdominal operation tenth edition Michael J Zimmer, Seymour J, Schwartz, Harold Ellis Appleton and Lange. 427-460, 1997.
6. Qureshi U, Hanif M, Zia N, et al Role of Nasogastric intubation after Small bowel anastomosis JCPSP. 2009 VOL. 19: 354-358.
7. James A, Catten Dilip, N.Lebo. The use of drains after gastrointestinal surgery. Recent advances in surgery. Irvin Taylor. Colin Johnson. 2009 published by RSM Press. 13-26.
8. Ayyub M, R. Sheikh. S Gangat et al. Single layer versus two-layer intestinal anastomosis prospective study Pak J of sur.vol.5, Issue 3,241-243.
9. Akram A, Ibrar S Shah H et al Status of Hospital Infection Control Measures of Seven Major Tertiary Care Hospitals of Northern Punjab JCPSP. 2010 VOL. 2 (4): 266-270
10. Zaheer S, Butt HA. Primary Repair Versus Colostomy an Experience at Mayo Hospital. Professional Med J. March 201. 73-77
11. Connolly, Patrick T, Teubner et al Outcome of Reconstructive Surgery for Intestinal Fistula in Open Abdomen Annals of Surgery. March 2008; col.247(3) 440-444
12. Murtaza B, Khan AN, Sharif AM, et al. Modified Midline Abdominal Wound Techniques in Complicated High-Risk Laparotomies. JCPSP. 2010; vol. 20(1): 37-4.
13. Naseer A, Ahmed S, Naeem M et al. One Stage Emergency Resection and primary anastomosis for sigmoid volvulus JCPSP. 2010 Vol. 20(5); 307-9.
14. Sardar SA, Nausheen S, Zahid M et al. condition presenting to the general surgeon as an acute abdomen. Annals volume (15) No.3 July- Sept.; 2009: 146-8
15. Tabassum HM, Chaudhary MA, Haq MU. Surgical Complications of abortions at Periphery Annals vol.10 No. 4 Oct-Dec 2004.479-481
16. Tufail A, Naheed F. Complication of diagnostic laparoscopy for gynecological indication. PJS. vol. 25, no.3 July-Sep. 2009:164-166
17. Kenneth L, Meredith, Sara et al. The Multidisciplinary Management of Rectal Cancer. Surgical Clinics of North America. Feb.2009 Volume (4) No.1 177-215.