CODEN [USA]: IAJPBB ISSN: 2349-7750

INDO AMERICAN JOURNAL OF
PHARMACEUTICAL SCIENCES

SJIF Impact Factor: 7.187
http://doi.org/10.5281/zenodo.3978944

Available online at: http://www.iajps.com *Research Article*

THE IMPACT OF HIGH FIELD MRI ON MERCURY RELEASES FROM DENTAL AMALGAM FILLINGS

[1]Dr Maha Butt, [2]Dr Muhammad Yasir Naeem, [1]Dr Areeba Shaheen Elahi
[1]Islamic International Dental Hospital Islamabad
[2]Multan Medical and Dental College Multan

Article Received: June 2020 **Accepted:** July 2020 **Published:** August 2020

Abstract:
Mercury is one of the most harmful non-radioactive components, which can be harmful even to small portions. A few surveys have shown the occurrence of mercury from dental amalgams in folks who used a cell phone. Our current research was led at Islamic International Dental Hospital from March 2018 to February 2019. The purpose of this review was to investigate the impact of high field MRI on mercury releases from dental amalgam fillings. We considered two gatherings of liners through dental decay needing a comparable example of restorative dentistry. They were presented to an attractive movement thickness of 1.5 T created by an MRI machine. 18 in any case sound liners with indistinct tooth decay participated in this investigation. They were subject to comparative corrective measures and randomly from two-gun rallies not covered by the MRI and control. Urinary mercury convergences in control patients were estimated previously (hour 0) and 3 and 4 days after amalgam recovery, using cold smoke nuclear ingestion spectrometry. Urinary mercury centralizations in uncovered persons were resolved earlier (hour 0), Moreover, 2, 3, 4 and 5 days after amalgam recovery. In contrast to the control subjects, they experienced MRI of the ordinary mind (17 min, 96 slices), 24 hours after amalgam recovery. The average ± SD Urinary mercury levels in people not covered by MRI rose directly from a standard estimate of 20.70±18.97 to 25.84±23.92 µg/L 72 hours after MRI. In reference group, fixation reduced directly from 21.71±21.78 to 17.15±21.06 µg/L. The contrast among Mercury in open in addition control collection, 72 hours after MRI (96 hours after remediation), was critical (p=0.047). Those results offer additional support for the adverse effects of MRI (introduction to field of solid attractiveness) and the arrival of mercury from dental amalgam contents.

Keywords: Impact of high field MRI, mercury releases from dental amalgam fillings.

Corresponding author:
Dr. Maha Butt,
Islamic International Dental Hospital Islamabad

QR code

Please cite this article in press Maha Butt et al, ***The Impact Of High Field MRI On Mercury Releases From Dental Amalgam Fillings.,*** *Indo Am. J. P. Sci, 2020; 07(08).*

INTRODUCTION:

Mercury is one of the most harmful substances in the world. non-radioactive elements, and can cause intoxication even at little quantities [1]. Dental amalgam, which is one of most important the materials most commonly used in therapeutics dentistry, was utilized for of 170 years. This comprises approximately half natural mercury and a mixture of silver, tin, copper and zinc [2]. The degree of mercury fumes, which are produced from dental amalgams reconstruction efforts, only in stages biting, eating, brushing teeth and drinking hot liquids. The welders have demonstrated that electromagnetic technology (EMC) can adjust the disappearance of mercury from dental amalgam restorative efforts [3]. X-rays are an effective and ever-expanding means of communication. indicative clinical imaging methodology. During the system, cases are presented to attractive static and tilt fields also as electromagnetic radiation in the field of radio repetition. In previous years, our research center has focused on studying the impacts on the well-being of the introduction of creatures and humans into research facilities to some normal sources of EMF [4], for example, mobile phones and their base 9.7 PCs, and mobile phone jammers, just like the words EMF presentation produced by dental citron or radar. We have previously indicated that the submission at 0.25 T MRI has fundamentally broadened the average ± SD salivary mercury level of 9.7±4.1 mg/L before MRI at 12.4±6.4 mg/L 17 min after imaging, in 40 persons through dental amalgam restorations [5].

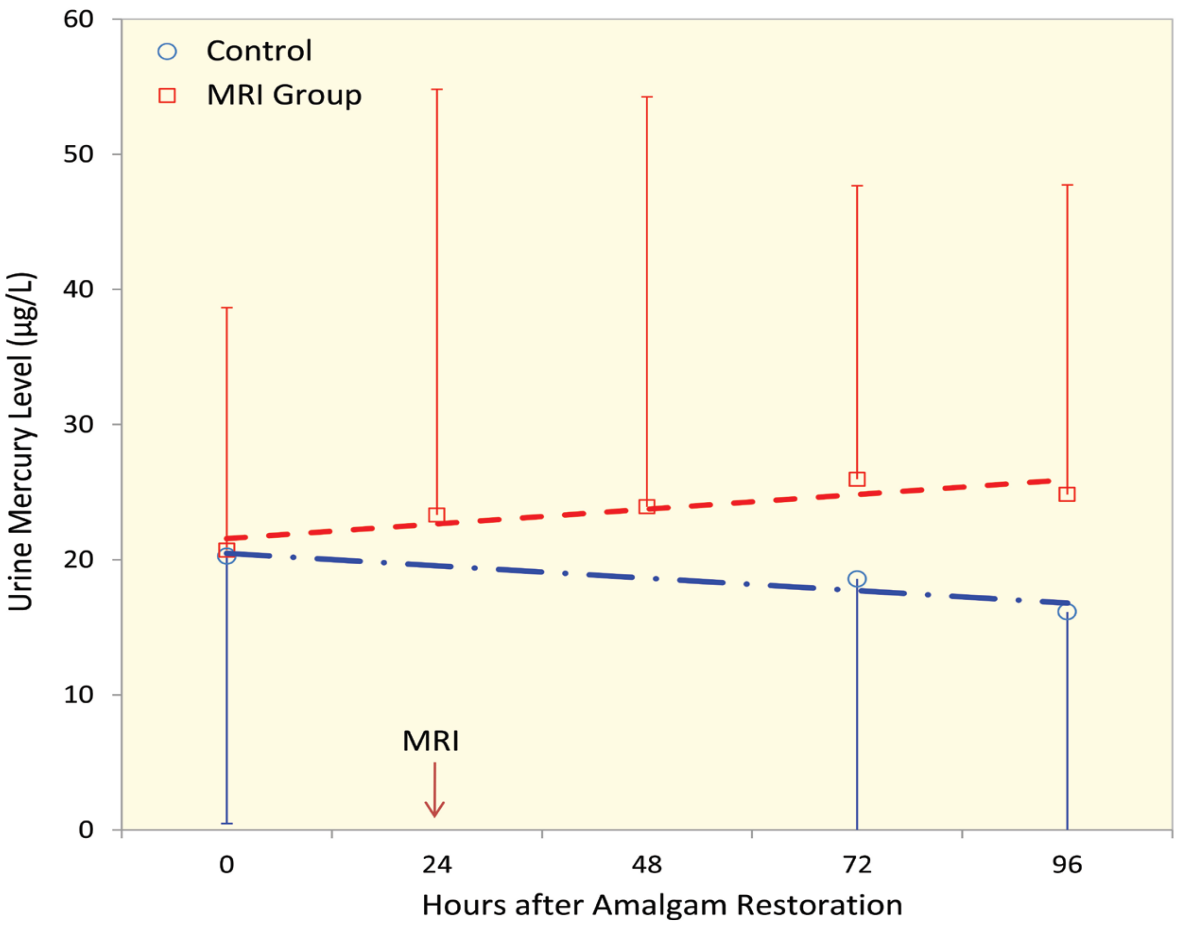

Figure 1:

METHODOLOGY:

The members of this review remained nominated by the screening program for understudies who need dental claims. They alluded to the dental specialist for assessment of oral well-being. Based on the incorporation measures, 18 solids we've discovered understudies qualified to participate in this investigation. Our current research was conducted at Islamic International Dental Hospital from March 2018 to February 2019. The purpose of this review was to investigate the impact of high field MRI on mercury releases from dental amalgam fillings. Authors considered two gatherings of liners with dental decay requiring a comparable example of

restorative dentistry. The size of the example was determined in light of information from one of our past lives. studies. Initially, two coordinated gatherings, each comprising of eight people (three men and five ladies), were formed; then the gatherings were randomly assigned to the two controls or on the other hand, arms not covered by MRI. After approval by the Medical Ethics Committee of Shiraz University of Medical Sciences and obtain informed consent consisting of members, inseparable dental amalgam Claims have been made for all members. Mercury levels were estimated in urine testing of control members before amalgam recovery (hour 0), and 3 days and 4 days after reconstruction. Members of the Discovery Assembly has experienced MRI of the ordinary mind (98 in 16 min) by means of the 1.6 T GE scanner 24 hours after amalgam reconstruction. Urinary the level of mercury in people not covered was resolved before the amalgam reconstruction (hour 0), and 2, 3, 4 and 5 days after amalgam reconstruction, the course of time during the level of urinary mercury in subjects who have experienced assistance dental procedures, normally amounted to gauge levels. Mercury concentrates in tests were estimated by cold fumes nuclear ingestion spectrophotometry.

Statistical Analysis:

SPSS® for Windows® ver 18.0 was used to the information survey. Mann-Whitney's U-test remained utilized to examine the level of urinary mercury in two rallies planned. An estimate <0.06 was considered to be measurably critical.

RESULTS:

The average ± SD time of the members of the control and study was 25.6±5.3 also, 26.7±4.8 years, separately (p=0.68). Figure 1 displays pattern of urinary mercury in two rallies under consideration. The site mean±SD of previous urinary mercury levels the recovery of amalgam for investigation, and remained 21.71±18.97, and 21.26±21.78 µg/L, individually (p=0.86) ; 72 hours after amalgam recovery (48 hours from MRI), the level of mercury in the survey also, the control clusters were 26.96±22.73, and 19.58±18.05 µg/L, individually (p=0.039). Later, 96 hours of amalgam recovery (72 hours afterwards MRI), level of mercury in MRI set remained still essentially (p=0.047) greater than that of control of the collection (p=0.047).

DISCUSSION:

In our investigation, while here remained not any contrast among standard urine mercury content of examination and monitoring from MRI, from 3 days after MRI, mercury in people with an enlarged MRI at levels substantially above these in reference set [6]. Those results affirmed outcomes we have achieved in our past 16 and has shown that MRI can rise essentially the arrival of mercury dental amalgam fillings where necessary within 3 days of the methodology. In another research led by Müller-Miny, and al, they inspected mercury issue for the average MRI conventions, isolated for two static and variable attractive fields in a 1.6 T MRI unit [7]. They were unable to illustrate any significant mercury increases of discharge because of the MRI. The explanation of principle behind the inconsistencies found among henceforth the consequences of our investigations and those detailed by Müller-Miny, et al, could be credited the in vitro nature of their test. This would be distinguished that salivation is a large electrolyte and may rise the discharge of mercury from dental amalgam to the acceptance of galvanic flux. Amalgam Fills can also create [8]. Hating the way mercury is a well-known substance, the risk to well-being, while this introduction to try to reduce the content of this overwhelming metal a have been associated with subclinical side effects of intoxication, no. There is agreement among reviewers on measurement of mercury released from dental devices amalgam that under typical conditions, would cause a toxic reaction in humans. While some specialists accept that there is no hard evidence while dental amalgam is detrimental to the well-being in mainstream of population impacts of dental amalgam on the counting pregnant females, small children and children with disabilities [9]. offspring, elderly and people who are particularly vulnerable to the effects of delicate to mercury, can be extraordinary. It would be all the more confusing if these individuals are presented to X-ray within 2 days of receipt dental amalgam fillings, as we've seen [10].

CONCLUSION:

Think about the importance of the issue, further tests are needed to explain regardless of the fact that other basic sources of EMF introduction may also cause changes to the and accelerate the arrival of mercury, and to examine whether these the improvement in discards is of neurotic importance, especially among the vulnerable people.

REFERENCES:

1. K.A. Willets, R.P. Van Duyne**Localized surface plasmon resonance spectroscopy and sensing** Annu. Rev. Phys. Chem., 58 (2007), pp. 267-297
2. Y. Zhuang, L. Liu, X. Wu, Y. Tian, X. Zhou, S . Xu, Z. Xie, Y. Ma**Size and shape effect of gold nanoparticles in "far-field" surface plasmon resonance** Part. Part. Syst. Charact., 36 (2019), Article 1800077
3. Y. Wu, M.R. Ali, K. Chen, N. Fang, M.A. El-Sayed**Gold nanoparticles in biological optical imaging** Nano Today, 24 (2019), pp. 120-140

4. K. Pathakoti, M. Manubolu, H.-M. Hwang**Nanostructures: current uses and future applications in food science** J. Food Drug Anal., 25 (2017), pp. 245-253
5. M.-C. Daniel, D. Astruc**Gold nanoparticles: assembly, supramolecular chemistry, quantum-size-related properties, and applications toward biology, catalysis, and nanotechnology** Chem. Rev., 104 (2004), pp. 293-346
6. Y. Hernández, B.C. Galarreta**Noble metal-based plasmonic nanoparticles for SERS imaging and photothermal therapy** Nanomaterials for Magnetic and Optical Hyperthermia Applications, Elsevier (2019), pp. 83-109
7. W. Zhao, M.A. Brook, Y. Li**Design of gold nanoparticle-based colorimetric biosensing assays** ChemBioChem, 9 (2008), pp. 2363-2371
8. D.D. Gurav, Y.A. Jia, J. Ye, K. Qian**Design of plasmonic nanomaterials for diagnostic spectrometry** Nanoscale Adv., 1 (2019), pp. 459-469
9. K.L. Kelly, E. Coronado, L.L. Zhao, G.C. Schatz**The Optical Properties of Metal Nanoparticles: the Influence of Size, Shape, and Dielectric Environment** ACS Publications (2003)
10. J. Pérez-Juste, I. Pastoriza-Santos, L.M. Liz-Marzán, P. Mulvaney**Gold nanorods: synthesis, characterization and applications** Coord. Chem. Rev., 249 (2005), pp. 1870-1901