



CODEN [USA]: IAJ PBB

ISSN: 2349-7750

**INDO AMERICAN JOURNAL OF  
PHARMACEUTICAL SCIENCES**<http://doi.org/10.5281/zenodo.3579097>Available online at: <http://www.iajps.com>

Research Article

**ANALYSIS OF DIAGNOSTIC ACCURACY OF  
ULTRASOUND (USG) IN PRENATAL DIAGNOSIS OF  
PLACENTA ACCRETA TAKING OPERATIVE FINDINGS AS  
GOLD STANDARDS**Hira Dastgir<sup>1</sup>, Aqsa Pervaiz<sup>2</sup>, Hafiza Ayesha Qudsia<sup>3</sup><sup>1</sup>District Headquarter Hospital, Gujranwala<sup>2</sup>Allama Iqbal Memorial Teaching Hospital, Sialkot<sup>3</sup>District Headquarter Hospital, Narowal**Abstract:**

**Introduction:** Morbidly adherent placenta (MAP) is defined as abnormal placental adherence, either in whole or in part of the placenta to the underlying uterine wall. **Aims and objectives:** The basic aim of the study is to analyze the diagnostic accuracy of ultrasound (USG) in prenatal diagnosis of placenta accreta taking operative findings as gold standards. **Material and methods:** This descriptive study was conducted in Allama Iqbal Memorial Teaching Hospital, Sialkot during May 2018 to September 2019. The data was collected from 50 patients of placenta accrete and we take operative findings as a gold standards. All those patients were at a high risk of abnormal placentation (placenta accrete, increta and percreta) regarding their clinical history of either one or all of the following: placenta previa, previous uterine interventional procedures (e.g. cesarean sections, dilation & curettage and myomectomy, maternal age of 35 years or more and grand multiparity. **Results:** The data was collected from 50 patients. The mean age of the patients was  $34.56 \pm 4.56$  years. In our study HB-difference (HB-dC) between pre- and post-operative values and estimated blood loss were the most significant risks factors for abnormal placentation added to risk factors known for placenta accrete. Postpartum SICU admission, prolonged hospital stay and CS hysterectomy were more common in the cases of placenta accreta associated with abnormal placentation. However, they were statistically insignificant. **Conclusion:** It is concluded that doppler ultrasound is useful in detecting placenta accreta in patients with placenta previa. Doppler ultrasound fairly good diagnostic accuracy for diagnosis placenta accreta.

**Corresponding author:**

Hira Dastgir,

District Headquarter Hospital, Gujranwala

QR code



Please cite this article in press Hira Dastgir et al., *Analysis Of Diagnostic Accuracy Of Ultrasound (USG) In Prenatal Diagnosis Of Placenta Accreta Taking Operative Findings As Gold Standards.*, Indo Am. J. P. Sci, 2019; 06(12).

**INTRODUCTION:**

Morbidly adherent placenta (MAP) is defined as abnormal placental adherence, either in whole or in part of the placenta to the underlying uterine wall. Morbid adherent placenta is a rare complication of placentation but has life and fertility threatening complications and includes placenta accreta, percreta and increta. It is found to be the third most frequent indication for emergency obstetrical hysterectomy next to uterine rupture and atony in Pakistan [1]. Placenta accreta is a pathological condition in which the placental trophoblast invades the endometrium beyond the Nitabuch's layer due to a defect in the decidua basalis.

In more severe cases, the trophoblast invades the myometrium (placenta increta) or the serosa and beyond (placenta percreta) [2]. In a series of studies by Miller *et al.* including 62 pathologically confirmed cases of abnormal placentation, 76% were accreta, 18% were increta, and 6% were percreta. The major morbidity associated with such an abnormal placentation primarily arises from a significant blood loss that occurs at the time of delivery, requiring longer maternal hospital stay and blood transfusion [3]. In addition, pregnancies complicated by placenta accreta are thought to be associated with increased incidence of cystotomy, ureteral injury, pulmonary embolism, need for ventilator use, reoperation, and intensive care unit (ICU) admission.

Risk factors for placenta accreta include prior cesarean section (CS) delivery, uterine instrumentation and intrauterine scarring, all of which may be associated with damage to or absence of the decidua basalis [4]. Another important factors are placenta previa, smoking, maternal age over 35 years, grand multiparity and recurrent miscarriage. Given the continual increase in CS deliveries worldwide, the relationship between prior uterine surgery and the risk of placenta previa and accreta is gaining on importance. It has been noted that one prior CS delivery doubles the risk of placenta previa in a subsequent pregnancy and those women are particularly at risk for placenta accreta [5].

**Theoretical background of the study**

Abnormal placental adherence to/or invasion into the myometrium prevents normal separation of the placenta at the time of delivery, potentially resulting in life-threatening uterine hemorrhage or retained

products of conception. Given the significant morbidity associated with this diagnosis, the ability to accurately diagnose placenta accreta is essential as it allows both the patient and the obstetrician to be prepared for potential complications of delivery and to proceed with antenatal care to minimize blood loss during and after delivery. Because ultrasonography (US) is relatively inexpensive and widely available, it remains the primary diagnostic tool for abnormal placentation, together with fetal screening examinations [6].

**Aims and objectives**

The basic aim of the study is to analyze the diagnostic accuracy of ultrasound (USG) in prenatal diagnosis of placenta accreta taking operative findings as gold standards.

**MATERIAL AND METHODS:**

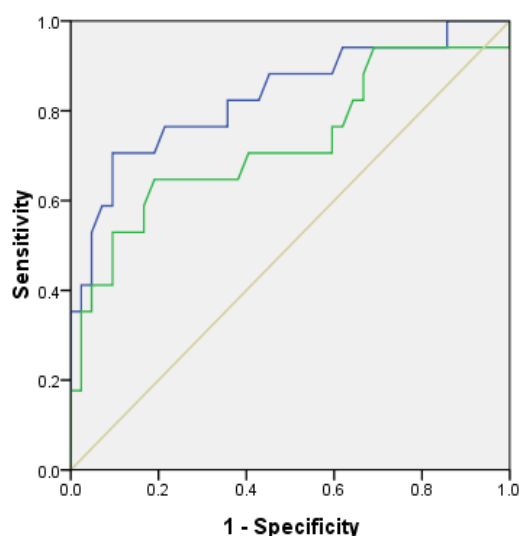
This descriptive study was conducted in Allama Iqbal Memorial Teaching Hospital, Sialkot during May 2018 to September 2019. The data was collected from 50 patients of placenta accrete and we take operative findings as a gold standards. All those patients were at a high risk of abnormal placentation (placenta accrete, increta and percreta) regarding their clinical history of either one or all of the following: placenta previa, previous uterine interventional procedures (e.g. cesarean sections, dilation & curettage and myomectomy, maternal age of 35 years or more and grand multiparity. All these patients were followed till delivery. Their surgical findings for evidence of morbidly adherent placenta (accreta, increta, percreta) were noticed and compared with Doppler ultrasound report. All US gray-scale and Doppler studies were performed by registered sonographers and interpreted by an accompanied radiologist.

**RESULTS:**

The data was collected from 50 patients. The mean age of the patients was  $34.56 \pm 4.56$  years. In our study HB-difference (HB-dC) between pre- and post-operative values and estimated blood loss were the most significant risks factors for abnormal placentation added to risk factors known for placenta accrete. Postpartum SICU admission, prolonged hospital stay and CS hysterectomy were more common in the cases of placenta accreta associated with abnormal placentation. However, they were statistically insignificant.

**Table 01:** Ultrasound signs of abnormal placentation in patients with placenta accreta

Ultrasound signs of abnormal placentation	Number of positive cases	% from positive cases	Number of negative cases	% from negative cases
1 – Placental lacunae with turbulent flow	28/34	82%	16/66	24%
2 – Thinned myometrial zone below 1 mm or loss of visualization	32/34	94%	33/66	50%
3 – Loss of retroplacental clear space	20/34	58%	30/66	45%
4 – Gap in the retroplacental blood flow	16/34	47%	12/66	18%
5 – Abnormal Color Doppler Imaging patterns in the form of disruption and increased color Doppler flow at placenta myometrium interface	30/34	88%	10/66	15%

**Figure 01:** ROC curve of sensitivity and specificity**DISCUSSION:**

In our analysis HB-difference (HB-dC) between pre- and post-operative values and estimated blood loss were the most significant risks factors for abnormal placentation added to risk factors known for placenta accrete. Morbidly adherent placenta with its variants is one of the most feared complications causing high morbidity and mortality in obstetrics. Pelvic ultrasonography has been the most commonly used imaging modality for the diagnosed of MAP. Levine et al showed the same results as Levine and the coworkers reported their experience with 19 women at risk of whom seven had MAP [7].

In our study ultrasonography accurately identified six of the seven women and correctly identified normal placentation in 11 of 12 cases. Chou et al followed 80 women prospectively and of 16 considered to have ultrasound findings consistent with MAP, 14 had tissue evidence confirming the diagnosis of the remaining 64 studies interpreted as negative, placenta was adherent in three and the remainder was accurately diagnosed, resulting in a sensitivity of 82% and specificity of 96.8%.the

findings of these two studies suggest that ultrasonography has a primary role in screening women at risk of MAP [7].

Three recently published systematic review have shown the diagnostic accuracy of ultrasound for the diagnosis of invasive placentation, the use of MRI22 and a comparison of ultrasound and MRI and it shows the same results as our study shows. Antonio et al published meta-analyses for diagnosis of invasive placentation with sensitivity of 90.7% and specificity of 96.9% for ultrasound and sensitivity of 94.4% and specificity of 84% for MRI [8]. Meng et al showed that ultrasound sensitivity was 83%, its specificity was 95% and diagnostic odds ratio(DOR) was compared with 82% , 88% and 22.9% respectively, for MRI. These meta-analyses showed good accuracy of ultrasound and MRI in the diagnosis of invasive placentation [9]. Color Doppler ultrasound imaging is popular because it is cheap, readily available, easily accessible and widely used for the screening of placenta location and placental abnormalities. Color Doppler ultrasound has high sensitivity and specificity for

diagnosis of morbidly adherent placenta especially when specific defined criteria are used for the diagnosis [10]. However, the results of the study in support with other studies reveal that diagnostic accuracy of color Doppler ultrasound in antenatal diagnosis of morbidly adherent placenta in gravid females having placenta previa is significantly higher and this modality may be used further for in-time management [11]

### CONCLUSION:

It is concluded that doppler ultrasound is useful in detecting placenta accreta in patients with placenta previa. Doppler ultrasound fairly good diagnostic accuracy for diagnosis placenta accreta.

### REFERENCES:

1. Comstock CH, Love JJ, Bronsteen RA, et al. Sonographic detection of placenta accreta in the second and third trimesters of pregnancy. *Am J Obstet Gynecol.* 2004;190:1135–40.
2. Finberg HJ, Williams JW. Placenta accreta: prospective sonographic diagnosis in patients with placenta previa and prior cesarean section. *J Ultrasound Med.* 1992;11:333–43.
3. McGahan JP, Phillips HE, Reid MH. The anechoic retroplacental area: a pitfall in diagnosis of placental – endometrial abnormalities during pregnancy. *Radiology.* 1980;134:475–78.
4. Wong HS, Cheung YK, Zuccollo J, et al. Evaluation of sonographic diagnostic criteria for placenta accreta. *J Clin Ultrasound.* 2008;36:551–59.
5. Belfort MA Publications Committee, Society for Maternal-Fetal Medicine. Placenta accreta. *Am J Obstet Gynecol.* 2010;203:430–39.
6. 14. Palacios Jaraquemada JM, Bruno CH. Magnetic resonance imaging in 300 cases of placenta accreta: surgical correlation of new findings. *Acta Obstet Gynecol Scand.* 2005;84:716–24. [PubMed] [Google Scholar]
7. Warshak CR, Eskander R, Hull AD, et al. Accuracy of ultrasonography and magnetic resonance imaging in the diagnosis of placenta accreta. *Obstet Gynecol.* 2006;108:573–81.
8. Lam G, Kuller J, McMahon M. Use of magnetic resonance imaging and ultrasound in the antenatal diagnosis of placenta accreta. *J Soc Gynecol Investig.* 2002;9:37–40.
9. Dwyer BK, Belogolovkin V, Tran L, et al. Prenatal diagnosis of placenta accreta: sonography or magnetic resonance imaging? *J Ultrasound Med.* 2008;27:1275–81.
10. Masselli G, Brunelli R, Casciani E, et al. Magnetic resonance imaging in the evaluation of placental adhesive disorders: correlation with color Doppler ultrasound. *Eur Radiol.* 2008;18:1292–99.
11. Kkanal E, Barkoich AJ, Bell C, et al. ACR guidance document for safe MR practices: 2007. ACR blue ribbon panel on MR Safety. *Am J Roentgenol.* 2007;188:1447–74.
12. Elsayes KM, Trout AT, Friedkin AM, et al. Imaging of the placenta: a multimodality pictorial review. *Radiographics.* 2009;29:1371–91.
13. Baughman WC, Corteville JE, Shah RR. Placenta Accreta: Spectrum of US and MR Imaging Findings. *Radiographics.* 2008;28:1905–16.
14. Comstock CH, Lee W, Vettraino IM, et al. The Early Sonographic Appearance of Placenta Accreta. *J Ultrasound Med.* 2003;22:19–23.