CODEN [USA]: IAJPBB ISSN : 2349-7750

INDO AMERICAN JOURNAL OF
PHARMACEUTICAL SCIENCES
SJIF Impact Factor: 7.187
http://doi.org/10.5281/zenodo.4314144

Avalable online at: http://www.iajps.com *Research Article*

COMPLICATIONS AND MANAGEMENT OF THYROIDECTOMY IN SUBSTERNAL GOITRE

[1]Dr Hafiz Muhammad Shafique ur Rehman, [2]Dr Saira Naseer, [3]Dr Nimra Mir

[1]Multan Medical & Dental College, [2]Fatima Jinnah Medical University, Lahore, [3]Fatima Jinnah Medical University, Lahore.

Article Received: October 2020 **Accepted:** November 2020 **Published:** December 2020

Abstract:

Aim: *To assess the need and complications of thyroidectomy in a Substernal goiter.*

Study design: *descriptive retrospective study.*

Place and Duration: *Ear, Nose and Throat, Head and Neck Surgery Department of Nishtar Hospital Multan for one-year duration from March 2019 to March 2020.*

Patients and Methods: *Seventeen patients with Substernal goiter, both sexes and different ages, who underwent thyroidectomy were examined for indications and complications after thyroidectomy.*

Results: *Only one patient (5.88%) experienced acute airway obstruction. Three (17.65%) patients complained of dyspnea in the supine position, dysphagia and hoarseness were found in two (11.76%) patients, and eleven (64.71%) patients had no apparent neck swelling. In fourteen cases (82.35%) total thyroidectomy was performed, and in three (17.65%) lobectomy with isthmectomy was performed. CT was performed in twelve (70.59%) of these cases. Most of our cases, ie sixteen (94.12%) were benign, while cancer occurred in only one (5.88%) patient. Complications such as hematoma in one (5.88%) patient, recurrent damage to the laryngeal nerve in two (11.76%), hypoparathyroidism (transient) in two (11.76%), and wound infection in one (5.88 %) patient. There was no pre- or postoperative mortality, none of them had permanent hypoparathyroidism, but one (5.88%) of our patient had unilateral recurrent pharyngeal trauma.*

Conclusion: *Sub-sternal goiter is often asymptomatic and thyroidectomy is the treatment of choice with very low mortality and morbidity.*

Key words: *Substernal goiter, total thyroidectomy, recurrent damage to the laryngeal nerve*

Corresponding author:

Dr. Hafiz Muhammad Shafique ur Rehman,

Multan Medical & Dental College.

QR code

Please cite this article in press Hafiz Muhammad Shafique ur Rehman et al, ***Complications And Management Of Thyroidectomy In Substernal Goitre.,*** *Indo Am. J. P. Sci, 2020; 07(12).*

INTRODUCTION:

When the thyroid gland has widened into the mediastinum, it is called a Substernal goiter. Lengthening of the goiter is commonly seen in the anterior mediastinum, while the posterior mediastinum is a rare site. The goiter under the sternum is actually the mass of the thyroid gland that extends beyond the upper thoracic inlet by at least 3 cm, maintaining the connection between the cervical and thoracic sections and maintaining the vascularization provided by the thoracic arteries. Almost 5% of the thyroid goiter descends to the area under the sternum, and only 5% of all medial-sternal masses are thyroid goiters.

Cerebral lengthening of the goiter may compress some mediastinal structures, such as the trachea, esophagus or superior vena cava.

Compression on the trachea and severe respiratory impairment are the most common symptoms occurring in 45% of cases of sub-sternal extension of the goiter, and it is one of the urgent indications for thyroidectomy under the sternum. Dyspnoea and choking are common symptoms and computed tomography is an important pre-operative examination in terms of length, size and planning of the operation. The severity of pressure symptoms and the potential risk of post-operative complications are usually associated with a large goiter under the sternum. Transcervical access is the most common incision to excise most of the goiter under the sternum, while a sternal incision is needed in a few cases without significant morbidity or mortality.

There are various factors, such as the size, location and depth of the goiter under the sternum, that may require sternotomy, culminating in postoperative complications. Acute airway obstruction and a malignant tumor may be seen in the gradually enlarging goitre under the skin. Therefore, surgery is the method of treatment recommended for all cases, regardless of symptoms, as long as there are no contraindications.

PATIENTS AND METHODS:

The study was conducted in the Ear, Nose and Throat, Head and Neck Surgery Department of Nishtar Hospital Multan for one-year duration from March 2019 to March 2020. In this study, all of our 17 patients had a goiter that extended to the thoracic opening, ie the fourth thoracic vertebra. Our study included patients of both sexes and aged 39 to 71 years. Of the 17 patients, 13 are female and only 04 are male. Pre-operative standard evaluation protocol including clinical history including clinical examination of the ear, nose, and throat, and the head and neck region. Each patient underwent complete blood count, urea, proportions, creatinine, electrolytes, thyroid profile, thyroid examination, ultrasound, chest X-ray, lateral neck X-ray and urinalysis. All patients have pre-operative evaluation and recording of vocal cord movements using flexible fiber optic laryngoscopy, which is repeated postoperatively in the event of any voice change. FNAC was performed in 07 cases. Lung function tests were performed in only one case of acute airway obstruction. In 12 cases, computed tomography was performed to find out the extent of the goiter and the degree of compression and deviation of the trachea. All our cases were euthyroid.

All of them obtained informed consent to perform a sternotomy if needed. Under general anesthesia, all patients were supine with the neck stretched, this area exposed from the chin to the nipple line. In all cases, cervical or cervical cleavage was preferred, and the belt muscles were cut as required to improve accessibility. The thyroid gland was mobilized by capsular dissection with careful ligation of the upper thyroid vessels, middle thyroid vein and lower thyroid vessels. The sub-sternal portion of the thyroid gland was manually withdrawn and delivered to the cervical region, with the diagnosis of a recurrent laryngeal nerve in most cases.

In all patients, the sternal part of the goiter was successfully performed and no sternotomy was required in any case. Blood loss during surgery was minimal and only one patient needed a transfusion. In total thyroidectomy, two and one suction drains were inserted for several days in cases of partial thyroidectomy, the wound was closed in layers. After surgery, all cases were followed for 5 months.

RESULTS:

Thyroidectomy was performed in 17 patients with goiter under the sternum. Six of the 17 patients had symptoms, 11 of which were asymptomatic instead of obvious neck swelling. Dyspnea was the dominant symptom in 3 (17.65%) patients, stridor and acute airway obstruction in 1 (5.88%) case, dysphagia and hoarseness were observed in only 2 (11.76%) patients.

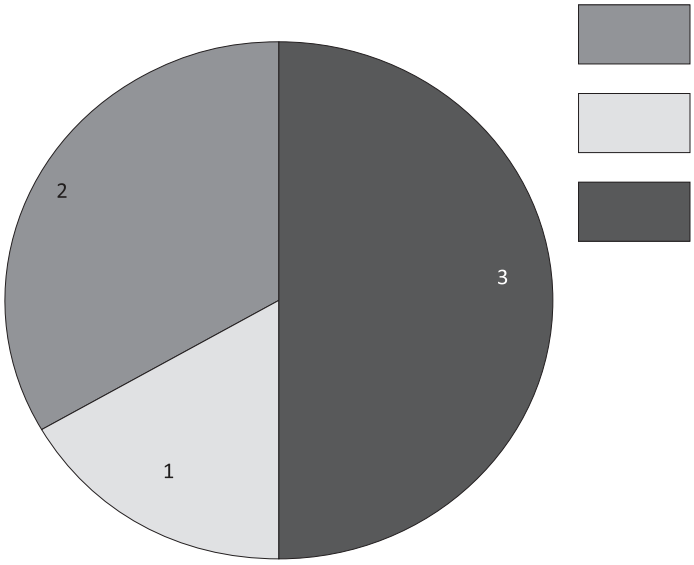

Figure 1: ***Symptoms***

Table 1: ***Clinical Presentation***

Presentation	No. of patients	Percentage
Acute Airway Obstruction Strider	01	05.88%
Dyspnea	03	17.65%
Dysphagia & Hoarseness	02	11.76%

Table 2: ***Histology of Substernal goiter***

Histopathology of the goiter	No. Of patients	Percentage
Nodular Hyperplasia	16	94.12%
Follicular Carcinoma	01	05.88%

Table 3: ***Complications***

Complications	No. of Patients	Percentage
Hematoma	01	05.88%
(Transient) Recurrent Laryngeal nerve palsy	02	11.76%
(Transient) Hypoparathyroidism	02	11.76%
Wound infection	01	05.88%
Permanent recurrent laryngeal nerve palsy	01	05.88%

In most of the 6 symptomatic cases the duration of the symptoms ranged from 5 to 55 months. One patient in our study presented with severe stridor for acute airway obstruction and was treated with emergency

endotracheal intubation followed by thyroidectomy. Euthyroidism was found in all our cases. Cervical incision was found to be appropriate in our thyroidectomy series, while a sternotomy was never required in any of them. Total thyroidectomy was performed in 14 (82.35%) cases, and lobectomy and isthmectomy were performed in only 3 (17.65%) patients.

Most of our patients recovered without any adverse effects, and the postoperative hospital stay lasted from 2 to 12 days. Histopathology showed benign nodular hyperplasia in 16 (94.12%) patients, while malignant neoplasm, ie follicular cancer, was only observed in 1 (5.88%) patient. Complications encountered in our series in the postoperative period have been reported. Postoperative hematoma was found in 1 (5.88%), recurrent laryngeal nerve paralysis (transient) in 2 (11.76%) patients, transient hypoparathyroidism was observed in 2 (11.76%), wound infection was found in 1 (5, 88%). Patient 1 (5.88%) of a follicular cancer patient developed persistent recurrent paralysis of the laryngeal nerve.

DISCUSSION:

When the enlarged thyroid gland extended to the chest, it is considered a goiter under the breastbone or in the chest. According to many authors, when more than 50% of the mass of the thyroid gland is below the plane of the first rib9, symptomatic or asymptomatic, it is called under the sternum, which can also cause surgical problems.10 In our study, all the masses were in the chest inlet.

Due to the progressive nature of the symptoms of compression and the nature of pathological surgery, they remain the main treatment option for retrosternal goiter.8 Pre-operative CT is the main imaging test to assess the extent of the goiter. Despite neck swelling and sternum extension, asymptomatic symptoms were found in 11 out of 17 patients in our study. In 06 symptomatic 03 patient's dyspnea, dysphagia and hoarseness were observed in 02 cases, only one of them experienced acute airway obstruction treated by emergency tracheal intubation and after thyroidectomy. Similar symptoms have been mentioned in many retrospective studies. In asymptomatic patients, postoperative complications were relatively smaller, which was also shown in the previous study. In our series, tracheal collapse was not found in the postoperative phase, but was observed more often in large and long goiters under the sternum. According to the literature review, the incidence of malignant neoplasms in the goiter under the sternum ranges from 03 to 19%, while in our series only 1 (%) of patients have follicular thyroid cancer. Transcervical access was sufficient to excise all thyroid tumors in our study, and sternotomy was not required in any of them, while this approach is necessary for large mediastinal goiters with malignant neoplasms requiring removal of mediastinal lymph nodes or with mediastinal vascularization. We did not notice any complications during thyroidectomy, and we were also supported by retrospective literature searches with a slightly different rate. No mortality or permanent hypoparathyroidism was reported in this study. Goiter under the sternum is a definite indication for thyroidectomy due to progressive enlargement, frequent risk of airway compression, dysphagia, hoarseness, tendency to malignant neoplasms in long-term cases and very low morbidity after thyroidectomy.

CONCLUSION:

Due to the potential risk of airway obstruction and malignancies, goiter under the sternum should always be treated with early thyroidectomy.

REFERENCES:

1. Doulaptsi, Maria, Alexandros Karatzanis, Emmanuel Prokopakis, Stylianos Velegrakis, Alexia Loutsidi, Athina Trachalaki, and George Velegrakis. "Substernal goiter: Treatment and challenges. Twenty-two years of experience in diagnosis and management of substernal goiters." *Auris Nasus Larynx* 46, no. 2 (2019): 246-251.
2. Hanson, Martin A., Ashok R. Shaha, and James X. Wu. "Surgical approach to the substernal goiter." *Best Practice & Research Clinical Endocrinology & Metabolism* 33, no. 4 (2019): 101312.
3. Wong, Wai Keat, Subhaschandra Shetty, Randall P. Morton, Nicholas P. McIvor, and Tony Zheng. "Management of retrosternal goiter: Retrospective study of 72 patients at two secondary care centers." *Auris Nasus Larynx* 46, no. 1 (2019): 129-134.
4. Papanastasiou, Anastasios, Konstantinos Sapalidis, Stylianos Mantalobas, Stefanos Atmatzidis, Nikolaos Michalopoulos, Valeriu Surlin, Athanasios Katsaounis et al. "Design of a predictive score to assess the risk of developing hypocalcemia after total thyroidectomy. A retrospective study." *International Journal of General Medicine* 12 (2019): 187.
5. Menon, Gokuldas, Pawan Kumar, Ahlam Abdul Rahman, Shalini M. Nair, Mathew George, and Eldo Issac. "Anesthetic management of total thyroidectomy and partial sternotomy for a case

of retrosternal goiter." *Amrita Journal of Medicine* 16, no. 3 (2020): 138.

6. Abdelrahman, Husham, Hassan Al-Thani, Maryam Al-Sulaiti, Abdelhakem Tabeb, and Ayman El-Menyar. "Clinical Presentation and Surgical Treatment of Retrosternal Goiter: A Case Series Study." *Qatar Medical Journal* 2020, no. 1 (2020): 13.
7. Feng, Allen L., Sidharth V. Puram, Michael C. Singer, Rahul Modi, Dipti Kamani, and Gregory W. Randolph. "Increased prevalence of neural monitoring during thyroidectomy: Global surgical survey." *The Laryngoscope* 130, no. 4 (2020): 1097-1104.
8. Finnerty, Brendan M., Katherine D. Gray, Timothy M. Ullmann, Rasa Zarnegar, Thomas J. Fahey, and Toni Beninato. "Frailty is More Predictive than Age for Complications After Thyroidectomy for Multinodular Goiter." *World Journal of Surgery* (2020): 1-9.
9. Li, Wei, Huisheng Li, Shanling Zhang, Yingjie Tao, Xudong Wang, and Junping Cheng. "To explore the risk factors and preventive measures affecting the treatment of retrosternal goiter: An observational study." *Medicine* 99, no. 44 (2020).
10. Aspinall, S., D. Oweis, and D. Chadwick. "Effect of surgeons' annual operative volume on the risk of permanent Hypoparathyroidism, recurrent laryngeal nerve palsy and Haematoma following thyroidectomy: analysis of United Kingdom registry of endocrine and thyroid surgery (UKRETS)." *Langenbeck's archives of surgery* 404, no. 4 (2019): 421-430.
11. Kleid, Stephen. "Techniques, considerations and outcomes for surgical treatment of retrosternal goiter." *Open Access Surgery* 12 (2019): 13.
12. Wang, Xu, Yuqiu Zhou, Chao Li, Yongcong Cai, Tianqi He, Ronghao Sun, Wen Tian et al. "Surgery for retrosternal goiter: cervical approach." *Gland Surgery* 9, no. 2 (2020): 392.
13. Fernandez-Ranvier, Gustavo, Aryan Meknat, Daniela E. Guevara, and William B. Inabnet III. "Transoral Endoscopic Thyroidectomy Vestibular Approach." *JSLS: Journal of the Society of Laparoendoscopic Surgeons* 23, no. 4 (2019).
14. Simó, Ricard, Iain J. Nixon, Vincent Vander Poorten, Miquel Quer, Ashok R. Shaha, Alvaro Sanabria, Fernando Lopez Alvarez, Peter Angelos, Alessandra Rinaldo, and Alfio Ferlito. "Surgical management of intrathoracic goitres." *European Archives of Oto-Rhino-Laryngology* 276, no. 2 (2019): 305-314.
15. Bhettani, Mehreen K., Mubarik Rehman, Muhammad S. Khan, Humera N. Altaf, Kamran Hakeem Khan, Fareeha Farooqui, Mohammad Amir, and Omar S. Altaf. "Safety and Cost-effectiveness of LigaSure® in Total Thyroidectomy in Comparison with Conventional Suture Tie Technique." *Cureus* 11, no. 12 (2019).