CODEN [USA]: IAJPBB ISSN : 2349-7750

INDO AMERICAN JOURNAL OF
PHARMACEUTICAL SCIENCES
SJIF Impact Factor: 7.187
http://doi.org/10.5281/zenodo.4314290

Avalable online at: http://www.iajps.com *Research Article*

MAGNITUDE OF SAFETY WHILE CONDUCTING PNEUMATIC DILATATION OF PRIMARY ACHALASIA CARDIA WITHOUT CONSCIOUS SEDATION

[1]Dr Sofia Sandal, [1]Dr Sheharyar Hassan Khan, [2] Dr Areeba Riasat Nahra
[1]Mayo Hospital Lahore, [2]University of Lahore.

Article Received: October 2020 **Accepted:** November 2020 **Published:** December 2020

Abstract:
Objective: *The objective of this prospective research is to examine the magnitude of efficacy and safety while conducting pneumatic dilatation of PAC (Primary Achalasia Cardia) without the provision of conscious sedation and also to assess endoscopic signs of "balloon waist" effacement. The said process is trended giving conscious sedation in the presence of endoscopic (ante-grade) guidance.*
Methodology: *The prospective research was performed successfully on subject size of 23 patients with the mean age of (40.54) years. Conscious sedation was not given while conducting diagnosis of radiologic and endoscopic Primary Achalasia Cardia.*
Results: *Symptoms were immediately removed in 90% (21) patients when observed with balloon 'waist' effacement when observed through endoscopic vision. All the patients experienced chest pain and only 66% (15) patients were observed with mild bleeding. 6% (2) cases required dilatation again. Follow-up was scheduled from 6 weeks to 23 months.*
Conclusions: *It is very safe performing pneumatic dilatation of Primary Achalasia Cardia with no conscious sedation. Effacement of the 'waist' of the balloon can be observed by EASL (Endoscopic Assessment of stretch on the lower oesophageal Sphincter) ante-grade.*
Keywords: *Pneumatic Dilatation, Conscious Sedation, Lower Oesophageal Sphincter, Oesophageal Sphincter, Upper Gastrointestinal Endoscopy.*

Corresponding author:
Dr. Sofia Sandal,
Mayo Hospital Lahore.

QR code

Please cite this article in press Sofia Sandal et al, ***Magnitude Of Safety While Conducting Pneumatic Dilatation Of Primary Achalasia Cardia Without Conscious Sedation.,*** *Indo Am. J. P. Sci, 2020; 07(12).*

INTRODUCTION:

Reports call PAC as a case with dysphagia to be uncommon in patients outdoor. Among non-classic and early cases, barium study and one gastrointestinal endoscopy (upper) is considered normal. Treatment with endoscopy has proved to have fruitful outcomes in Primary Achalasia Cardia. Pneumatic Dilatation and Botox (botulinum toxin) injection in LES are widely preferred and used to myotomy (surgical) [1]. The use of indigenous balloons (modified) has proved to be successful. Up till now, fluoroscopic guidance was used for carrying out Pneumatic Dilatation but considering less radiation exposure and convenience, endoscopic guidance is adopted widely. However, the results of using endoscopic guidance depends on many factors. The latest therapeutic techniques may be initiated with transluminal surgery through clinical application. Our study proves Pneumatic Dilatation of Primary Achalasia Cardia to be safe in performance without CS and using fluoroscopic guidance. Also that the method is cost effective, nullifying adverse effects of CS and can be carried out outdoor. The description of EA of effacement of balloon 'waist' by EASL has not been mentioned before [2]. Our research also provides the experience of radiological development correlating subjective relief and manometry role in conducting Primary Achalasia Cardia.

METHODOLOGY:

The participants of this study were 23 patients which was receiving Pneumatic Dilatation for Primary Achalasia Cardia and the duration of this study was from October 2019 to September 2020. The subjects include 54% (12) male and 42% (11) female with mean age of 40.3 years (14-69 years' age group). To achieve the Primary Achalasia Cardia diagnosis, UGE and BSE was used. Subjects with strictures of oesophageal were not included in the research. Pneumatic Dilatation without CS was carried out with informed consent. Before operation, patients were reassured with bearable chest pain due to procedure in most cases. We used a 3 cent-meter Microvasive Rigifles balloon, a 2.8 millimetre video gastro-scope a pressure gauge and a guide wire for operation. Each subject was advised NPO (nil-per-oral) for six to twelve hours before the dilatation is started. After anaesthesia (topical pharyngeal with two percent xylocaine), the endoscope was initiated from the left (lateral) position. A high level clearance of oesophageal was acquired with gastro-scope directly. Accessory channel was used to place the guide wire into the stomach. With the help of guide wire, Rigifflex balloon was moved forward and endoscope was taken out back. Gastro-scope was introduced again. Approximately one by third proximal of the deflated balloon was left above ES, the rest of it was transferred to lower ES under direct vision. To get an ante-grade view of lower ES, the endoscope was placed at 5 centimetres proximal to the balloon. The safe procedure of holding the balloon catheter at mouth-guard was adopted. This is to prevent any distal stream out while insufflating air. Each subject was notified immediately regarding chest pain before the pneumatic balloon inflation. Dilatation sessions (2 successively, each for thirty to 45 seconds) were carried out with inflation pressure of ten to fifteen psi. Gastro-scope was used for constant keen observation of Lower ES to determine adequate dilatation, haemorrhage and oesophageal tear. The retrieval of pneumatic balloon was performed along with guide-wire after being deflated. A thorough inspection of dilated lower ES was carried out and then the removal of gastro-scope. After four to six hours, fluids (clear) were flowed orally with gradual increase in case the subject's asymptomatic condition continued. To remove oesophageal perforation, barium oesophagogram was attained within one day. In case the subject felt partial relief or any symptoms were found persistent, dilatation was once again planned.

RESULTS:

After Pneumatic Dilatation of Primary Achalasia Cardia, 90% (21) patients felt an immediate improvement symptomatically. During scheduled follow-up (6 weeks to 23 months), only 6% (2) cases required dilatation again (reported within 2 months) because of dysphagia recurrence (Figure-1A). All the patients (100%) experienced chest pain and only 66% (15) patients were observed with mild bleeding at lower ES (Figure-1B). One procedure was postponed due to symptoms of transient neurogenesis another experienced minor trauma in oesophageal because of minor displacement of guide-wire accidently. Both subjects were kept indoor under observation for one day. No perforation or haemorrhage was observed in oesophagus. No mortality with no gastroesophageal reflux reports in follow-up schedule.

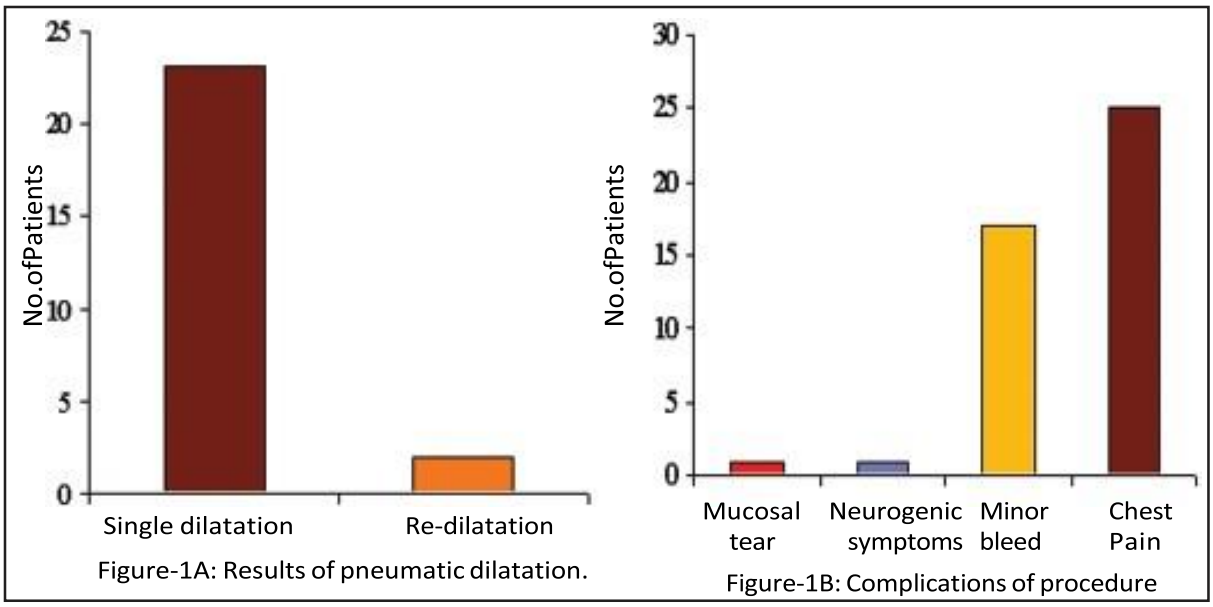

Figure-1: (A) Results of pneumatic dilatation (B) Complications of procedure

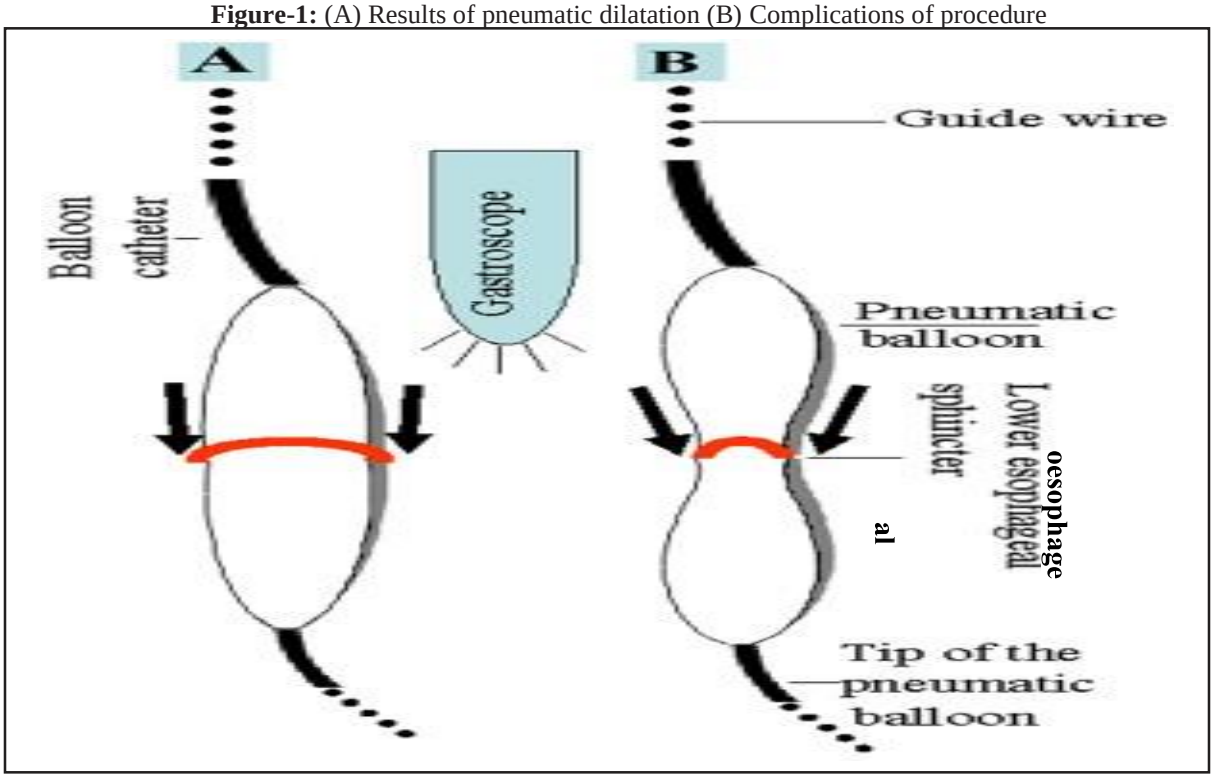

Figure-2A & B: Parallel balloon walls meeting LES at right angles indicate obliteration of balloon "waist" (B) ` balloon walls converging at LES indicate inadequate dilatation

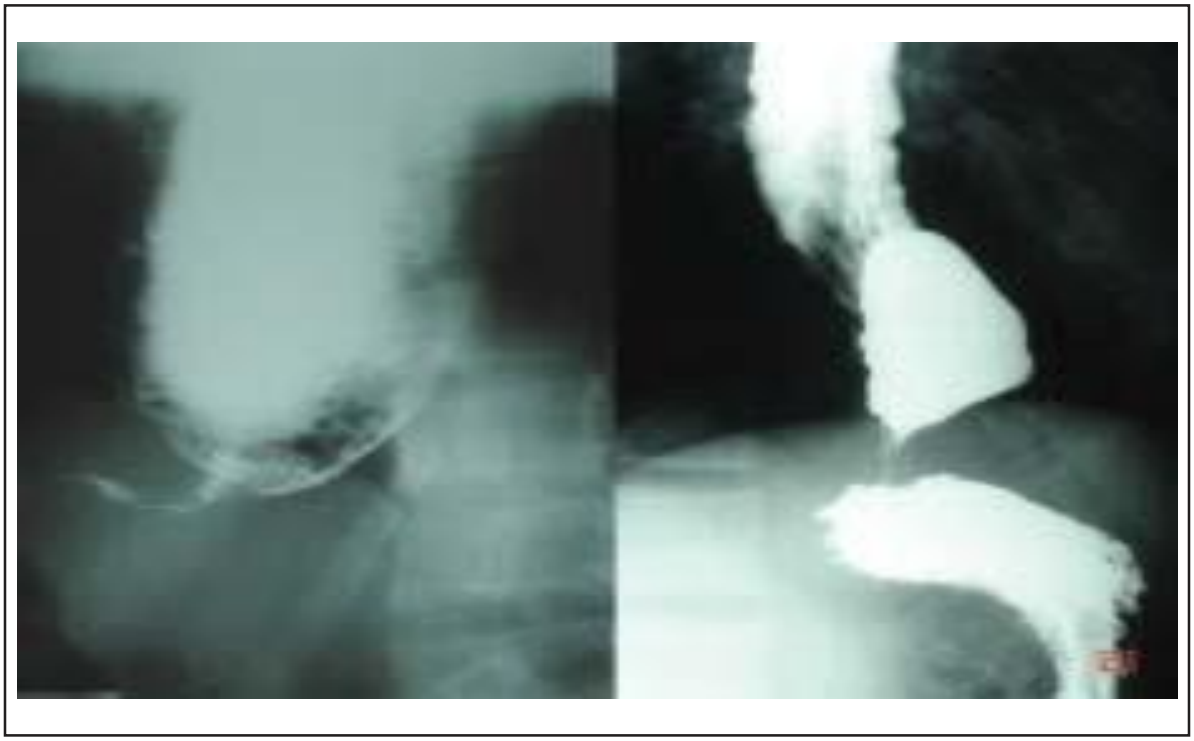

Fig-3: X-ray pictures showing the details of barium swallow study. (A) Classic "bird beak "tapering deformity of the oesophagus in achalasia cardia before dilatation & (B) post-dilatation study showing thin streak of barium in LES region" (same patient).

Fig-4: Barium swallow study of PAC (A) before dilatation and (B) after dilatation showing longitudinal folds in the LES region

DISCUSSION:

Patients attending our hospital due to Primary Achalasia Cardia are mostly caused by dysphagia being the 3rd leading reason for achalasia cardia. Patients feel mild oesophageal stricture first [3]. Our patients did not report any abnormality causing reasons for secondary Primary Achalasia Cardia. The recollection of oesophageal contents established strong clues in favour of endoscopic diagnosis of primary achalasia cardia [4]. During treatment, food

debris and liquid in oesophagus causes embarrassing respiration. Nasogastric tube is used to clear oesophagus which sometimes induces vomiting because the tube curls inside the oesophageal lumen and causes obstruction at lower oesophageal sphincter level [5]. Therefore, we sucked liquid through endoscopy and pushed the food content across the lower ES during pneumatic balloon advancement [6]. This experience proves to be safe for groups like obese, old, and pregnant. Procedure of CS proves to be tolerable due to sedation being a continuum and division between deep and CS is still not distinct. This leaves a subject's response unpredictable. Sedation preceding Pneumatic Dilatation of Primary Achalasia Cardia increases aspiration risks by depressing central respiratory and dampening cough reflex. Furthermore [7], oesophageal contents gravitate into airways due to lying position. Moreover, patients with neurogenic symptoms would have experienced increased hypotension due to sedation [8]. Likewise, harmful to patients receiving shocks during dilatation due to haemorrhage. In our research, pregnant patients were also harmed by sedation. Indoor observation and resuscitation cost is being reduced by no sedation. Conscious subjects are more responsive towards guidance about chest pain and subject could temporarily pause the treatment if desired [9].

Due to similar reasons, the use of CS is not supported during oesophageal stricture dilatation and endoscopy. Therefore, it is beneficial to compromise sedation hazards with tolerable chest pain. The use of 3-centimetre Rigi flex balloon was successful for dilatation (initial and 2nd) [10]. By keeping Pneumatic Dilatation parameters constant in this present research, our ability of achieving radiologic development and relief from symptoms were possible among 90% (21) patients with no noteworthy morbidity. The outcomes of our study are can be compared with other studies [11]. Having avoided radiation exposure of younger and pregnant patients, endoscopic guidance is far better than fluoroscopy. Ante-grade view of endoscopy real time observation of lower ES. During endoscopic treatment, bleeding, laceration and oesophageal tear could quickly be removed. We left up the one third of pneumatic balloon at lower ES which let us have huge intraluminal area for vision of endoscopy. To prevent distal flow out during inflation, the technician held the catheter of balloon [12]. We preferred EASL due to its safety during dilatation against fluoroscopy. The overhead view of LES shows the balloon walls meeting LES at 90 degrees, eliminating 'waist' of balloon effectively. (Figure-2A): If walls of balloon touch at the lower ES, the dilatation is likely to be insufficient. (Figure-2B). EASL allows pneumatic balloon to enlarge not even using pressure gauge. If balloon walls kept touching the hard-pressured lower ES at 90 degrees, the balloon may rupture. Therefore, almost accurate knowledge of obliteration of balloon 'waist' can be examined through EASL. EASL combined with a subject's improvement history can release from the need of radionuclide transit and lower ES manometry studies. However, a contrast observation for the exclusion of oesophageal perforation is helpful [13]. Although the subject may feel relief but barium flow across lower ES cannot be detected sometimes due to dilatation trauma causing muscle spasm in areas with high pressure. In such scenarios, re-dilatation must be carried out early. We received 12% (3) subjects with such situation. We suggest replacing 'bird beak' deformity (Fig. 3A) by a barium streak (Fig. 3B) or as longitudinal folds appear inside the region of lower oesophageal sphincter (Fig. 4) indicating radiological development [14].

As endoscopy is capable in the provision of detailed information about diagnosis among majority of subjects, therefore, using oesophageal manometry seems less rational before first dilatation rather using it at re-dilatation looks justified because of lower ES hypertonicity and/or oesophageal dysmotility. Successful re-dilatation among 6% (2) patients using manometry denotes the initial failure to be the reason of Lower ES hypertension. Improvement of radiology in 90% (21) subjects shows the role of manometry to be limited in treatment of Primary Achalasia Cardia. Patients with prolonged Primary Achalasia Cardia standing encounter sitophobia, therefore, slower diet return was tolerable for these subjects.

CONCLUSION:

To execute Pneumatic Dilatation of Primary Achalasia Cardia as an outdoor procedure through endoscopy effective with the same magnitude without CS. EASL can appreciate satisfying dilatation of LES. Assessment of radiology right after operation may mislead because of LES spasm. Oesophageal manometry has limited role and less relevance initially in Primary Achalasia Cardia.

REFERENCES:

1. Wu, P. I., Szczesniak, M. M., Craig, P. I., Choo, L., Engelman, J., Terkasher, B., ... & Cook, I. J. (2018). Novel intra-procedural distensibility measurement accurately predicts immediate outcome of pneumatic dilatation for idiopathic achalasia. American Journal of Gastroenterology, 113(2), 205-212.

2. Nabi, Z., & Reddy, D. N. (2018). Advanced therapeutic gastrointestinal endoscopy in children–today and tomorrow. Clinical Endoscopy, 51(2), 142.
3. Barret, M., Guillaumot, M. A., Leandri, C., Leblanc, S., Coriat, R., Belle, A., & Chaussade, S. (2020). Intraoperative high-resolution esophageal manometry during peroral endoscopic myotomy. Scientific Reports, 10(1), 1-6.
4. Nabi, Z., Ramchandani, M., Chavan, R., Darisetty, S., Kalapala, R., Shava, U., ... & Reddy, D. N. (2019). Outcome of peroral endoscopic myotomy in children with achalasia. Surgical Endoscopy, 33(11), 3656-3664.
5. Chrystoja, C. C., Darling, G. E., Diamant, N. E., Kortan, P. P., Tomlinson, G. A., Deitel, W., ... & Canadian Achalasia Trial Study Group. (2016). Achalasia-specific quality of life after pneumatic dilation or laparoscopic Heller myotomy with partial fundoplication: a multicenter, randomized clinical trial. American Journal of Gastroenterology, 111(11), 1536-1545.
6. RAB, O. N. (2020). Oude Nijhuis RAB, Zaninotto G, Roman S et al. European Guideline on Achalasia–UEG and ESNM recommendations. United European Gastroenterology Journal 2020, Vol. 8 (1): 13–34. United European Gastroenterology Journal, 8(1), 13-34.
7. Sami, S. S., Haboubi, H. N., Ang, Y., Boger, P., Bhandari, P., De Caestecker, J., ... & Paterson, S. (2018). UK guidelines on oesophageal dilatation in clinical practice. Gut, 67(6), 1000-1023.
8. Hathorn, K. E., Chan, W. W., Aihara, H., & Thompson, C. C. (2020). Determining the Safety and Effectiveness of Electrocautery Enhanced Scissors for Peroral Endoscopic Myotomy (with Video). Clinical Endoscopy.
9. Bohnen, J. D., & Meireles, O. R. (2020). Master's Program Flexible Endoscopy Pathway: Balloon Dilation. In the SAGES Manual of Flexible Endoscopy (pp. 81-98). Springer, Cham.
10. Swaney, J. M., Smith, Y. M., & Sachai, W. (2016). Primary achalasia: practice implications. The Journal for Nurse Practitioners, 12(7), 473-478.
11. Oude Nijhuis, R. A. B., Zaninotto, G., Roman, S., Boeckxstaens, G. E., Fockens, P., Langendam, M. W., ... & Weusten, B. L. A. M. (2020). European guidelines on achalasia: United European Gastroenterology and European Society of Neurogastroenterology and Motility recommendations. United European gastroenterology journal, 8(1), 13-33.
12. Vaezi, M. F., & Lappas, B. M. (2019). Endoscopic Management of Achalasia: Botulinum Toxin and Pneumatic Dilation. In the SAGES Manual of Foregut Surgery (pp. 409-421). Springer, Cham.
13. Nijhuis, R. O., Zaninotto, G., Roman, S., Boeckxstaens, G. E., Fockens, P., Langendam, M. W., ... & Weusten, B. L. A. M. (2020). European Guideline on Achalasia–UEG and ESNM recommendations. United European Gastroenterology Journal, 8(1), 13.
14. Vaezi, M. F., Pandolfino, J. E., Yadlapati, R. H., Greer, K. B., & Kavitt, R. T. (2020). ACG Clinical Guidelines: Achalasia. Official journal of the American College of Gastroenterology| ACG.