CODEN [USA]: IAJPBB ISSN : 2349-7750

INDO AMERICAN JOURNAL OF
PHARMACEUTICAL SCIENCES
SJIF Impact Factor: 7.187
http://doi.org/10.5281/zenodo.4317400

Avalable online at: http://www.iajps.com *Research Article*

CHARACTERIZATION AND MANAGEMENT OF DEEP NECK INFECTIONS

[1]Dr. Suman Arooj, [2]Dr. Muntaha tariq, [3]Dr.Nafeesa Abdullah
[1]Women Medical and Dental College Abbotabad
[2]Margalla Institute of Health Sciences, Rawalpindi
[3]Bahria University of Medical and Dental College

Article Received: October 2020 **Accepted:** November 2020 **Published:** December 2020

Abstract:
Background and Objectives: *A total of 91 patients were included in this retrospective research of deep neck infections to find the clinical disease pattern and form an effective management plan. We determined our findings via clinical, radiological, and operative measures. Peritonsillar space was found in 72 patients in total, 8 patients had parapharyngeal space, submandibular space was determined in 7 patients, retropharyngeal space 1 patient, one patient had a superficial space, anterior visceral space (1), and visceral vascular space (1). In 8 patients out of the 19 patients, who did not present with a peritonsillar space infection, the origin of the infection was found, 4 of these were odontogenic. 38 patients in total required immediate surgical drainage of the abscess. On 5 patients the doctors performed tracheotomy because dyspnea was noticed to be increasing. 1 patient died due to unknown reasons, who presented with diabetes mellitus and a history of myocardial infraction. No significant occurrence was found in other patients, they had an uneventful recovery with no complications that's mainly due to an effective combination of early diagnosis, anti microbial therapy and intensive surgical management contributed to the good prognosis.*

Key words: *cervical fascia; neck space; infection; management*

Corresponding author:
Dr. Suman Arooj,
Women Medical and Dental College Abbotabad

QR code

Please cite this article in press Suman Arooj et al, ***Characterization And Management Of Deep Neck Infections.,*** *Indo Am. J. P. Sci, 2020; 07(12).*

INTRODUCTION:

Deep neck infections affect visceral spaces of the head and neck and their contents. Although the prevalence of deep neck infection has decreased markedly since antimicrobial drugs became available, these infections continue to be a cause of significant morbidity and mortality.[6,11,14] In addition to the systemic toxicity and the localized respiratory and digestive tract disturbance characteristic of these infections, more serious sequelae such as life-threatening airway obstruction, mediastinitis, pericarditis, internal jugular vein thrombosis, epidural abscess, and carotid artery erosion may result[1,7,15,16,18]. In this paper, we present a review of 91 cases of deep neck infection that were treated in our department. Our aim was to study the pattern of this clinical condition and to formulate a management plan.

MATERIAL AND METHODS:

We reviewed the medical records of 91 patients with a diagnosis of deep neck infection. Of these patients, 69 had been admitted to Margalla institute of health sciences between 2010 and 2019.

Diagnostic imaging procedures included computed tomography (CT), ultrasonography, and plain radiography. The predominant visceral space involved was determined retrospectively by clinical, radiologic, and operative findings. All patients were closely monitored for impending airway obstruction and septicemia and were immediately started on intravenous antimicrobial therapy without waiting for culture and sensitivity reports. Since deep neck infections are often polymicrobial in nature [5,13,14,18], many authors recommend combination therapy including clindamycin, which has excellent activity against anaerobes, to ensure maximum antimicrobial effect[2,13,15,18]. Therefore, the patients were treated with a broad-spectrum penicillin derivative, such as piperacillin, in combination with clindamycin; or with a cephalosporin combined with clindamycin; or with clindamycin alone. When the presence of an abscess was established, incision and drainage were performed. Factors such as age, sex, diagnosis, cause, microbiology, therapy, and complications were studied.

RESULTS:

Characteristics of patients and infections

The age distribution of the 91 patients is shown in Fig. 1. There were 71 males (78%) and 20 females (22%), whose ages ranged 1-81 years (mean 36 years). Four patients had diabetes mellitus. One patient's disease was well controlled by diet, one was well controlled by hypoglycemic medication, and one was stabilized by the administration of insulin. The remaining patient was an undiagnosed diabetic

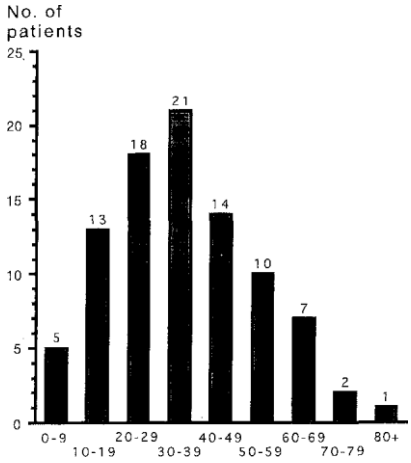

Fig 1. Age distribution

Of the 91 patients, 72 had a peritonsillar space infection (Fig. 2). The second most common location was the parapharyngeal space (eight patients) (Fig. 3), followed by the submandibular space including the sublingual and sub- maxillary space (seven patients) (Fig. 4). The other locations were retro- pharyngeal (one patient), visceral vascular (one patient) (Fig. 5), anterior visceral (one patient), and superficial (one patient).

Fig. 2. Postcontrast CT scan at level of oropharynx, showing left peritonsillar abscess (large arrow). Note that left parapharyngeal space is preserved (small arrow).

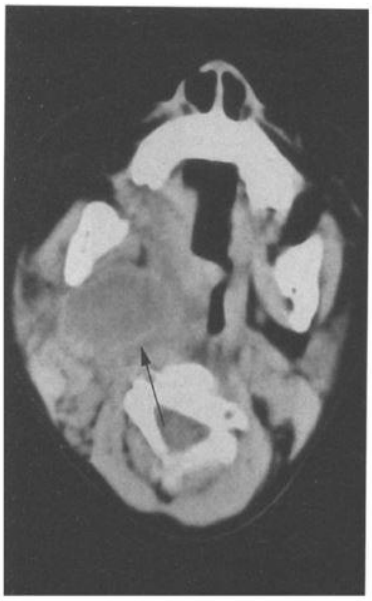

Fig. 3. (Patient 2) Precontrast CT scan at level of oropharynx, showing right parapharyngeal abscess (arrow).

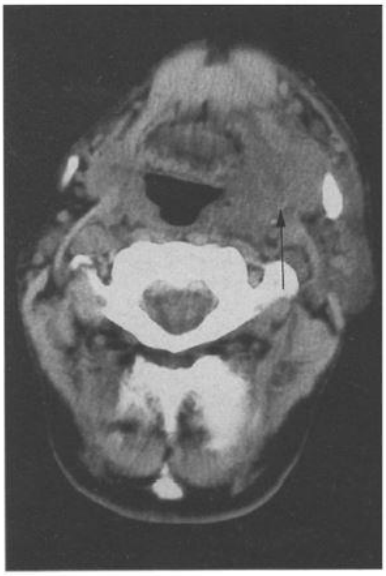

Fig. 4. (Patient 9) Precontrast CT scan at level of angle of mandible, showing swelling in left submandibular region (arrow).

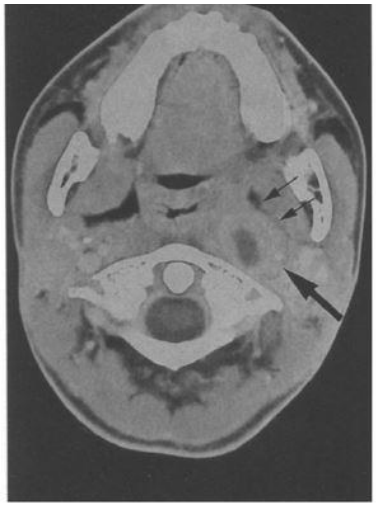

Fig. 5. (Patient 17) Postcontrast CT scan at level of atlas vertebra, showing abscess in left visceral vascular space (large arrow). Note that left parapharyngeal space is preserved (small arrows).

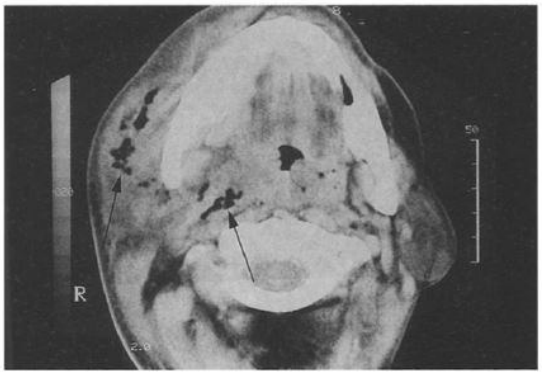

Fig. 6. (Patient 5) Precontrast CT scan at level of body of mandible, showing swelling of right parapharyngeal and submandibular region and gas bubbles within it (arrows).

The peritonsillar space infections in the 72 cases followed acute tonsillitis. Of the 19 patients who did not have a peritonsillar space infection, the origin of infection was diagnosed with certainty in eight patients (Table 1). A patliologic dental condition was the most common cause of deep neck infection in these patients.

Gram's stain, aerobic cultures, and anaerobic cultures were done on purulent material obtained by aspiration with a syringe or by swabs. Results of cultures were available for 29 of the 91 patients. Of these, 25 cultures were positive and four were negative. Twelve of the 25 specimens had more than one organism. The organisms are listed in Table 2. The most common organisms isolated were viridians group streptococci, followed by *Neisser ia* sp. An- aerobes accounted for 4/25 (16%) of the positive cultures.

Table 7. Clinical profiles of 19 patients with deep neck infections (excludes case of peritonsillar space infection)

Patient no.	Age (years)	Sex	Location	Cause	Dia-betes	Bacteriologic findings	Drainage of abscess	Tr'acheotomy	Duration of hospital stay (days)	Death
1	60	M	Parapharyngeal	Unknown	+	No growth *Staphylococcus aureus*	External	+	14	–
2	1	M	Parapharyngeal	Untukown		*Eilcenella corrodens*	External		21	
3	9	F	Parapharyngeal	Trauma	—	*Pseudon1ona.s puticla*	External		10	
4	55	F	Parapharyngeal	Unknown	—	*Fusobacteri.irn vat rum*	External	+	31	
5	60	M	Parapharyngeal	Odoiito-genic'	+	No culture	External	+	1	+
6	3	M	Parapharyngeal	Trauma	—	*Eilcenella corrodcns*	Intraoral		12	
7	45	M	Parapharyngeal	Odonto-genres	—	*Streptococcus viridans* *Neisseria* sp. *Haemophilus* sp.	Spontaneous rupture		13	
8	42	F	Parapharyngeal	Unknown	–	No culture	Antibiotics alone	–	5	–
9	48	M	Submandibular	Unknown	—	*Prevotella or alis*	External		16	
10	63	M	Submandibular	Unknown	–	Gram-negative rod	External		T4	
11	45	M	Submandibular	Odonto-genie'	—	No culture	Spontaneous rupture	–		–
12	71	M	Submandibular	Odonto-genic'		Q-Streptococcus	Spontaneous rupture		8	
13	7.5	F	Submandibular	Unknown	—	No culture	Antibiotics alonc		13	
14	5	M	Submandibular	Unknown	—	No culture	Antibiotics alone		8	
15	3	M	Submandibular	Unknown		No growth	Antibiotics alone		10	
16	47	M	Retropharyngeal	Trauma	—	*Streptococcus internledius*	Intraoral		9	
17	14	M	Visceral vascular	Unknown		No culture	Antibiotics alone		20	
18	32	M	Anterior visceral	Iatrogenic (fiberscope)	—	*Strep tocoe'cus sanguis* Yeast-like fungus	Spontaneous rupture		11	–
19	63	F	Superficial	Unknown	+	*Streptoco cti.s pyogenes*	Antibiotics alone	+	31	

[1] Infection after extraction of various tooth. [2] Dental caries. [3] Pericoronitis.

Table 2. Organisms isolated in 29 patients with deep neck infections (includes case of peritonsillar space infection)

Organism	No. of patients
Viridans group streptococcus	10
Neisseria sp.	5
Haemophilus sp.	4
Streptococcus pyogenes	4
Non-A β-streptococcus	3
Eikenella corrodens	2
Bacteroides capillosus	2
Candida albicans	2
Streptococcus intermedius	1
Staphylococcus aureus	1
Pseudomonas putida	1
Gram-negative rod	1
Fusobacterium varium	1
Prevotella oralis	1
Yeast-like fungus	1

Patient management and outcome

Thirty-eight (42%) of the 91 patients re- quired surgical drainage of the abscess. Six patients had external neck drainage; four with parapharyngeal space infection and two with submandibular space infection. Thirty-two patients had intra- oral drainage; 29 with peritonsillar space infection, two with parapharyngeal space infection, and one with retro- pharyngeal space infection. In 11 (12'Z) of the 91 patients, the abscesses ruptured

spontaneously. Of these 11 patients, seven had a peritonsillar space infection. The remaining 46'/o (42/91) recovered with antimicrobial therapy alone.

The only major complication was air- way obstruction requiring tracheotomy. This occurred in one patient with peritonsillar cellulitis, in three patients with parapharyngeal abscess, and in one patient with cellulitis of the superficial space.

The mean duration of hospital stay related to the infection was 8.2 days (range: 1-31 days).

One patient (no. 5) died, a 60-year-old man with diabetes mellitus and a history of myocardial infarction and coronary artery bypass surgery. Four days after a carious tooth was extracted, he complained of a sore throat and dyspnea. A CT scan showed gas bubbles in the parapharyngeal and submandibular space (Fig. 6). He had a cardiac arrest and died 2 h after performance of tracheotomy and successful drainage of the parapharyngeal abscess under general anesthesia. Since no autopsy was permitted, the cause of death remained unknown.

DISCUSSION:

Deep neck infections arise from various sites in the head and neck including the teeth, salivary glands, cervical lymphoid tissue, and adeno-tonsillar tissues. Most common are those of odontogenic and tonsillar origin.[6,13,14,17] In our series, nearly 80 percent of the deep neck infections originated in the tonsils. The cause of infection remained unknown in more than half of the remaining cases, despite detailed history, and physical and radiologic examination. The initial focus of infection in these patients may have been in the oropharynx and may have resolved by the time of presentation. Other studies have also reported a significant proportion of deep neck infections of unknown cause [15,16].

The most common deep neck infection, that is, peritonsillar space infection, occurs frequently in young adults. In our study, as well as in other studies[6,14,16], there was a preponderance of males. The reason for this sex predilection remains unknown.

The organisms most often isolated from deep neck infections are those that usually reside in the oropharynx[5]. Mixed infections, with both aerobic and anaerobic bacteria, are the rule. [3,16,18] In our study, however, anaerobes accounted for 16% of the positive cultures. This low percentage may be due to the collection of the specimen with swabs in some cases. Often, it is claimed, because of prior antimicrobial therapy, the exudate is sterile.[5]

The treatment of deep neck infections has three main aspects: medical management, surgical management, and airway control.[3]

Early intervention with antimicrobial drugs, preferably a penicil Min derivative and clindamycin, is the key to successful therapy and avoidance of complication[6,15]. Attempts to obtain material for culture are important, but treatment should not await sensitivity reports[15].

Deep neck infections still in the cellulitic stage can be successfully treated with antimicrobials alone. Surgical intervention is indicated when an abscess is established. CT, magnetic resonance imaging, and ultrasonography are useful for detecting the presence of a deep neck abscess [4,8,10,12]. In the absence of a demonstrable abscess, incision and drainage are advised only for patients who are deteriorating clinically, or who fail to improve within 48h of initiation of antimicrobial therapy[2,15].

Management of the airway is the most important issue in treating deep neck infections. A tracheotomy should be considered whenever difficult intubation is anticipated; otherwise, overzealous attempts at intubation may jeopardize an already compromised airway[14]. Published reports indicate that airway obstruction of a sufficient degree to warrant tracheotomy for airway support is present in 12-16% of patients with deep neck abscesses[6,14,16]. HAR-EL et al.[6] reported that the need for tracheotomy was common in retropharyngeal and submandibular abscesses.

Recommendations

During the time of our research and the data collected in previous years, we have seen only one death, no septicemia, no mediastinitis, no jugular vein thrombosis, and no major vessel rupture in cases of deep neck infections. The combination of early radiologic diagnosis, effective antimicrobial therapy, and intensive management all contribute to the good prognosis.

REFERENCES:

1. ALEXANDER DW, LEONARD JR, TRAIL ML. Vascular complications of deep neck abscesses: a report of four cases. Lar- yngoscope 1968: 78: 361—70.
2. BLOMQUIST IK, BARER AS. Life-threaten- ing deep fascial space infections of the head and neck. Infect Dis Clin North Am 1988: 2: 237-64.
3. BROOK I. Aerobic and anaerobic bacter- iology of peritonsillar abscess in children. Acta Paediatr Scand 1981: 70: 831-5.
4. **ENDICOTT** JN, NELSON RJ, SARACENO CA. Diagnosis and management de- cisions in infections of the deep fascial spaces of the head and neck utilizing computerized tomography. Laryngo- scope 1982: 92: 630—3.
5. GATES GA. Deep neck infection. Am I Otolaryngol 1983: 4: 420—1. 6
6. HAR-Er G, AROrS+v JH, SHAHA A, L - CENTE FE. Changing trends in deep neck abscess: a retrospective study of 110 pa- tients. Oral Surg 1994: 77: 446—50.
7. **HEINDEL** DJ. Deep neck abscesses in adults: management of a difficult airway. Anesth Analg 1987: 66: 774—6.
8. Hoes GR, McMAws K, NEWMAN CRK, POTTER JL, TINSLEY PP. Computed tomography in the diagnosis of deep- neck infections. Arch Otolaryngol 1982: 108: 693-6.
9. **KREUTZER** EW, JAFEK BW, Jonson ML, ZUNKEL DE. Ultrasonography in the pre- operative evaluation of neck abscesses. Head Neck Surg 1981: 4: 290—5.
10. LAZOR JB, CUNNINGHA1\1 MJ, EAVEY RD, **MBER** AL. Comparison of computed tomography and surgical findings in deep neck infections. Otolaryngol Head Neck Surg 1994: 111: 746—50.
11. Lrvrrr MGW. Cervical fascia and deep neck infections. Lar yngoscope 1970: 80: 409—35.
12. MATT BH, LusK RP. Delineation of a deep neck abscess with magnetic reson- ance imaging. Ann Otol Rhinol Laryngol 1987: 96: 615—17.
13. **PETERSON** LJ. Contemporary manage- ment of deep infections of the neck. I Oral Maxillofac Surg 1993: 51: 226— 31.
14. SfiTHl DS, STANrEY RE. Deep neck ab- scess changing trends. J Laryngol Otol 1994: 108: 138—43.
15. STlERNBERo CM. Deep-neck space infec- tions: diagnosis and management. Arch Otolaryngol Head Neck Surg 1986: 112: 1274—9.
16. TOM MB, RICE DH. Presentation and management of neck abscess: a retrospec- tive analysis. Laryngoscope 1988: 98: 877—80.
17. **VIROLAINEN** E, **HAAPANI£MI** J, AITASALO K, SUONPAA J. Deep neck infections. Int J Oral Surg 1979: 8: 407—11.
18. WILLS PI, VERNON RP. Complications of space infections of the head and neck. Laryngoscope 1981: 91: 1129—36.