CODEN [USA]: IAJPBB ISSN : 2349-7750

INDO AMERICAN JOURNAL OF
PHARMACEUTICAL SCIENCES
SJIF Impact Factor: 7.187
http://doi.org/10.5281/zenodo.4322605

Avalable online at: http://www.iajps.com *Research Article*

A RESEARCH STUDY ON PATIENTS WITH HEPATITIS C AND THE RECURRENCE OF SKIN

[1]Dr. Nimra Rehan, [2]Dr. Amara Khalid, [3]Dr. Afia Batool
[1]Bahawal Victoria Hospital Bahawalpur

Article Received: October 2020 **Accepted:** November 2020 **Published:** December 2020

Abstract:
Objective: *To make a decision on recurrence of skin indications in cases with hepatitis C.*
Methods: *About 110 hepatitis C cases, admitted to Restoration Units of Jinnah Hospital, Lahore from December, 2017 to November, 2018 were enrolled over a six-month period, in this cross-sectional examination. The skin apparitions of these patients were recorded and broken down.*
Results and conclusion: *A large proportion of the patients had more than one skin indication. Out of 110 patients, 56 (51%) were male and 54 (49%) female. The Lion's share of the patients (73%) were between 21 and 60 years of age. These were summarized pruritus 31%, plan lichen 32%, urticaria 27%, leukocyte clastic vasculitis 26%, acral necrotic erythema 21% and late cutaneous porphyria 5%. Skin Appearances of hepatitis are normal. They could be the main clinical indication of a long-lasting hepatitis C infection. Pruritus, lichen planus, urticaria, leukocyte classic vasculitis, acralnecrolytic erythema and late porphyria have been the main skin manifestations recorded. Screening these patients on the basis of these dermatoses and examining them in the same manner can help to quickly identify and avoid the complexities of this serious condition.*
Key words: *HCV, Hepatitis C, coetaneous manifestations.*

Corresponding author:
Dr Nimra Rehan
Bahawal Victoria Hospital Bahawalpur.

QR code

Please cite this article in press Nimra Rehan et al, ***A research Study On Patients With Hepatitis C And The Recurrence Of Skin.,*** *Indo Am. J. P. Sci, 2020; 07(12).*

INTRODUCTION:

HCV mimics cytoplasm of hepatocytes, but is not legitimately cytopathic. Hepatitis C infection (HCV) is an RNA infection that belongs to Flaviviridae family. The stability of the disease appears to be contingent on the rapidity of infection creation and the constant cell-to-cell spread, as well as the absence of an unresponsive response of T cells to HCV antigens [1]. The HCV turnover rate can be extremely high through replication of 1012 to 1014virions per day and an anticipated viral half-life of 2 to 3 hours. The speed of viral repetition and the nonappearance of viral RNA polymerase mounting errors are the reasons why the HCV RNA genome changes regularly. There are sevenrecognized genotypes (numbered 2 to 8) and more than 52 subtypes (e.g., 1a, 1b, 2a...). The recurrent changes in HCV and various subtypes have made HCV immunization testing a necessity [2]. Enduring hepatitis C is the most well-known reason for ongoing liver illness and cirrhosis, and is the most widely recognized sign for liver transplantation in the United States (US), Australia, and most European countries. Hepatitis C is the most common cause of liver disease and cirrhosis, and is the most widely recognized sign for liver transplantation in the United States (US), Australia, and most European countries. In the US, it is the most common cause of liver disease and cirrhosis. Approximately 172 million people are infected with HCV worldwide, representing about 3% of the world's population. Hepatitis C (HCV) infection is the most widely recognized constant blood contamination in the United States and is responsible for 42% of the world's interminable liver illness [3]. Hepatitis C contagion is one of maximumknown ongoing viral diseases in the world, with approximately 303 million people permanently infected worldwide. Endless HCV contamination causes cirrhosis of the liver if not treated properly. Doctors have been aware of cirrhosis of the liver and its complexity since the time of Hippocrates [4]. The World Health Organization (WHO) has estimated that cirrhosis is responsible for 1.2% of all deaths worldwide. Approximately 175 million persons worldwide have cirrhosis of the liver. Cirrhosis is the tenth leading cause of death in the United States. About 32% of cirrhosis patients bite the dust in a state of hepatic trance. Hepatitis C disease is fundamental in this territory of southern Punjab. It is associated with many skin signs. These skin signs may prompt early detection and determination of this relentless infection. Deciding on the recurrence of these skin changes in hepatitis C patients was the aim of this investigation [5].

METHODOLOGY:

Patients of both sexes who were HCV antibody positive according to the BIOTEC® Latex Kit method and HCV RNA proximity by polymerase chain reaction were recalled for the investigation. About 110 hepatitis C cases, admitted to Restoration Units of Jinnah Hospital, Lahore from December, 2017 to November, 2018 were enrolled over a six-month period, in this cross-sectional examination. Patients under 18 years of age, known heavy drinkers, patients with essential biliary cirrhosis and patients with a positive HBsAg test were excluded from the study. Hepatitis C cases with evidence of positive HCV, as indicated by the criteria for consideration, conceded in the Restoration Units of Bahawal-Victoria Hospital, Bahawalpur were considered. One hundred positive HCV cases were enrolled in the investigation. Informed consent of patients was obtained and all data were collected on the pre-determined pro forma, in two parts, Part I including the intricacies of the social segment such as age, sex, occupation and instructor status, while Part II included the study factors. Skin appearances were observed in each patient and the dermatological conclusion was confirmed by a senior specialist dermatologist and reviewed as necessary. Patients who had HCV antibodies in their serum were exposed to HCV RNA by PCR. Cryoglobulins and degrees of supplementation were broken down in patients with positive serological tests for rheumatoid factor. Patients with concomitant liver disease (co-contamination with hepatitis B infection), alcoholic liver disease and essential biliary cirrhosis were excluded. All data collected on proforma were reviewed using the Sociology Measurement Set (SPSS), variant 23.0. The frequencies of individual skin signs and their rates were determined in hepatitis C patients in general, as well as sex and age. The most prominent skin signs were also recorded, with or without a history of antiviral treatment. Mean and standard deviation were determined for age. The skin apparitions of these patients were recorded and broken down.

RESULTS:

Approximately 100 hepatitis C patients were recalled for testing on the basis of HCV antibody positive and PCR for this investigation. Of these, 55 (54%) were male and 45 (46%) were female, the ratio of males to females being 1.05:1.01. Age ranged from 16 years to over 72 years of age. The majority of patients (74%) were between the ages of 20 and 60 years, while only 9% were younger than 21 years and 19% were older than 59 years. A large proportion of the patients were generally middle-aged, for example 82% of the patients were 56 years old (running age 25-79 years). Of these 110 patients, 19 had a history of a previous

medical procedure, 16 had received blood transfusions, four patients had dental methodology, two had undergone hemodialysis for ongoing renal deception and one patient had a history of misuse of intravenous medications. In 68 out of 110 cases, the course of transmission was undetected.

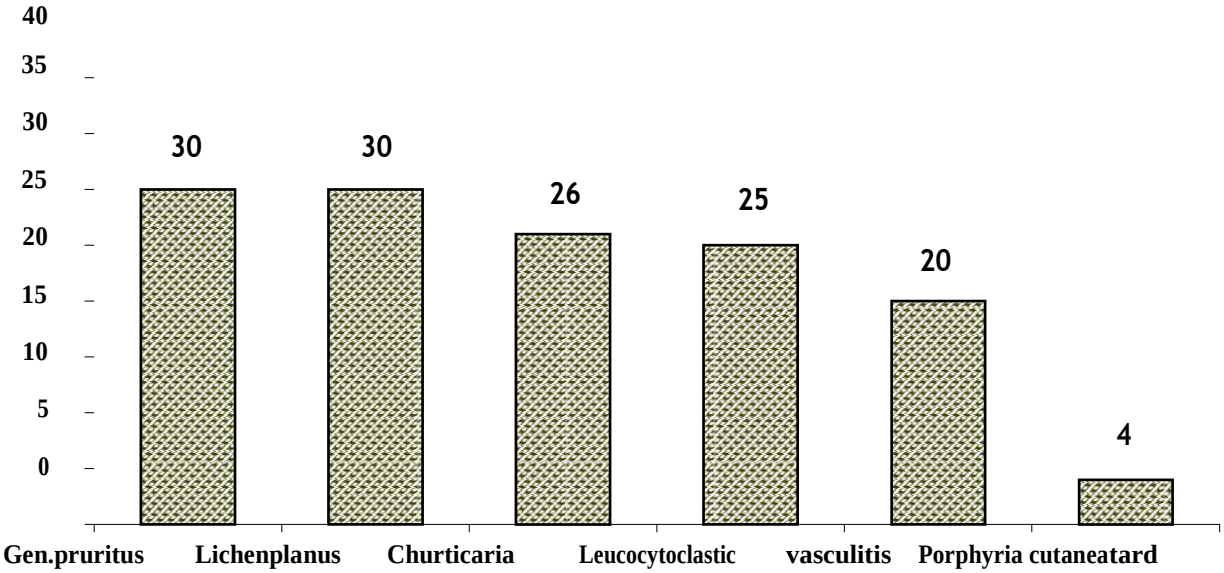

Figure 1: Incidence of different cutaneous manifestations in 100 HCV patients.

All of the patients were on strong or symptomatic therapy. Figure 1. shows the recurrence of various skin indications found in the examination population. Out of 100 patients, summary pruritus was observed in 32% (19 men and 13 women), lichen planus in 32% (19 men and 15 women), urticaria in 267% (1 men and 14 women), leukocyte clastic vasculitis in 27% (16 men and 12 women), acralnecrolytic erythema in 20% (12 men and 8 women) and late cutaneous porphyria in 41% (4 men and 1 woman), Summary pruritus was found in 30 (30%) cases. At the time of evaluation, 7 had dry skin and 2 had abraded papules, the skin of the rest was ordinary. In 6 of the 32 patients with pruritus, moderate cholestasis was available. Histopathology revealed cutaneous leukocyte clastic vasculitis. In 6 of these patients, RF was definite, supplementation rates were low and cryoglobulinemia was noted. Necrolyticacral erythema was recorded in 22% of patients as erythematous and textured plaques on the hands and feet. Histopathology was reminiscent of the disease. In 4 MDT patients there was a history of photosensitivity and runny face and hands, hyperpigmentation, hypertrichosis and scarring; however, biochemical determination could not be asserted due to the inaccessibility of testing facilities. Serum ALT and AST levels were normal in 23 of 110 patients with ongoing HCV infection (23%). Fifty-five patients (55%) had serum transaminase levels ranging from mild to very high. RF was definite (>20 IU/mL) in 45 of 110 patients (45%). In 6 serum tests performed in RF positive patients, cryoglobulinemia and adjusted supplementation levels were recognized. Forty patients (41%) had received or were receiving antiviral therapy, which was a mixture of interferon and ribavirin. None of the patients were on interferon alone or ribavirin therapy.

DISCUSSION:

The accurate and convenient discovery of HCV is fundamental to prevent dangerous tangles. In this review, all 110 patients were incorporated. 56 (51%) were male and 54 (49%) were women. Male potency has been found in various examinations conducted in Pakistan, as it has been found overall in this survey. This gender distinction could be due to the postponement of interviewing by female patients and the gender disparity in the use of medical service offices in Pakistan [6]. The other factor could be that, in contrast to women, men are generally increasingly exposed to the risk factor of HCV transmission, such as transmission through hairdressers and misuse of intravenous drugs. Fifty-seven percent of patients were unaware. Epidemiological investigations

revealed that HCV disease is unprecedented in age groups younger than 20 years and invasive in people over 41 years of age [7]. Our results show only 9 patients under 20 years of age with a recurrence of 8%, thus a virtually comparative situation; yet we found the infection also regular in the 40-49 age group. This may demonstrate that in our region, young people are turning into individuals injured by the disease. Continuous HCV is a major source of cirrhosis in Bahawalpur. As there is as yet no accessible immunization against hepatitis C and it is the most common reason for cirrhosis in this part of the world, increasing caution must be exercised to prevent its transmission, by avoiding risk factors and detecting it early, if a patient shows any skin sign [8]. Irrespective of the growth of cirrhosis, early detection and brief treatment of these viral contaminations improves the overall outcome of patients and prevents the progression of hepatocellular carcinoma. Once the cirrhosis procedure has begun, the onset of hepatocellular carcinoma ranges from 2% to 5%. Hepatitis C is reaching plague proportions and is a huge reason for the gloom all over the world. Convenient mediation can settle the disease and tip the scales of horror and mortality. This underscores the importance of identifying those infected with HCV [9]. Since dermatological indications may be the primary and clearest indication of the endless HCV, it is important that human services experts be aware of these dermatological appearances. Skin reflections are themselves a cause of gloom, but they can also give aberrant information about the basic disease. Such a perception encourages early identification and early treatment. Antiviral treatment of HCV may also be essential to restore skin disease, such ascryoglobulinemia. In addition, such distinctive evidence can prevent the transmission of the disease [10].

CONCLUSION:

Screening for HCV infection in certain dermatological conditions may prompt antiviral therapy that is successful in relieving skin disease. In addition, such recognizable evidence will help prevent HCV transmission. The cutaneous aspect may be the primary clinical indication for the endless HCV infection.

REFERENCES:

1. Bukh J, Miller RH, Purcell RH. Geneticheterogeneity of hepatitis C virus:Quasispecies and genotypes. *Semin LiverDis.* 1995;**15**:41-63.
2. Neumann AU, Lam NP, Dahari H *et al*.Hepatitis C viral dynamics in vivo and theantiviral efficacy of interferon-alphatherapy. *Science*. 1998;**282**:103-7.
3. Poynard T, Yuen MF, Ratziu V, Lai CL.Viral hepatitis C. *Lancet*. 2003;**362**:2095-2100.
4. Paoletti V, Mammarella A, Basili S et al.Prevalence and clinical features of skindisease in chronic hepatitis C infections. Aprospective study in 96 patients.*Panminerva Med*. 2002;**44**:349-52.
5. Mahboob A, Haroon TS, Iqbal Z *et al*.Frequency of anti-HCV antibodies inpatients with lichen planus. *J CollPhysicians Surg Pak*. 2003;**13**:248-52.
6. Tameez-ud-Deen, Naqqash S, Butt AQ.Lichen planus and hepatitis C virusinfection: An epidemiologic study. *J PakAssocDermatol.* 2003;**13**:127-9.
7. Dupin N, Chosidow O, Lunel F *et al*.Essential mixed cryoglobulinemiacomparativestudy of dermatologicalmanifestations in patients infected ornoninfected with hepatitis C virus. *ArchDermatol*. 1995;**131**:1424-7.
8. Lauer GM, Walker BD. Hepatitis C virusinfection. *N Engl J Med*. 2001;**345**:41-52.
9. Gisbert JP, Garcia-Buey L, Pajares JM,Moreno-Otero R. Prevalence of hepatitisC virus infection in porphyria cutaneatarda: systematic review and metaanalysis.*J Hepatol.* 2003; 39: 620-627
10. 22 Chuang TY, Stitle L, Brashear R, Lewis C. Porphyria cutaneatarda and hepatitis Cvirus: A case control study and metaanalysisof the literature. *J Am AcadDermatol*. 1999;**41**:31-6.