CODEN [USA]: IAJPBB ISSN : 2349-7750

INDO AMERICAN JOURNAL OF
PHARMACEUTICAL SCIENCES
SJIF Impact Factor: 7.187
http://doi.org/10.5281/zenodo.4381250

Avalable online at: http://www.iajps.com *Research Article*

CEPHALOMETRIC SOFT AND HARD TISSUE ASSESSMENT WITH CENTRAL REFERENCE LINE IN A HETROGENEOUS SAMPLE

Dr Asraa Naeem[1], Dr Sehrish Zafar[2], Dr Arqam Ali Khan[3]

[1,2]Dental Section Faisalabad Medical University Faisalabad, [3]de'Montmorency College of Dentistry, Lahore.

Article Received: October 2020 **Accepted:** November 2020 **Published:** December 2020

Abstract:

Aim: *The study assessed the usefulness of using the newly introduced non-anatomical soft and hard tissue centroid line (S&H centroid) in differentiating between the sagittal and vertical cephalometric interdental relationships in a heterogeneous sample.*

Methods: *This study was held in the Dental Section Allied Hospital, Faisalabad for six-months duration from February 2020 to July 2020. The sample consisted of 87 12 "x 14" side cephalometric radiographs of mixed sagittal individuals; skeletal class I, II and III and vertically; skeletal horizontal and steep planes of the mandible. The mean values of the sagittal and vertical dimensions of the maxilla and the mandible were determined and analyzed. Pearson's correlation coefficient was used to assess reliability. The one-way ANOVA test and the Tukey Post Hoc multiple comparison test were also used with a significant level at P <0.05. The results were also statistically compared to the previously reported homogeneous sample results using an independent t-test at P <0.05.*

Results*: The obtained results indicate high reliability of the intra-researcher, with a correlation coefficient in the range 0.00 - 1.00. A reference line based on the center of gravity enables the evaluation and statistical differentiation of sagittal and vertical interdental relationships in both heterogeneous and homogeneous specimens.*

Conclusions: *In conclusions, the results seem to confirm the usefulness or utility of the line (S&H centroid) in the cephalometric evaluation of the skeleton.*

Keywords: *Cephalometric evaluation of soft and hard tissues, heterogeneous sample.*

Corresponding author:

Dr. Asraa Naeem,

Dental Section Faisalabad Medical University Faisalabad.

QR code

Please cite this article in press Asraa Naeem et al, ***Cephalometric Soft And Hard Tissue Assessment With Central Reference Line In A Hetrogeneous Sample.,*** *Indo Am. J. P. Sci, 2020; 07(12).*

INTRODUCTION:

The introduction of the centroid into cephalometry was recorded almost fifty years ago.1 However, the technical determination of the centroid area of the entire anatomical cephalometric skull was difficult and impractical for orthodontists [1-2]. As a result, limited studies have been reported. Some studies have introduced the concept of centroids in cephalometry and pivotal studies. There have been very few clinical evaluation studies [3-4]. Such clinical studies have been modified and simplified determination center of gravity by presenting the actual cephalometric image of the skull and / or its elements of the main skull, maxilla and mandible into simple geometric shapes. Then the center of gravity for that geometric shape (s) was established [5-6]. However, with the general advancement of computer technology, a recent study introduced a new line of center of gravity for soft and hard tissues (S&H Centroid). The feasibility of such an S&H centerline was tested in a homogeneous Class I skeleton specimen with normal occlusion and a pleasant profile [7-8]. The Centroid-Seed (CN) reference line was created using the newly introduced S&H centroid line. Such a C-N reference line was found to be as useful or useful as the conventionally used S-N cephalometric plane in such a homogeneous sample [9]. The purpose of this study was to test the plausibility and usefulness of the cephalometric S&H midline in a larger heterogeneous sample consisting of bone; sagittal classes I, II and III, as well as vertical; steep and horizontal planes of the mandible.

MATERIALS AND METHODS:

This study was held in the Dental Section Allied Hospital, Faisalabad for six-months duration from February 2020 to July 2020. The sample consisted of seventy-eight 12 "x 14" side cephalometric images obtained from adults with the following criteria: - Adult with permanent dentition - Head in a natural head position, with lips resting - Heterogeneous sample with various sagittal malocclusions and vertical; (-40> ANB> 70 and 230> MP> 480) - No prior orthodontic treatment - No functional jaw displacement due to extensive restorations, severe tooth wear, ectopic tooth eruption and / or missing teeth. From these lateral cephalometric radiographs, the S&H center of gravity line was generated using a customized computer program (m file). A CN cephalometric reference line was created and compared to a conventionally used SN line run on its class I homogeneous skeleton sample. The reliability and suitability of the S&H cephalometric center of gravity in the present non-homogeneous sample was tested using a thorough examination method, variables and statistical tests, as well as using statistical independent t-test to statistically analyze the difference between the subtracted mean values of the two studies. A perpendicular line came from the Seed point (N) to the S&H centroid (Point C), creating a cephalometric N-C baseline. Sagittal measurements of the maxilla and mandible using the N-C baseline were established and compared with the measurements made using the conventional S-N cephalometric line (Fig. 1).

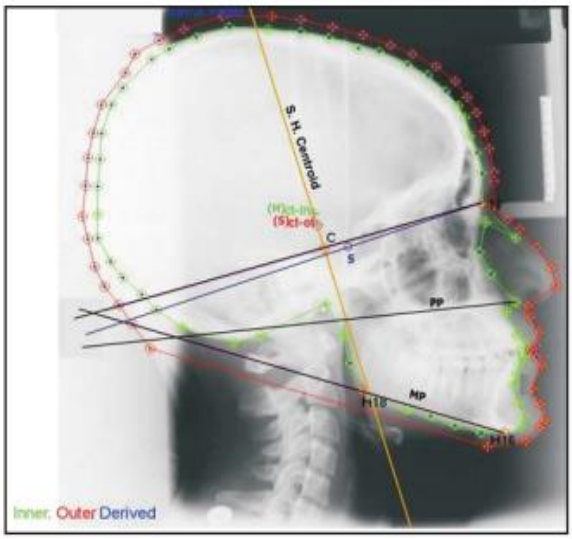

Fig 2: The centroid and conventional vertical variables

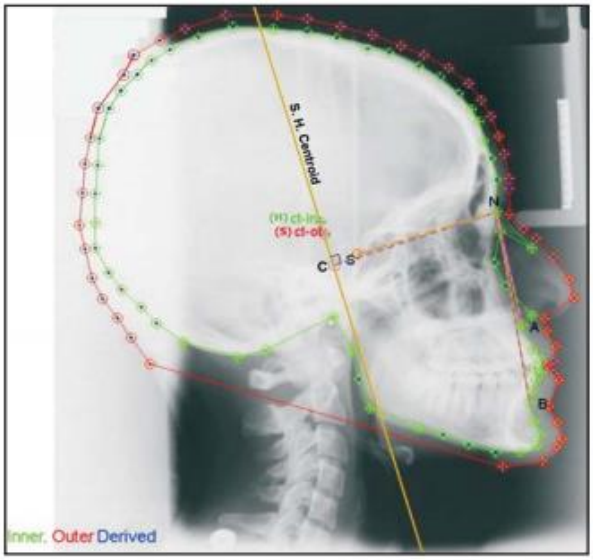

Fig 1: The centroid and conventional sagittal variables

Similarly, vertical measurements of the maxilla and mandible using the N-C baseline were established and compared with the measurements established by the conventional S-N baseline (Fig. 2). Measurements and standard deviations of the sagittal and vertical dimensions of the maxilla and mandible were calculated for the center of gravity (based on C-N) and conventional (based on S-N) cephalometric angles. Statistical compassion between the center of gravity and conventional angles was performed using one-way ANOVA and Tukey's post-Hoc multiple comparison test, with a significance set at P less than 0.05. The results of this study were also statistically compared an independent t-test with a P less than 0.05. Statistical analysis was performed using the SPSS 12 program (SPSS Inc., Chicago, Illinois, USA) for Windows.

RESULTS:

The obtained results indicated a high reliability of the intra-researcher with a correlation coefficient in the range of 0.99 - 1.00. The mean and standard deviation of the values based on C-N, conventional based on S-N and the subtracted values of the differences of the studied sagittal and vertical variables are presented (Table 1).

TABLE 1: MEAN AND STANDARD DEVIATION FOR THE VALUES OF THE SAGITTAL AND VERTICAL CENTROID AND CONVENTIONAL VARIABLES WITH THE SUBTRACTED DIFFERENCE

Centroid (C-N based) Analysis			**Conventional (S-N based) Analysis**			**Centroid (-) Conventional Subtracted Difference**		
Variable Analysis	**Mean**	**SD**	**Variable Analysis**	**Mean**	**SD**	**Variable**	**Mean**	**SD**
C-N-A	87.45	7.77	S-N-A	82.41	3.76	D-C-S-A	5.05	7.43
C-N-B	84.49	7.85	S-N-B	79.42	4.00	D-C-S-B	5.07	7.43
A-N-B	2.98	2.31	A-N-B	2.98	2.31	N/A	N/A	N/A
C-N/MP	27.96	5.40	S-N/MP	34.67	5.46	D-C-S/MP	-6.71	2.93
C-N/PP	3.15	7.83	S-N/PP	8.20	4.11	D-C-S/PP	-5.05	7.43
PP/MP	26.47	5.01	PP/MP	26.47	5.01	N/A	N/A	N/A

The one-way ANOVA and the Tukey post Hoc multiple comparison test showed a statistical difference between the four means subtracted in the sagittal and vertical planes.

TABLE 2: ONE WAY ANOVA TO COMPARE THE SAGITTAL AND VERTICAL SUBSTRACTED C-N AND S-N BASED ANGLES

(l) Group	**(J) Group**	**Mean Difference (I-J)**	**Std. Error**	**Sig.**
D-C-S-A	D-C-S-B	-.01736	1.00092	1.000
	D-C-S/MP	11.76023*	1.00092	.000
	D-C-S/PP	10.09598*	1.00092	.000
D-C-S-B	D-C-S-A	.01736	1.00092	1.000
	D-C-S/MP	11.77759*	1.00092	.000
	D-C-S/PP	10.11333*	1.00092	.000
D-C-S/MP	D-C-S-A	-11.76023*	1.00092	.000
	D-C-S-B	-11.77759*	1.00092	.000
	D-C-S-PP	-1.66425	1.00092	.345
D-C-S/PP	D-C-S-A	-10.09598*	1.00092	.000
	D-C-S-B	-10.11333*	1.00092	.000
	D-C-S-PP	-1.66425	1.00092	.345

The two sagittal variables differed statistically from the two vertical variables (P = 0.000) (Table 2). However, no statistical difference was found between the subtracted mean values for the sagittal and vertical group variables (P = 1.00 and P = 0.93, respectively (Table 3).

TABLE 3: TUKEY MULTIPLE COMPARISONPOST HOC TEST

Group	N	Subset for alpha - .05	
		1	2
D-C-S-A	87		5.0478
D-C-S-B	87		5.0652
D-C-S/MP	87	-6.7124	
D-C-S/PP	87	-5.0482	
Sig.		.345 NS	1.000 NS

There was also no statistical difference between the mean values of the examined subtracted differences - a heterogeneous sample from this study compared to the previously reported homogeneous sample (Table 4).

TABLE 4: MEAN AND STANDARD DEVIATION OF THE SUBSTRACTED DIFFERENCES OF THE HOMOGENOUS AND HETEROGENEOUS SAMPLES OF THE TWO STUDIES

Variables	Present Study Heterogeneous sample N = 87		Al-Dhahran Study Homogenous sample N = 57		Sig.
	Mean	SD	Mean	SD	
D-C-S-A	5.05	7.43	5.31	7.73	NS
D-C-S-B	5.07	7.43	5.34	7.73	NS
D-C-S/MP	-6.71	2.93	-6.09	2.80	NS
D-C-S/PP	-5.05	7.43	-5.32	7.73	NS

DISCUSSION:

As expected, the change in sample homogeneity did not affect the reliability of the digitization technique, the method used for cephalometric landmark identification and data collection. The reliability of the study was significantly high, which was consistent with other reports. C-N-based analysis and conventional S-N-based analysis have the same ability to evaluate and establish sagittal as well as vertical jaw relationship in a heterogeneous sample [8-10]. In Table 1-3, the results of the subtracted mean values associated with the sagittal and vertical variables in the current heterogeneous sample showed the same behavior, with the subtracted mean values from the homogeneous sample reported by Al-Shahrani[11]. The subtracted mean values for the sagittal variables were almost the same (5.05) and (5.07), and the subtracted mean values for the vertical variables were also almost similar (-6.71) and (-5.05). The statistically significant difference between the two groups - sagittal group variables vs vertical group variables - and no statistical difference between the values in each of the two individual groups - two variables in the sagittal group or two variables within the vertical group - indicate that the values of the sagittal and vertical variables can be considered constant, with the positive or negative sign representing the sagittal or vertical group, respectively[12]. Further research is recommended to support research into the applicability of the S&H centroid lineage. It may be interesting to study deviations or changes in the special inclination of the midline of the midsection and upper body for different sagittal relationships - class I, II, III - and vertical - horizontal, normal, vertical - skeletal. It may also be interesting to study the longitudinal stability or changes in the slope of the S&H midline from childhood to adulthood [13-14]. If the results of such future studies confirm the reliability of the S&H midline as the least variable of the non-anatomic cephalometric line and also confirm its suitability for the differentiation of different skeletal-facial growth patterns, then such a non-anatomic baseline can be considered a logical cephalometric reference line for the assessment of craniofacial growth. and / or malocclusion compared to the centroids described in the literature. [15] (1-6,18) However, currently such research is still limited; unavailability of customized software, cost and possible clinical unavailability of hardware tools, including large format (12 "x 14") film / cassette, and finally time-consuming digitization of numerous anatomical landmarks of soft and hard tissues.

CONCLUSION:

The homogeneity or heterogeneity of the sample did not affect the reliability of the method or the applicability of the "S&H centroid" line. The created C-N reference line using the S&H Centroid is able to

distinguish between sagittal and vertical maxillomandibular relationships.

REFERENCES:

1. Gaitan-Romero L, Shujaat S, Ma H, Orhan K, Shaheen E, Mulier D, Willems G, Politis C, Jacobs R. Evaluation of long-term hard tissue relapse following surgical–orthodontic treatment in skeletal class II patients: A systematic review and meta-analysis. International Journal of Oral and Maxillofacial Surgery. 2020 Oct 9.
2. Chen Z, Mo S, Fan X, You Y, Ye G, Zhou N. A meta-analysis and systematic review comparing the effectiveness of traditional and virtual surgical planning for orthognathic surgery: Based on randomized clinical trials. Journal of Oral and Maxillofacial Surgery. 2020 Sep 9.
3. Ferrer Colomar M. Evaluation of dental and skeletal effects of orthodontic functional appliances associated with skeletal maturation of cervical vertebrae in class II malocclusion. Universitat Internacional de Catalunya. 2020 Jun 19.
4. Liu Y, Yang ZJ, Zhou J, Xiong P, Wang Q, Yang Y, Hu Y, Hu JT. Soft Tissue Changes in Patients With Dentoalveolar Protrusion Treated With Maximum Anchorage: A Systematic Review and Meta-analysis. Journal of Evidence Based Dental Practice. 2019 Dec 1;19(4):101310.
5. Santana LG, Flores-Mir C, Iglesias-Linares A, Pithon MM, Marques LS. Influence of heritability on occlusal traits: a systematic review of studies in twins. Progress in orthodontics. 2020 Dec;21(1):1-1.
6. Kadam S, Murjani B, Ramaswami E, Nimma V, Bhosale R, Kausadikar P, Saju R. Prediction methods for soft tissue structures in forensic facial reconstruction: A review for reconstruction of nose, eyes, mouth and ears. INTERNATIONAL JOURNAL OF ETHICS, TRAUMA & VICTIMOLOGY. 2020 Aug 16;6(01):31-9.
7. Alam MK, Kajii TS, Sato Y, Iida J. Clinical investigation of congenital factor affecting craniofacial morphology of unilateral cleft lip and palate in Japanese patients. Pesquisa Brasileira em Odontopediatria e Clínica Integrada. 2019;19.
8. Kyburz KS, Eliades T, Papageorgiou SN. What effect does functional appliance treatment have on the temporomandibular joint? A systematic review with meta-analysis. Progress in orthodontics. 2019 Dec 1;20(1):32.
9. Sam A, Currie K, Oh H, Flores-Mir C, Lagravére-Vich M. Reliability of different three-dimensional cephalometric landmarks in cone-beam computed tomography: A systematic review. The Angle Orthodontist. 2019 Mar;89(2):317-32.
10. Agbolade O, Nazri A, Yaakob R, Ghani AA, Cheah YK. Morphometric approach to 3D soft-tissue craniofacial analysis and classification of ethnicity, sex, and age. Plos one. 2020 Apr 9;15(4):e0228402.
11. Ginart MT. *Assessment of palatal rugae in a multiethnic population* (Doctoral dissertation, University of Iowa).
12. Kobayashi Y, Ogura K, Hikita R, Tsuji M, Moriyama K. Craniofacial, oral, and cervical morphological characteristics in Japanese patients with Apert syndrome or Crouzon syndrome. European Journal of Orthodontics. 2020 Mar 7.
13. Salgado KR, Wendt AR, Fagundes NC, Maia LC, Normando D, Leão PB. Early or delayed palatoplasty in complete unilateral cleft lip and palate patients? A systematic review of the effects on maxillary growth. Journal of Cranio-Maxillofacial Surgery. 2019 Nov 1;47(11):1690-8.
14. Suppapinyaroj C, Lin CH, Lo LJ, Ko EC. Outcome of surgical-orthodontic treatment in hemifacial microsomia with and without early mandibular distraction osteogenesis. International Journal of Oral and Maxillofacial Surgery. 2020 Nov 17.
15. Tippashetty SK, Joshi S, Sajjan C, Konin P, Kumari S, Sajan RP. Determining the occlusal plane using hamular notch incisive papilla plane evaluator: An in vivo study. The Journal of Indian Prosthodontic Society. 2020 Jan 1;20(1):61.