



CODEN [USA]: IAJ PBB

ISSN: 2349-7750

**INDO AMERICAN JOURNAL OF
PHARMACEUTICAL SCIENCES**<http://doi.org/10.5281/zenodo.2579282>Available online at: <http://www.iajps.com>

Research Article

**ANALYSIS OF CLINICO PATHOLOGICAL FEATURES OF
HODGKIN LYMPHOMA IN PAKISTAN**¹Dr Muhammad Ali Hassan Khan, ²Dr Muhammad Imran,³Dr Syeda Wajeeha Bukhari¹Medical Officer at RHC Daira Din Panah, Muzaffargarh, ²Nishtar Hospital, Multan, ³Jinnah Hospital, Lahore**Abstract:**

Introduction: Hodgkin lymphoma (HL), formerly called Hodgkin's disease, arises from germinal center or post-germinal center B cells. HL has a unique cellular composition, containing a minority of neoplastic cells (Reed-Sternberg cells and their variants) in an inflammatory background. **Aims and objectives:** The main objective of the study is to analyze the clinico pathological features of classic and non-classic Hodgkin lymphoma in Pakistan. **Material and methods:** This study was conducted in Jinnah hospital, Lahore and Nishtar Hospital Multan during 2018 with the permission of ethical committee of hospital. This was basically a case study which was seen in Jinnah Hospital Lahore. There was a female in her 60s who presented with cervical lymphadenopathy associated with heavy infection with Epstein-Barr virus (EBV), diagnosed as Hodgkin lymphoma, mixed cellularity. During the staging workup, the patient was discovered to have extensive bone marrow (BM) involvement by Burkitt leukemia/lymphoma (BL). A diagnosis of concomitant EBV-related discordant lymphoma (cHL and BL) in leukemic phase was made. **Results:** Histopathological examination of the LN revealed subtotal effacement of the nodal tissue by a diffuse proliferation of lymphoid cells intermixed with scattered histiocytes, plasma cells, and eosinophils. There were many large atypical cells consistent with Hodgkin/Reed-Sternberg cells and mummified cells seen in the reactive background. As the patient's general condition had rapidly deteriorated and as a part of staging workup for HL, BM examination was performed. The BM aspirate smear unexpectedly showed infiltration with monotonous population of leukemic cells (~27%), medium size with regular round nuclei, dispersed nuclear chromatin, deeply basophilic cytoplasm with prominent vacuolation. **Conclusion:** It is concluded that correct diagnosis and appropriate treatment for composite CHL and B-NHL is highly important in patient's ≥ 40 years old. CHL must continue to be recognized because the disease subsets may have variable natural histories, prognosis, and different treatment modalities.

Key words: Hodgkin, Cells, Diseases, Patients.**Corresponding author:****Dr. Muhammad Ali Hassan Khan,**

Medical Officer at RHC Daira Din Panah, Muzaffargarh.

QR code



Please cite this article in press Muhammad Ali Hassan Khan et al., *Analysis Of Clinico Pathological Features Of Hodgkin Lymphoma In Pakistan.*, Indo Am. J. P. Sci, 2019; 06(02).

INTRODUCTION:

Hodgkin lymphoma (HL), formerly called Hodgkin's disease, arises from germinal center or post-germinal center B cells. HL has a unique cellular composition, containing a minority of neoplastic cells (Reed-Sternberg cells and their variants) in an inflammatory background. It is separated from the other B cell lymphomas based on its unique clinic-pathologic features, and can be divided into two major subgroups, based on the appearance and immuno phenotype of the tumor cells [1].

Of all Hodgkin lymphomas (HL), classical Hodgkin lymphoma (CHL) accounts for ~95% of all cases, whereas the remaining 5% comprises nodular lymphocyte predominant Hodgkin lymphoma. CHL shows a peak incidence at 15–35 years, and a second peak in elderly patients. Epstein–Barr virus (EBV) has been postulated to play a role in the pathogenesis and the outcome of CHL [2]. The reported incidence of EBV positivity in CHL cases varies: 31% (≥ 50 years old) (3) and 34% (≥ 60 years old) in two European studies, but up to 100% in tropical regions. In particular, EBV is frequently found in mixed cellularity and lymphocyte depleted subtypes [3]. The prognostic significance of EBV-association on OS in CHL cases is controversial. However, there have been several reports suggesting unfavorable OS in elderly patients with EBV-positive CHL compared with that of patients with EBV-negative CHL [4]. Hodgkin's lymphoma (HL) is a lymphoid tumor representing less than 1% of all *de novo* neoplasms occurring every year worldwide. Its diagnosis is based on the identification of characteristic multinucleated giant cells within an inflammatory milieu. These cells termed Reed-Sternberg (RS) or diagnostic cells represent the body of the tumor; they measure 20–60 μm in diameter and display a large rim of cytoplasm and at least two nuclei with acidophilic or amphophilic nucleoli, covering more than 50% of the nuclear area [5].

The tumoral population also includes a variable number of mononuclear elements, Hodgkin's cells (HCs) showing similar cytological features to RS cells and neoplastic cell variants, each corresponding to a specific subtype of HL. Molecular studies have only recently shown that in most if not all cases RS cells,

Hodgkin's cells, and cell variants belong to the same clonal population, which is derived from peripheral B cell [6].

Aims and objectives

The main objective of the study is to analyze the clinico pathological features of classic and non-classic Hodgkin lymphoma in Pakistan.

MATERIAL AND METHODS:

This study was conducted in Jinnah hospital, Lahore and Nishtar Hospital Multan during 2018 with the permission of ethical committee of hospital. This was basically a case study which was seen in Jinnah Hospital Lahore. There was a female in her 60s who presented with cervical lymphadenopathy associated with heavy infection with Epstein-Barr virus (EBV), diagnosed as Hodgkin lymphoma, mixed cellularity. During the staging workup, the patient was discovered to have extensive bone marrow (BM) involvement by Burkitt leukemia/lymphoma (BL). A diagnosis of concomitant EBV-related discordant lymphoma (cHL and BL) in leukemic phase was made.

She presented with a seven-month history of right-sided neck swelling, weight loss, and night sweating. On initial physical examination, the patient had hepatosplenomegaly and right cervical lymphadenopathy for which an excisional lymph node (LN) biopsy was performed and a diagnosis of Hodgkin lymphoma, mixed cellularity type III, was confirmed.

RESULTS:

Histopathological examination of the LN revealed subtotal effacement of the nodal tissue by a diffuse proliferation of lymphoid cells intermixed with scattered histiocytes, plasma cells, and eosinophils. There were many large atypical cells consistent with Hodgkin/Reed–Sternberg cells and mummified cells seen in the reactive background. As the patient's general condition had rapidly deteriorated and as a part of staging workup for HL, BM examination was performed. The BM aspirate smear unexpectedly showed infiltration with monotonous population of leukemic cells (~27%), medium size with regular round nuclei, dispersed nuclear chromatin, deeply basophilic cytoplasm with prominent vacuolation.

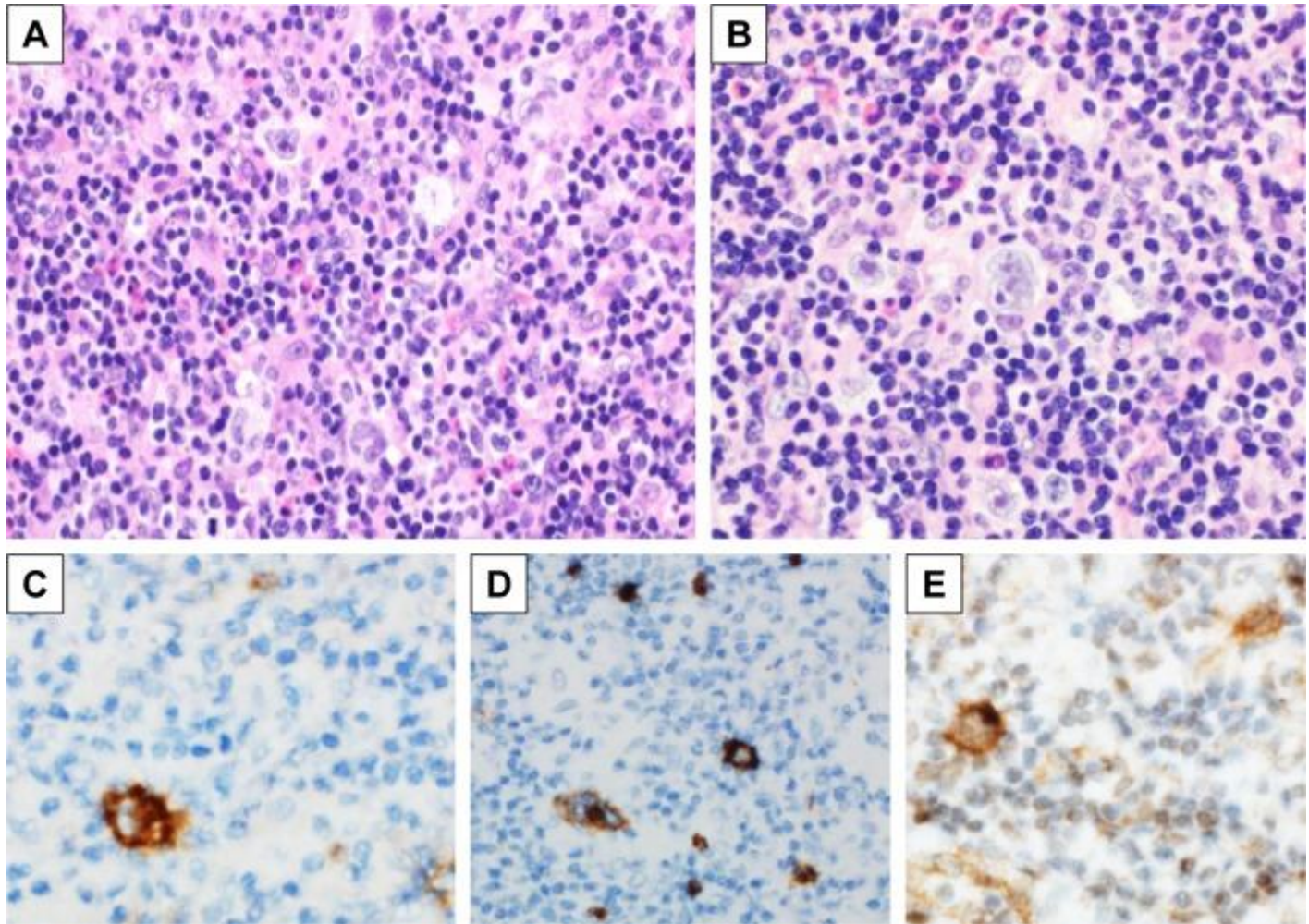


Figure 1: Histological examination. (A & B) Hodgkin/Reed-Sternberg cells seen in a reactive background of a lymph node tissue (H&E $\times 40$). (C & D) Immunohistochemical study demonstrates that Reed-Sternberg cells are positive for CD30 and CD15. (E) Reed-Sternberg cells are positive for EBV (LMP-1).

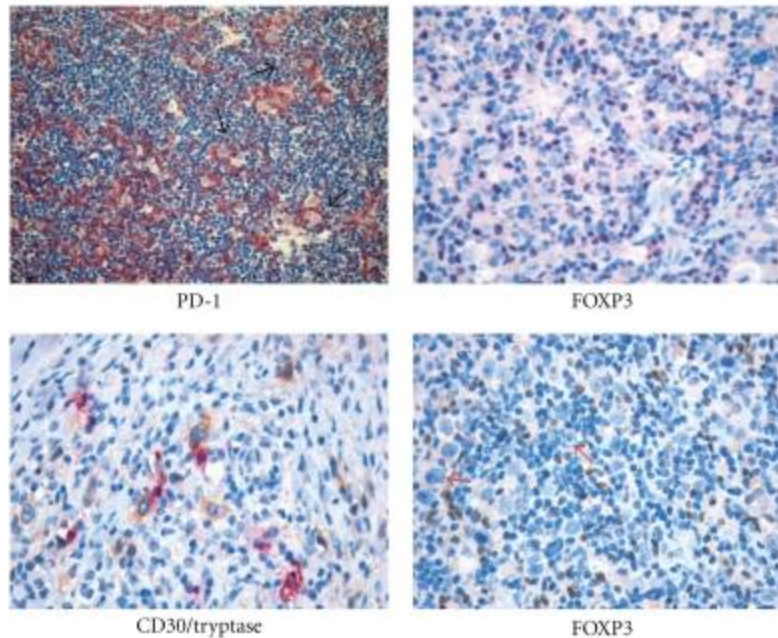


Figure 02: The reactive “milieu” in Hodgkin lymphoma. Mast cells and regulatory T cells populate the HL microenvironment showing spatial interaction with RS cells.

DISCUSSION:

Most of clinically reported CLs are actually sequential lymphomas in which two different histological types of lymphoma occur in the same group of LNs after successful treatment of the first lymphoma. In these instances, the development of the second lymphoma might have been a coincidental occurrence or secondary to cytotoxic therapy received for treatment of the first lymphoma [7]. Discordant lymphoma is another rare condition in which different types of malignant lymphomas occur in different anatomic sites. The two diseases may present clinically as concurrent or sequential disease [8].

The concept of CL was first proposed by Custer to denote the occurrence of more than one histological type of lymphoma in a single patient. The concept of CL is now restricted by some authors to the rare occurrence of two or more morphologically and immunophenotypically distinct lymphoma clones in a single anatomical site, ie, within a single organ or tissue [9].

In most instances (11 of 18 informative cases), the cHL and the NHL were clonally related. The reported NHL that was found to be clonally related to cHL included follicular lymphoma, mantle cell lymphoma, diffuse large cell lymphoma, and chronic lymphocytic leukemia [10]. In eight of 18 combinations of a HL and a NHL that were diagnosed consecutively, the

lymphomas were clonally unrelated [11]. In spite of the relatively long history of LN enlargement, the possibility that BL could represent a transformation of HL is very remote, since cHL does not have a tendency to transform into more aggressive subtypes unlike NLPHL, which has a tendency to transform into a high-grade lymphoma [12].

CONCLUSION:

It is concluded that correct diagnosis and appropriate treatment for composite CHL and B-NHL is highly important in patient's ≥ 40 years old. CHL must continue to be recognized because the disease subsets may have variable natural histories, prognosis, and different treatment modalities.

REFERENCES:

1. Kerl K, Girardet C, Borisch B. A common B-cell precursor in composite lymphomas. *N Engl J Med.* 1999;341:764–765.
2. Yoshinaga H, Ohashi K, Yamamoto K, et al. Clonal identification of Burkitt's lymphoma arising from lymphocyte-predominant Hodgkin's disease. *Br J Haematol.* 1996;95(2):380–382.
3. Kotila TR, Aken'ova YA, Shokunbi WA, Akingbola TS, Fasola FA. Hodgkin's disease after treatment for Burkitt's lymphoma: case report. *East Afr Med J.* 2001;78:6.
4. Chapman A, Rickinson A. Epstein-Barr virus in Hodgkin's disease. *Ann Oncol.* 1998;9:S5–S16.

5. Jarrett R, Gallagher A, Jones D, et al. Detection of EBV genomes in Hodgkin's disease: relation to age. *J Clin Pathol (Lond)* 1991;44:844–848.
6. Razzouk B, Gan Y, Mendonca C, et al. Epstein-Barr virus in pediatric Hodgkin's disease: age and histiotype are more predictive than geographic location. *Med Pediatr Oncol.* 1997;28:248–254.
7. Miettinen M, Franssila KO, Saxen E. Hodgkin's disease, lymphocytic predominance nodular. Increased risk for subsequent non-Hodgkin's lymphomas. *Cancer.* 1983;51:2293–2300.
8. Mokhtar N, Gouda I, Adel I. *Cancer Pathology Registry Book (2003–2004) and Time Trend Analysis.* 1st ed. Cairo: NCI, Cairo University; 2007.
9. Tinguely M, Vonlanthen R, Müller E, et al. Hodgkin's disease-like lymphoproliferative disorders in patients with different underlying immunodeficiency states. *Mod Pathol* 1998; 11:307.
10. Glaser SL, Clarke CA, Gulley ML, et al. Population-based patterns of human immunodeficiency virus-related Hodgkin lymphoma in the Greater San Francisco Bay Area, 1988-1998. *Cancer* 2003; 98:300.
11. Garnier JL, Lebranchu Y, Dantal J, et al. Hodgkin's disease after transplantation. *Transplantation* 1996; 61:71.
12. Patel P, Hanson DL, Sullivan PS, et al. Incidence of types of cancer among HIV-infected persons compared with the general population in the United States, 1992-2003. *Ann Intern Med* 2008; 148:728.