CODEN [USA]: IAJPBB ISSN: 2349-7750

INDO AMERICAN JOURNAL OF
PHARMACEUTICAL SCIENCES

http://doi.org/10.5281/zenodo.3709613

Available online at: http://www.iajps.com Research Article

# AN ASSESSMENT OF POST-OPERATIVE CAVITY COMPLICATIONS IN PATIENTS UNDERGOING OPEN CAVITY MASTOIDECTOMY

**[1]Dr. Muhammad Yousaf Saleemi, [2]Dr. Muhammad Younas, [3] Sana Sajid**

[1]Associate Professor, Department of Otorhinolaryngology, Head & Neck Surgery,DHQ Teaching Hospital Sahiwal

[2]Assistant Professor, Department of Otorhinolaryngology, Head & Neck Surgery, Quaid-e-Azam Medical College/BVH, Bahawalpur

[3]Ex-House Officer, Nishter Hospital, Multan

**Article Received:** December 2019 **Accepted:** January 2020 **Published:** February 2020

**Abstract:**

***Objective:*** *To assess the post-operative cavity complications in patients undergoing open cavity mastoidectomy.*

***Material and methods:***

***METHODS:*** *This cross-sectional study was at Department of Otorhinolaryngology, Head & Neck Surgery DHQ Hospital, Sahiwal from January March 2019 to September 2019 over the period of six months.*

*Total 78 patients having age 1-60 years either male or female undergone open cavity mastoidectomy were selected for this study. Post-operative complications were assessed.*

***Results:*** *Total 78 patients were selected for this study. Postoperative cavity problems were seen in 27% patients. Total 6 (29%) patients belonged to age group 21-40 years followed by 7 (33%) patients to age group 21-40 years and 8 (38%) patients to age group 41-60 years. Of the 78 cases, 59 (75.64%) had sclerotic mastoid and 10 (12.82%) had cellular mastoid and 9 (11.53%) had diploeic mastoid. out of the 21 postoperative mastoid cavity problems, 5 cases had large postoperative cavity, 18 cases had high facial ridge, 1 case had stenosis of meatoplasty, 17 cases had exposed middle ear and eustachian tube and 17 had postoperative granulations.*

***Conclusions:*** *Results of present study showed that post mastoidectomy cavity problems were seen in 27% patients. Most of the patients with complication were belonged to age group 41-60 years. Cavity problems were seen slightly more in sclerotic mastoids.*

***Keywords:*** *Open mastoidectomy, Granulations, Meatoplasty, Pneumatisation, Cholesteatoma*

**Corresponding author:**

**Dr. Muhammad Yousaf Saleemi,**

*Associate Professor, Department of Otorhinolaryngology, Head & Neck Surgery, DHQ Teaching Hospital Sahiwal*

QR code

*Please cite this article in press Muhammad Yousaf Saleemi,* ***An Assessment Of Post-Operative Cavity Complications In Patients Undergoing Open Cavity Mastoidectomy.,*** *Indo Am. J. P. Sci, 2020; 07(02).*

## INTRODUCTION:

The main aims of surgical treatment of chronic middle ear suppuration are elimination of disease process, reconstruction of hearing mechanism and prevention of complications. This requires excision, exenteration and often exteriorisation of the disease process in the middle ear and mastoid. Controversy still exists among otolaryngologists regarding the need for exteriorisation of mastoid.[1] If the mastoid is exteriorised by taking down the posterior bony external canal wall, then an open cavity mastoidectomy is established. Avoidance of this step results in a canal wall up mastoidectomy. Supporters of open cavity mastoidectomy stress upon the future monitoring of the disease process, because even if some of the disease were left in the open cavity, that can be extruded spontaneously or can be removed during the subsequent visits.[2,3] Hence this is the surgery of choice in patients where the surgeon is not sure of the follow up status. Canal wall down technique also ensures good ventilation of cavity which has a drying effect.[4] Finally canal wall up technique needs surgical expertise for complete removal of diseased portion for avoidance of surgical complications. Usually an open mastoid cavity heals by secondary intention.[5,6] The average time for complete healing of this cavity varies according to various authors. Failure of healing and complete epithelialisation of this open cavity leads to cavity problems including continued discharge from the cavity, impaction of wax, persistent vertigo, residual/recurrent disease, and brain fungus.[7] So, the rationale behind the study as there was lacunae in literature in the current scenario this study was planned to analyse the cavity problems post mastoidectomy.

## MATERIAL AND METHODS:

This cross sectional study was at Department of Otorhinolaryngology, Head & Neck Surgery DHQ Hospital, Sahiwal from January March 2019 to September 2019 over the period of six months.

Total 78 patients having age 1-60 years either male or female undergone open cavity mastoidectomy were selected for this study. Patients with any systemic disease, having age >60 years were exclude from the study. Study was approved by ethical committee and written informed consent was taken from every patient. Base line investigation was done and demographic profile of all the patients were entered in pre-designed proforma. Open cavity mastoidectomy was performed in selected. They were assessed primarily by their complaints and then by cavity examination. Each patient had a follow up upto three months at twice weekly intervals. In this study a borderline healing period of three months (12 weeks) was given for the complete epithelialisation of an open mastoid cavity. So, any patient presenting with symptoms beyond this period was taken as a cavity problem case. The cases were studied according to the clinical symptoms. Basic clinical examinations were done. For each case, any of the proven predisposing factors, was determined by cavity examination. When required, investigations like culture and sensitivity of pus was done. Measurement of parameters like facial ridge height, size of cavity and size of meatoplasty were adopted from standard studies conducted by other authors. In this study 5 cc is taken as the volume of a large mastoid cavity, 3-5 cc, small less than 3 cc, appropriate medical treatments like topical/systemic antibiotics, aural toilet, steroids and cauterisation were given. Chemical cauterisations of granulations were attempted as an outpatient basis. Patients were followed up at intervals of 2 weeks after the treatment to assess the progress. Some cases were admitted in the ward for protracted symptoms and they were given parenteral medication. Rarely cases required surgical management.

All the collected was entered in SPSS version 18 and analyzed. Mean and SD was calculated for numerical data. Frequencies were calculated for categorical data.

## RESULTS:

Out of 78 patients who undergone open cavity mastoidectomy, post mastoidectomy cavity problems were seen in 21 (27%) patients. (Fig. 1) Patients of post-operative cavity problems were divided into three age groups i.e. age 1-20years, age group 21-40 years and age group 41-60 years. Total 6 (29%) patients belonged to age group 21-40 years followed by 7 (33%) patients to age group 21-40 years and 8 (38%) patients to age group 41-60 years. (Fig. 2)

Of the 78 cases, 59 (75.64%) had sclerotic mastoid and 10 (12.82%) had cellular mastoid and 9 (11.53%) had diploeic mastoid. Of the 59 sclerotic mastoids, 16 (27.11%) had post mastoidectomy cavity problems. Of the 9 diploeic mastoid, 4 (44.44%) had postoperative cavity problems and of the 10 cellular mastoids, 1 (10%) had postoperative cavity problems. i.e., Of the 21 patients with cavity problems, 76.19% were of sclerotic mastoid and 4.76% were of cellular mastoid and19.04% were of diploeic mastoid. 26 surgeries were done under general anaesthesia. All the 78 patients underwent modified radical mastoidectomy. (Table 1)

Of the 21 problem cavities, 20 had prolonged discharge from mastoid cavity as the main problem (95.23%). Accumulation of wax in the cavity was present in 6 cases (28.57%). Vertigo persisting beyond the immediate postoperative period was present in 4 cases (19.04%). Perichondritis of pinna was found in 1 case (4.76%). Persistence

or/development of facial palsy in post-operative period was found in 5 cases (23.80%) and recurrent cholesteatoma was seen only in 3 cases (14.28%). 2 Cases had postoperative wound infection (9.52%). (Table 2)

According to Table 3, of the 78 cases, 8 cases had a large post-operative cavity. Hence out of the 21 postoperative mastoid cavity problems, 5 cases had large postoperative cavity, 18 cases had high facial ridge, 1 case had stenosis of meatoplasty, 17 cases had exposed middle ear and eustachian tube and 17 had postoperative granulations. Treatment given includes aural toilet, topical and systemic antibiotics, steroids and cauterisation.

**Fig. 1: Frequency of postoperative cavity problems**

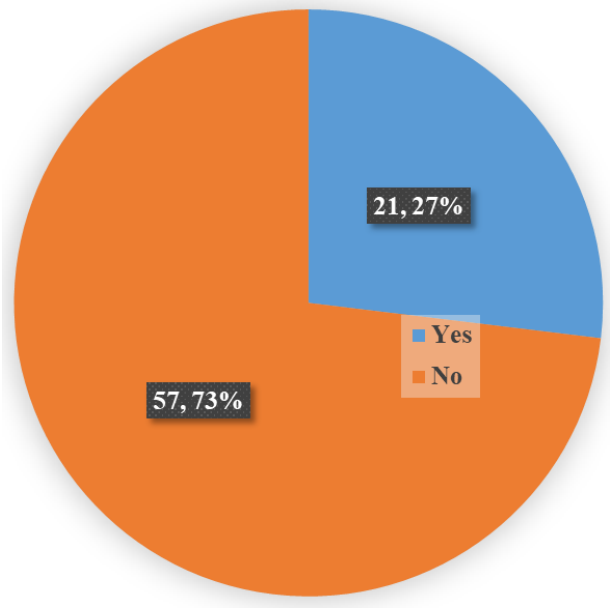


**Fig. 2: Age wise distribution (N=21)**

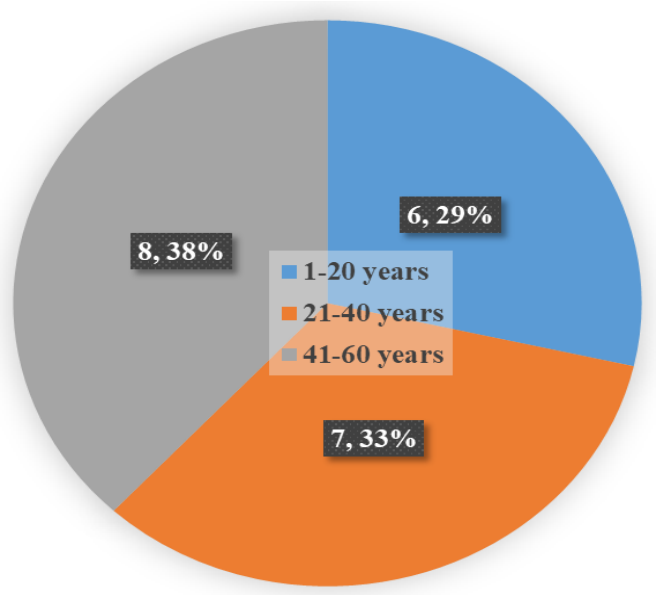

**Table 1: Pneumatisation of mastoid, type of surgery and type of anesthesia during the procedure.**

| Mastoid Pneumatisation | No. of Cases | Cases with cavity problem | % |
|---|---|---|---|
| **Sclerotic** | 59 | 16 | 27.11 |
| **Cellular** | 10 | 1 | 10 |
| **Diploeic** | 9 | 4 | 44.44 |

**Table 2: Post-operative problems. (N =21)**

| Cavity problems | % |
|---|---|
| **Discharge** | 95.23 |
| **Wax** | 28.57 |
| **Vertigo** | 19.04 |
| **Perichondritis** | 4.76 |
| **Facial palsy** | 23.80 |
| **Recurrent cholesteatoma** | 14.28 |
| **Post-operative wound infection** | 9.52 |

**Table 3: Post-operative analysis.**

| Post-operative analysis | Number |
|---|---|
| **Larger cavity** | 5 |
| **High facial ridge** | 18 |
| **Meatoplasty sterosis** | 1 |
| **Exposed middle ear and eustachian tube** | 17 |
| **Post-operative granuloma** | 17 |

## DISCUSSION:

In the present study 21 patients had post-operative mastoid cavity problems. Hence 26.92% of the total had cavity problems, according to this study. Sade et al had 28% post mastoidectomy cavity problems and Kos et al had 30% cavity problems.[8,9] Khan et al had 26.6% problem mastoid cavities.[10] Hence, this study has almost comparable incidence of cavity problems to previous studies.[10] Patients of post-operative cavity problems were divided into three age groups i.e. age 1-20years, age group 21-40 years and age group 41-60 years. Total 6 (29%) patients belonged to age group 21-40 years followed by 7 (33%) patients to age group 21-40 years and 8 (38%) patients to age group 41-60 years. Vaid et al got the same findings in their study.[11] But Vartianen had different observations. Vartianen had maximum incidence between 20 and 30 years.[12] 23% of patients with high facial ridge had cavity problems. In the study conducted by Sade et al this was 80%.[8] Almost same value was obtained by Vaid et.al also.[11] This finding points to the need of lowering the facial ridge upto the level of floor of external auditory canal. On doing so adequate care should be taken to avoid injury to facial nerve, especially in cellular mastoids, where one can expect extensive pneumatisation onto the perifacial and retrofacial cell tracts with a deep mastoid tip. Exposed middle ear and eustachian tube areas were found to be a significant factor causing postoperative discharge from the cavity. This was proven by all the previous studies conducted by Sade et al and Castrellion et al, only 18.18% grafted cases had cavity problems whereas 30.35% cases had cavity problems when grafting was not done.[8,13] Meatoplasty stenosis was found only in 3.84% cases. According to Sade et al, only 30% of their patients with meatoplasty stenosis attained dry cavity.[8] Vartianen et al had 27.8% cases of meatoplasty stenosis.[12]

## CONCLUSION:

Results of present study showed that post mastoidectomy cavity problems were seen in 27% patients. Most of the patients with complication were belonged to age group 41-60 years. Cavity problems were seen slightly more in sclerotic mastoids.

## REFERENCES:

1. Vikram BK, Khaja N, Udayashankar SG, Venkatesha BK, Manjunath D. Clinicoepidemiological study of complicated

and uncomplicated chronic suppurative otitis media. J Laryngol Otol. 2014;122:442-6.
2. Parry D, Meyers AD (eds). Middle ear chronic suppurative otitis, medical treatment. 2011. Available at: emedicine.medscape.com/article/859501-treatment. Accessed on 12th June 2019.
3. Woodfield G. Dugdale A. Evidence behind the WHO guidelines: hospital care for children: what is the most effective antibiotic regime for chronic suppurative otitis media in children. J Trop Pediatr. 2013;54:151-6.
4. Matsuda Y, Kurita T, Ueda Y, Ito S, Nakashima T. Effects of tympanic membrane perforation on middle-ear sound transmission. J Laryngol Otol. 2014;123(Suppl 31):81-9.
5. Wright D, Safranek S. Treatment of otitis media with perforated tympanic membrane Am Fam Physician. 2009;79:650-4.
6. van der Veen EL, Schilder AGM, van Heerbeek N, Verhoeff M, Zielhuis GA, Rovers MM. Predictors of chronic suppurative otitis media in children. Arch Otolaryngol Head Neck Surg. 2011;132:1115-8.
7. Smith JA, Danner CJ. Complications of chronic otitis media and cholesteatoma. Otolarygol Clin North Am. 2010;39:1237-55.
8. Sade J. Treatment of retraction pockets and cholesteatoma. J Laryngol Otol. 1982;96:685-704.
9. Kos MI, Castrillon R, Montandon P, Guyot JP. Anatomic and functional long-term results of canal wall –down mastoidectomy. Ann Otol Rhinol Laryngol. 2004;113:872-6.
10. Khan AA, Manzoor T, Shah AA, Ayub Z. Evaluation of mastoid cavities after canal wall down mastoidectomy. Pak Armed Forces Med J. 2009;59:295-7.
11. Vaid L, Gupta M, Singh PP. Mastoid obliteration in management of chronically discharging ear. Indian J Otol. 2002;8:47–56.
12. Vartianen E. Ten-year results of canal wall down mastoidectomy for acquired choesteatoma. Auris Nasus Larynx. 2001;27:227-9.
13. Castrillion R, Kos I, Montandon P, Guyot JP. Longterm results of canal wall down mastoidectomy. Schweiz Med Wochenschr. 2000;125(Suppl):58S- 65S.