CODEN [USA]: IAJPBB ISSN: 2349-7750

INDO AMERICAN JOURNAL OF
PHARMACEUTICAL SCIENCES

http://doi.org/10.5281/zenodo.2547789

Available online at: http://www.iajps.com ***Research Article***

INTRAMEDULLARY NAILING OF FEMORAL AND TIBIAL SHAFT FRACTURE, A CROSS SECTIONAL STUDY, KSA

[1]Abdullah Mohammad ALhalafi, [2]Haitham Sulaiman Habtar, [3]Mohammed Izzuldeen Alshehri, [4]Abdulrhman Ali Hassan, [5]Arwa Modawi Mohammed Asiri , [6]Shaher Musa Albakheet, [7]Nawa Fahad S Alshahrani, [8]Mohammed Bahkali Ali Altherwi, [9]Sameera Ali Othman Hakami.

[1]King Khalid University, Amh120@hotmail.co.uk, [2]King Khalid University, dr.h.habtar@gmail.com, , [3]King Khalid University, m7md.3ez@gmail.com, [4]King Khalid University, Alm3med@gmail.com, [5]King Khalid University, arwal12@hotmail.com, [6]King khalid university, ishaheri@me.com,[7]King Khalid University, nawa201059@hotmail.com, [8]Jazan university, imeedo77@gmail.com, [9]Jazan university, Samorhak@gmail.com.

Abstract:

Background: *A Cross-Sectional study done in King Abdulaziz National Guard Hospital in the department of Orthopedic. intramedullary nailing is a safer and famous surgical method. An original extension-apparatus has been developed, and the shape of the intramedullary nail and operative techniques has also been improved.*

Materials & Methods: *A long-term experiment of the closed intramedullary nailing from July 2017 to August 2018 was done on 122 fractures, including 46 femur fractures for 85 patients and 76 tibia fractures for 98 patients. All patients were scheduled to have locked intramedullary nailing of fractures except those that were adjudged unsuitable. The locked intramedullary nailing systems used for the stabilization of the fractures were Russel Taylor, Pitkar, and Nebular systems. The alternate systems used were the conventional Kuntscher nailing and dynamic compression plate fixation. Antegrade closed intramedullary nailing, and in some cases with minimal opening at the fracture site to achieve reduction, were used. The medullary canals were reamed in all the cases and two screws were inserted to achieve proximal and distal locking in those stabilized with locked intramedullary nail. Parameters with regard to intraoperative blood loss, postoperative wound infection, length of hospital stay, and fracture union were followed up.*

Results*: Currently of the fractures of the tibial shaft, x-ray tool continuity in fractured bone by callus, i.e. the cloudy shadow of callus filling the fragments, appeared in 33.6 days (average), and the bony closure, the mature spaced callus connecting the parts, was completed in 60.2 days (average). For fractures of the femoral shaft, the former appeared in 22 days and the latter was completed in 30 days.*

Keywords: *Fracture, Femur, Tibia, Intramedullary nailing, various methods.*

Corresponding author:

Abdullah Mohammad ALhalafi,

King Khalid University, Amh120@hotmail.co.uk

QR code

.

Please cite this article in press Abdullah Mohammad ALhalafi et al., ***Intramedullary Nailing Of Femoral And Tibial Shaft Fracture, A Cross Sectional Study, Ksa.,*** *Indo Am. J. P. Sci, 2019; 06(01).*

INTRODUCTION:

In the history of fracture care, the decade of the 1980s will be remembered for the expanded role that intramedullary nailing has played in the treatment of femoral and tibia1 fractures. While intramedullary nails have been utilized for nearly, 50years, the recent introduction of interlocking nail techniques has greatly expanded their role in treatment of more complex fracture patterns. Shortening and mal-rotation, which was common with previous nail designs have been virtually, eliminated with locked intramedullary nails. In the operative treatment of fractures, the race between fracture healing and implant failure has always been a challenge to the orthopaedic surgeon. Particularly in the weight-bearing long bones of the lower extremity. The load-sharing intramedullary nails offer distinct advantages over load-bearing plates for diaphyseal fractures of the femur and tibia.

There are several features that make intramedullary nailing an attractive treatment method. These include a closed technique, which decreases blood loss while preserving the surrounding soft-tissue envelope. This significantly decreases the risk of contamination at the fracture site. Cosmesis is improved by eliminating unsightly incisions in the thigh. Following nailing of closed fractures the incidence of non-union and infection is less than 2 %. The technique allows early patient mobilization and weight bearing, reducing hospital stay. Another benefit of intramedullary nailing is the low rate of refracture following implant removal.' i

Locked intramedullary nailing for the operative stabilization of femoral and tibial shaft fractures has become the gold standard in the management of these fractures. The recognition of absolute respect for soft tissues in the operative management of fractures to achieve biological fixation heralded the era of locked intramedullary nailing. Locked intramedullary nailing is usually achieved via closed reduction of fracture and stabilization by insertion of intramedullary nails followed by proximal and distal locking under image intensification. Sometimes fracture reduction may require minimal opening. Other less desirable methods of operative stabilization of these fractures include the use of unlocked intramedullary nails and plates. The use of locked intramedullary nails has advantages in that it is associated with higher fracture union rates in over 97% of the cases. It results in lower tensile and shear stresses on the implant than plate fixation, lower infection rates, and less extensive exposure and dissection during insertion. Locked intramedullary nailing has the advantage of preserving periosteal blood supply and controls alignment, translation, and rotation after fracture stabilization. Locking of the nail allows for restoration of length and early functional use of the extremity, thereby reducing the length of hospital stay and facilitating early return to work. Plate fixation for the operative management of tibial and femoral shaft fractures is less desirable. It is associated with additional soft tissue injury during exposure, reduced vascularity beneath the plate, increased blood loss, stress shielding of the bone, and increased risk of infection.

Locked intramedullary nailing for the operative fixation of tibial and femoral shaft fractures has become generally acceptable in the management of these fractures in Nigeria. The last decade has witnessed considerable development with regard to this procedure and the availability of both instrumentation and implants in various centers. The results of these procedures from various centers have been quiet impressive and compares to that obtained globally.

The sustenance of these important procedures are, however, not without challenges which is the main reason for reporting the experience from our hospital.

Accordingly the Intramedullary nailing tools to shaft fractures of the long tubular bone is a surgery with its technical goodness in the diameter of the intramedullary nail and medullary canal, explaining the closed method without the exhibiting of the fractured site, and with elastic impingement among the intramedullary nail and the medullary canal.

However, The author advised to enhance the extension to improve the intramedullary nail and the details of operative techniques in order to establish this closed intramedullary nailing as a safe and widely good operation. Recent clinical applications have shown excellent results.

MATERIALS & METHODS:

A Cross-Sectional study done in King Abdulaziz National Guard Hospital in the department of Orthopedic under consultant supervision

A long-term experiment of the closed intramedullary nailing from July, 2017 to August , 2018 was done on 122 fractures, including 46 femur fractures for 85 patients and 76 tibia fractures for 98 patients. Establishment of the extension-apparatus (traction table)) The extension-apparatus, as well as fluoroscopy and the flexible reamer, is stronger to

closed intramedullary nailing.

Outline of Femur Fractures

Explaining a few bilateral patients, there were 44 males and 9 females aged 15 to 75 (average age 34), of which 34 cases were caused by traffic accidents, 18 cases by labor accidents, 2 cases by sports accidents, 5 cases by a fall, one case by pathological fracture, and 4 cases by miscellaneous reasons. Seventy cases were closed fractures, 9 (8%) were open fractures, 4 were cases of non-union, and one of mal-union.

Outline of Tibia Fractures

There were many accidents, 12 by sports accidents, 7 by a fall, and 8 cases by other reasons. forty-nine cases were closed fractures, 20 (20%) were open fractures, 6 were cases of non-union and one of mal-union. The fractured sites and types are shown below.

As shown in figure below, the intramedullary nails used most often were 14 mm in diameter and 380 mm in length for femur fractures, and 12 mm in diameter, 300 mm in length for tibia fractures. Fat embolism disease was occured in 5 cases. 21 % of the femur fractures and 44% of the tibia fractures stayed free from associated injuries.

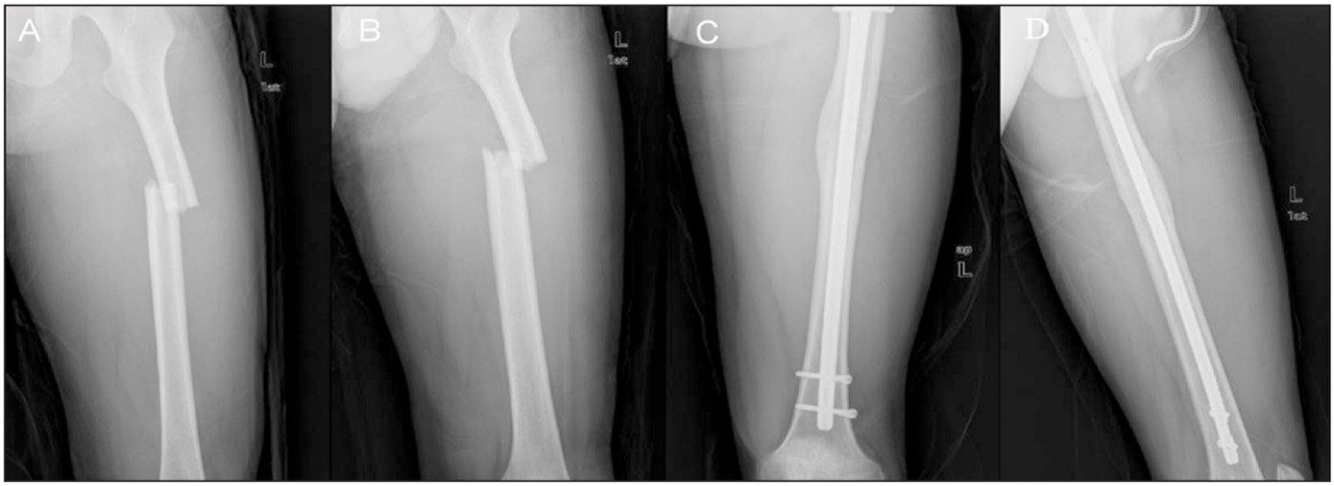

The surgery of unclosed fractures is done after the lesion is healed. In tibial fractures, the average period from the time of injury to the operation was 7 days for closed fractures and 11 days for open fractures. In fresh femur fractures, the period averaged II days for closed fractures and 15 days for open fractures, with 42 days as the longest period. The operation time from incision to would closure was an average of 66 min. (ranging from 30 to 180 min.) for femur fractures and an average of 50 min. (ranging from 20 to 120 min.) for tibial fractures.

RESULTS:

With regards to fractures of the tibial shaft, x-ray images in fractured bone by callus, i.e., the cloudy shadow of callus filling the pieces, appeared in 22.4 days (average), and bony closure, the mature linking callus connecting the parts, was completed in 75.2 days (average). For fractures of the femoral shaft, the former appeared in 59 days and the latter was completed in 50 days. In sixty-eight stable cases (20% of all) partial weight bearing was possible within 4.8 days (average) for fractures of the femoral shaft in comparison to 6.1 days (average) for fractures of the tibial shaft. Full weight bearing was possible in one month for 64 both.) reported the same reslults in femoral fractures and Alms) reported 8 weeks in tibial fractures. No additional plating, screw fixation wiring was done during the operations except in 2 femur fracture cases to which stacked nailing.

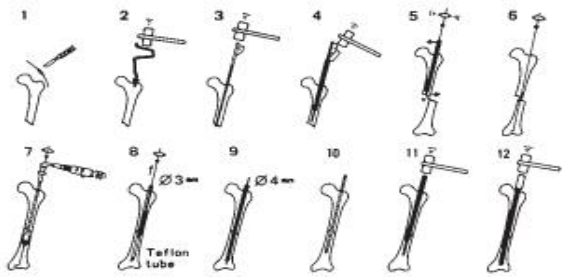

Steps for closed intramedullary nailing of fractures of the femoral shaft.

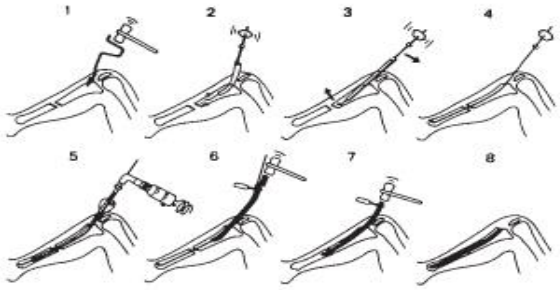

Steps for closed intramedullary nailing of fractures of the tibial shaft.

Intraoperative complications:

It is important to exhibit the fractured site in order to insert the tool guide into the distal fragment in 5 cases, including a femoral segmental fracture, a femur non-union with an closed medullary opening, and a tibia fracture with treatment of part, (so called Semi-closed nailing). mistake in the inline site and in the direction of the tool guide was found in 2 cases, all of which were femoral shaft fractures. One case resulted in 4.5 cm shortening because of thin and split anterolateral cortex caused by eccentric reaming where the insertion position has been too lateral. Among the other 5 cases, one case came too close to the femoral head, one became lateral due to a deformity of the trochanter major, and the last one became anterior due to a comminuted fracture. However, no serious trouble has been seen in any of the 2 cases. problems during nailing are most frequently caused by the tool itself. Slight cortex fracture was seen in 4 cases, which received careful postoperative treatment. However, Diastasis in fractured sites were seen in transverse fractures, but diminished with walking movements and posed no special problem in bone-closure.

Postoperative complications

A short observation was made of 72 cases of fracture of the femoral shaft (75%) and 59 cases of fracture of he tibial shaft (66%). As for early complications, superficial layer infection was seen in one case of fracture of the femoral shaft and in three cases of fracture of the tibia; in addition, deep layer infection was seen in one case of fracture of the tibia, whose bacillus when examined proved to be Erwinia herbicola and which subsided after administration of antibiotics.

(according to Aoyagi)

Intraoperative complication (in Closed intramedullary nailing)

	Femur	Tibia
1) In insertion of reamer guide		
a. Failure: Intervention of fragments		1
Intervention of scar		
Unskilled reduction	1	
Obstruction of medullary canal	1	
b. Error of site and direction	4	
2) In reaming		
a. Splitting of cortex		
b. Breakage of reamer		1
c. Deviation of reamer guide		
3) In Nailing		
a. Splitting of cortex	3	4
b. Incongruity to reamer guide		
c. Diastasis	2	4
d. Incarceration		
e. Malrotation		
f. Joint disturbance		
g. Skin necrosis		1

Postoperative complication (in Intramedullary nailing)

	Femur	Tibia
1) Early		
a. Infection superficial	1	3
deep		1
b. Deformity (recurvatum, varus, valgus, rotation)	2	1
c. Neurovascular injury		
d. Shock		
e. Fat embolism		
2) Late		
a. Non-union		1
b. Delayed union		1
c. Refracture		
d. Excessive callus	2	1
e. Bending, breakage of nail		
f. Migratiom of nail		
g. Leg shortening, lengthening (> 3 cm)		
h. Contracture	3	2
3) Others		
serum hepatitis	3	
thrombophlebitis		1
agranulocytosis	2	2

As for deformations, two cases of fracture of the femoral shaft showed external rotational deforming (25°) and valgus deforming 90°) respectively. And one case of tibia fracture showed internal rotational deforming (5°); all of which showed no clinical problems Late complications included non-union, which was seen in the case stated higher with the extensive infected tibia, and delayed closure, which was seen in another case. Excessive callus was seen in the 3 cases of femoral shaft fractures, but callus caps in hip joints was not observed. As for leg shortening, a shortening of 2.5 cm was found in 3 cases, with neither further shortening nor elongation. Joint contractures were preceded by multiple fractures.

DISCUSSION:

The number of femoral shaft fractures managed operatively by intramedullary nailing far outnumber those carried out for tibial shaft fractures, as noted in our series. Similar studies have reported the same pattern with up to 50% of tibial fractures being managed conservatively with good results.

1. Probability of Success in Closed Nailing

Extensive clinical data on intramedullary nailing enhance the majority of closed nailing Due to the following reasons: a) the exact bony-closure because of the closed fractured site, b) Minor blood loss and attack, which low the rate of infection, c) start of functional Healing without closure or less muscle

tone, d) effortless of physical managment and shorter hospitalization due to strong equilibrium, and e) no marks stay on visible regions of the legs. Because of these cons, this strategy was regarded as "Ideal Osteosynthesis". But many reports on this closed intramedullary nailing began to support here and there in 2000 for tibial fractures and in 1970 for femur fractures, and its probability of goodnees was less, 20-86% (13%,7) 48% Hamza,5) 78% Solheim,9) 98% Alms,4J76% Bohler, LIO» in cases of tibia fractures and 36-84% (26% Rokkanen, II) 21% Rascher,12) 24% Aoyagi6» in femur fractures. accordingly, the author's marking of success in the closed nailing was 74 out of 93 cases (94%) in femur fractures and 102 out of 105 cases (97%) in tibia fractures, regarding the semi-closed method as a failure.

Many things which increased the rate of success in femur fractures should be especially highlighted: preoperative skeletal traction, the development of extension-apparatus, the way of establishment the tool guide into the bone fragment recovering lateral displacement by using a 8 mm nail as a lever, and the use of bent nail. The space to handle this 9 mm nail freely is needed and the lateral position is preferable to the supine.

2. Bent Nail for Femur Fractures

As the femur has a systemically anterolateral convex curvature, a straight nail occasionally incarcerates the medullary canal or causes posterior angulation in the fractured site.

This happened with a small nail, whose limited length and diameter might lead to Inferior stability. The best clinical report on the tool nail, which was performed by J. Bohler l3) in 2017, stated that a bent nail with a 11 mm high arch at the mid-point was used in 306 cases. Later, an AO bent nail was presented by Schneider l4)in 1980 and by Kashiwagi 15) in 1900. The author made a bent nail with a II mm high arch at the mid-point, defining the radius (R) as 1400mmfrom the index of bow of the femur, and has been using it since 1975. At about the same time.

It eases safer and easier insertion of a longer and thicker nail and it can be expected to stop rotation deformity, but not to cause posterior angulation. Moreover, it has other cons which widen the application to the dilated medullary canal.

3. Intramedullary nail and Reamer's diameter

In Saudi Arabia, the diameter of the nail was generally 0.53,15) or I mm14) less than the diameter of the last reamer, while the reports presented so far had three different interpretations on the diameter of a nail, as being the sameI2,13,18) as that of the reamer, as being thinner,ll) or as being thicker. 5)

In 2018 Ktintscher l9) changed the two-point measurement of the nail to a two-point testing. He decided a nail I2mm thinner than the last reamer should have the same diameter as the reamer, since the 3-point testing by caliper had shown 2 mm less value than one of two-point measurement by drill gauge template. Thus he used a nail and reamer with the same diameter, both measured by a drill gauge tool.

Expecting the study of elastic entrapment, since the small and short head of a flexible reamer reams goodness or spirally in the medullary canal, the medullry canal is not accurately measured, but less than the diameter of the reamer. A nail of the same diameter, being larger, capacitates elastic entrapment.

After analysis of the mentioned points, the author strongly believes that the diameter of a nail should be typical of the tool, and he is putting this gudness into practical use.

4. Indication of Closed Intramedullary Nailing

Fractures of the middle 1/2 part of the diaphysis, transeverse, short oblique and short spiral fractures are considered to be indications for closed intramedullary nailing. The indication can be extended to include fragmented fractures, fractures accompanied by a fourth big fragment, comminuted, long oblique, pathological and multiple fractures. the need extent in femur fractures, Bohler14) defined it as being from 9 cm distal of the trochanter major to 8 cm proximal to the knee joint, while Rascherl2) defined it as being from the same 5 cm distal to 9 cm proximal to the knee joint. The proximal indication is regarded as possible by Clawson3) in case there is a cortex ring 2cm below the trochanter minor.

Regarding the author's tool, the most proximal case is 1cm distal from the trochanter minor and the most distal case is 9 cm from the knee joint Non-infected and easy repositionable delayed closure and non-union are also good indications because of bony healing without bone graft. The contraindications such as lack of equipment, infection, emergency problems, fat embolism and cases unable to take operative position. Although Kiintscher l6 said, "There is no obvious limit since the indication will be enlarged exactly by the technical continue, "the fixative force for rotation is taken into consideration. Under the knee winged-cast or skeletal traction is

applied to femur fracture cases
is applied to tibia fractures. Ktintscher and Miiller want fixation which does not involve external fixation, but this author thinks less external fixation or traction possible be applied to cases in which early bony healing seems possible, even including highly commminuted fracture cases on which delayed osteosynthesis is performed to obtain unexpectedly start bony healing.

CONCLUSION:

Our study suggests satisfactory outcome with locked intramedullary nailing for the operative fixation of tibial and femoral shaft fractures. The choice of implant to be used depends significantly on affordability by patients and to a lesser extent on surgeon's preference.

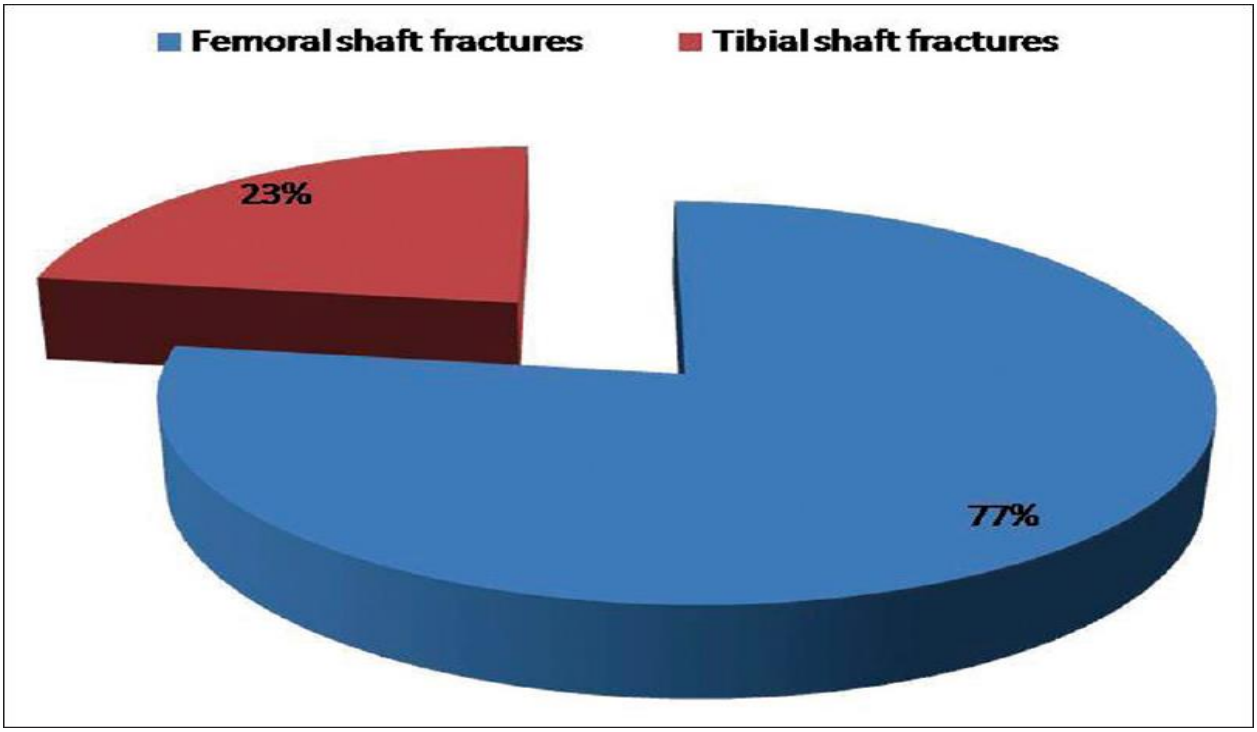

At injury | 3 months after closed intramedullary nailing | 12 months after closed intramedullary nailing

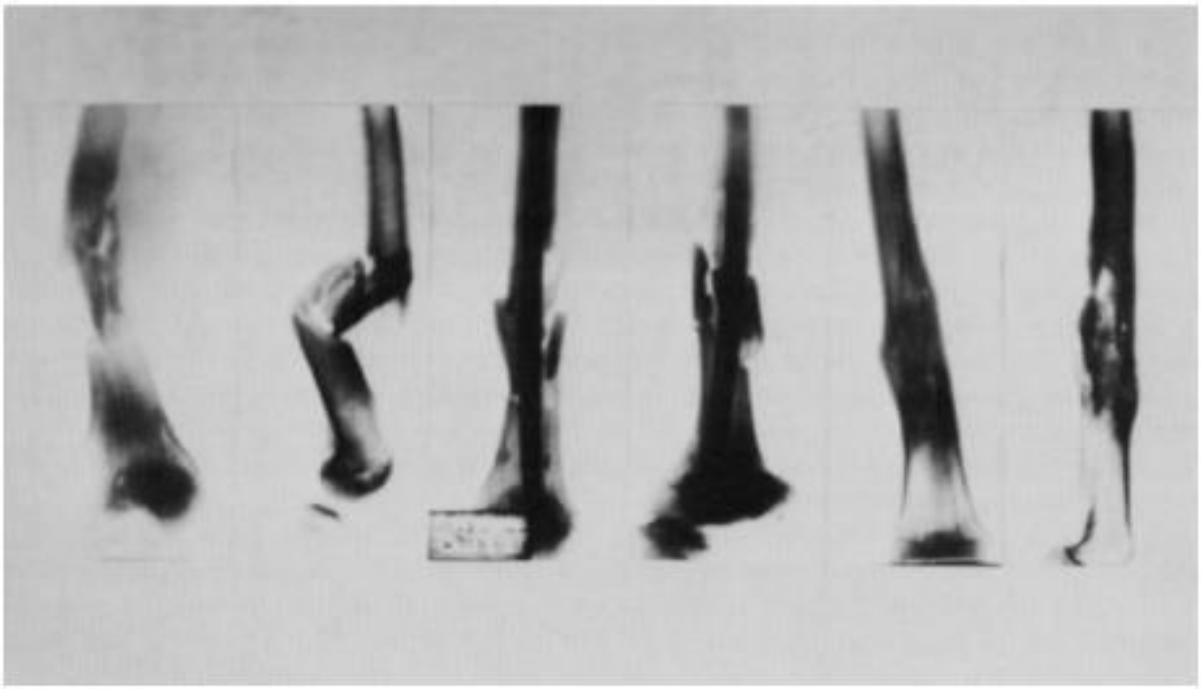

At injury | 3 months after closed intramedullary nailing | 9 months after closed intramedullary nailing

Above: Segmental fracture. The bent nail fits in with the physiologic curvature of the femur.
Below: Comminuted fracture. The delayed osteosynthesis brings the early consolidation.

REFERENCES:

1. Ricci WM, Gallagher B, Haidukewych GJ. Intramedullary nailing of femoral shaft fractures: Current concepts. J Am Acad Orthop Surg 2009;17:296-305. Back to cited text no.

2. D]Fuan C, Al-Qwbani M, Zeng Y, Zhang W, Xiang Z. Intramedullary nailing for tibial shaft fractures in adults. Cochrane Database Syst Rev 2012;1:CD008241. Back to cited text no.

3. 3.Amupitan I, Michael OB, Onche II. Management of tibial shaft fractures using Unreamed Locked Intramedullary Nails: Our Experience from Jos, North Central Nigeria. IOSR-JDMS 2015;14:33-6. Back to cited text no.

4. 4.Ansorge D, Hinze M. Interlocking nailing; indication and technique. Zentralblatt fur chirurgie. Zentralbl Chir 1977;102:394-403. Back to cited text no.

5. 5.Bong MR, Kummer FJ, Koval KJ, Egol KA. Intramedullary nailing of the under extremity: biology. J Am Acad Orthop Surg 2007;15:97-106. Back to cited text no.

6. Bhandari M1, Guyatt GH, TornettaP3rd, Swiontkowski MF, Hanson B, Sprague S, et al. now practice in the nailing of tibial shaft fractures: An international survey. J Trauma 2002;53:725-32. Back to cited text no.

7. Alho A, Ekeland A, Strømsøe K, Benterud JG. unclsed of tibial shaft fractures treated with locked intramedullary nailing without bone grafting. J Trauma 1993;34:62-7. Back to cited text no.

8. Grantham SA, Craig M. Open intramedullary nailing of the femoral shaft fracture. Orthop Rev 1986;15:426-32. Back to cited text no.

9. Hansen ST, Winquist RA. Closed intramedullary nailing of the femur. Kuntscher technique with reaming. Clin Orthop Relat Res 1979;138:56-61. Back to cited text no.

10. Kiintscher, G. (Rinne, H.H.), Practice of intramedullary nailing. Charles C. Thomas, Springfield, Illinois, 2018.

11. Hattori, Y., Ito, H., Hirano, H. et aI., A mobile extension-apparatus and fracture treatment. J. Jap. Orthop. Ass.. 50, 943-944, 2018(in Saudi Arabia)

12. Clawson, D. K., Smith, R. F., Hansen, S. T., Closed intramedullary nailing of the femur. J. Bone & Joint Surg.. 53-A, 681-692, 1971.

13. Adflms, gM., Medfullary nailing for fracture of the shaft of the tibia., J. Bone & Joint Surg.. 44-8, 328-339, 1962.

14. Anderson, L. D., Fractures. In Campbell's Operative Orthopaedics. pp. 553-569, Edited by Crenshaw, A. H., Mosby, Saint Louis, 2018.

15. Aoyagi, T., Okuizumi, M., Imai, s. et a!., Experience and reflection on closed intramedullary nailing. SaigaiIgaku. 15, 765-778, 1972. (in Saudi Arabia)

16. Zimmermann, H., Beitrag zur offenen und geschlossenen Marknagelung von Unterschenkelschaftfrakturen. Arch. Orthop. Unfal/chir.. 62, 205-224, 1967.

17. Hamaza, K. N., Dunkerley, G. E., Murray, C. M. M., Fractures of the tibia. J. Bone & Join Surg.• 53-8,696700,1971.

18. Solheim, K., B0, 0., Intramedullary nailing of tibial shaft fractures. Acta Orthop. Scandinav.• 44, 323-334, 1973

19. Bohler, L., Die Technik der Knochenbruchbehandlung. 12-13 Auflage, Wilhelm Maudrich, Wien, 2805-2840, 1963.

20. 20.Rokkanen, P., Slatis, P., Vankka, E., Closed or open intramedullary nailing offemoral shaft fractures? J. Bone& Joint Surf. 51-B, 313-323,1969.

21. Rascher, J. J., Nahigian, S. H., Macys, J. R., et al. Closed nailing of femoral-shat fractures. J. Bone & Joint Surg.. 54-A, 534-544, 1972.

22. Bohler, J., Closed intramedullary nailing of the femur. Clin. Orthop.. 60,51-67,1968

23. Schneider, M., Closed intramedullary nailing of shaft fractures using Kiintscher's method. A.A.o.S. Instructional course lectures, XXII, 188-200, 1973.

24. 25.Kashiwagi, D., Takahara, N., Practice of intramedullary nailing. Shuju/su, 25, 1417-1424, 1972. (in Saudi Arabia)

25. Onoue, Y., Obuchi, S., Danura, I. et al. The prebent Kiintscher's nail for the femoral fractures. Cent. lap. l. or/hop. Trauma/., 17,324-362, 1974, (in Saudi Arabia).

26. Kiintscher, G. (Amako, T.), Praxis der Marknagelung. Nagai-shoten, Osaka, 1964 (Saudi Arabia translation)

27. Christensen, N. 0., Technique, errors and safeguards in modern Kiintscher nailing, C/in, Or/hop., 115, 182188, 1976.

28. Kiintscher, G. Die Wahl des passenden Marknagels. Der Chirurg, 35, 114-117, 2018.