CODEN [USA]: IAJPBB ISSN: 2349-7750

INDO AMERICAN JOURNAL OF
PHARMACEUTICAL SCIENCES
http://doi.org/10.5281/zenodo.3597099

Available online at: http://www.iajps.com *Research Article*

USAGE OF COMPUTERIZED IMAGING TO CHOOSE SIZE AND STATE OF TONGUE AND TERRITORY

[1]Dr Madiha Anwar, [2]Dr Muhammad Saud Iqbal, [3]Abdullah

[1]Tehsil Headquarter Hospital Shakargarh, [2]Medical Officer, RHC Allah Abad, [3]Islamic International Medical College/Riphah International University.

Article Received: November 2019 **Accepted:** December 2019 **Published:** January 2020

Abstract:

Objective: *Current prescient aviation route tests center around the tongue, yet are abstract and differ enormously relying upon the specialist who performs them. We needed to build up a procedure of utilizes computerized imaging to decide size and state of tongue and territory of remaining parts empty in the oral depression. Our objective was to build up an exact and target appraisal of the elective aviation routes.*

Methods: *Our current research was conducted at Services Hospital Lahore from June 2018 to May 2019. The photographs were taken by the current medical research group. An aggregate of 12 photographic pictures were taken by 9 individuals utilizing ImageJ programming created by the Mayo Hospital Lahore and broke down to quantify size and state of tongue by territory estimation (in cm2), the zone of the teeth, the zone of the abandoned space, region of the whole oral hole (short lips). The proportion of the abandoned territory to the all-out oral depression was determined by partitioning the zone of the vacant zone by the region of the absolute oral cavity and increasing it by 100. What's more, intra-and between lateral unwavering quality was additionally estimated to evaluate the exactness of the goal assessment.*

Results: *Different sizes and states of tongues were found in oral hole. The proportion of abandoned zone to add up to oral depression was somewhere in the range of 21.8 and 48.4. We additionally discovered high exactness, characterized by intra-and between lateral unwavering quality of 1.639×11-5 and 4.348×10-4, separately.*

Conclusion: *Owing to distinctions in sizes and states of tongues, vacant zone staying in oral hole varied between the broke down pictures. In this manner, proportion of the vacant territory to the complete oral pit differed extraordinarily. In general, our elective technique can permit a progressively precise and target appraisal of the aviation routes.*

Keywords: *Airway; Valuation; Digital imaging; ImageJ; Tongue.*

Corresponding author:

Madiha Anwar,

Tehsil Headquarter Hospital Shakargarh.

QR code

Please cite this article in press Madiha Anwar et al., ***Usage Of Computerized Imaging To Choose Size And State Of Tongue And Territory,*** *Indo Am. J. P. Sci, 2020; 07(01).*

INTRODUCTION:

Anesthetists utilize preoperatively aviation route assessments to evaluate anatomical structures in oral pit and foresee which patients are hard to laryngoscope as well as intubate. Numerous abstract aviation route tests have been created, and albeit valuable, there is a critical absence of accuracy between the evaluations of various doctors [1]. Imaging thinks about have been utilized in the past to evaluate distinctive anatomical structures associated with aviation route the executives, yet require costly radiological gear and additionally complex programming examination [2]. The Mallampati Classification is a broadly utilized aviation route assessment performed before aviation route the board. It is controlled by the visual evaluation of how much distending tongue discourages perspective on tonsillar sections. Tongue size comparative with lingual fat was projected to correspond and conceivably clarify with Mallampati orders, through huge tongues demonstrating a higher probability of troublesome intubation [3]. The tongue might change in both size and shape in oral hole and may influence respiratory administration distinctively relying upon these attributes. We at of point determined a proportion of the vacant region to remainder of oral hole [4]. Our auxiliary objective was to quantify intra-and between lateral unwavering quality to decide the exactness of our technique. We present our first encounters with DI as a target device for estimating anatomical structures, exactly size and state of tongue and the proportion of abandoned region to oral cavity [5].

METHODOLOGY:

Endorsement from the Recognized Appraisal Board was not required, as venture was planned as the inner task and individuals from the examination group filled in as research subjects, albeit composed endorsement was all the while being acquired. Our current research was conducted at Services Hospital Lahore from June 2018 to May 2019. ImageJ, free programming from the NIH, accessible for Mac, Windows and Linux working frameworks and introduced on a scrambled PC. The fitness of the program activity was procured by the examination staff through instructional exercises and rehearsal with program. Microsoft Excel was utilized related to ImageJ on the grounds of it gives the most ideal approach to rapidly compute midpoints, standard deviations and proportions. The estimation elements of ImageJ were utilized to quantify the territory of the whole oral depression less the lips. The territory involved by the tongue was estimated, trailed by the region involved by the teeth lastly the abandoned region inside the oral depression (Figure 1b). The complete time for examination in ImageJ was under 6 minutes, contingent upon every individual's recognition with the program. The proportion of the vacant zone in oral pit was determined by separating region of vacant territory by zone of whole oral cavity and duplicating it by 100 (Figure 1c). To quantify exactness, standard deviations and deviations were found for estimations of a photo taken by an evaluator who rehashed multiple times the structures in the oral depression (complete territory of the oral pit, rate zone of the tongue, teeth, teeth and tongue, and abandoned region) to decide the unwavering quality of the intrareader. The standard deviations and deviations for average estimations of every estimation of a photo among 9 unique scorers were then determined to decide the unwavering quality between scores. The midpoints, standard deviations and deviations were determined utilizing Microsoft Excel®.

Table 1: Measured limitations of all of respondents:

Sample	Total area	Area of tongue	Teeth area	Unoccupied area
1	D	B	C	D
2	A	E	B	S
3	F	E	A	A
4	C	A	D	C
5	B	J	B	B
6	A	B	A	A

RESULTS:

Inconstancy in tongue size and shape:

Researchers found an enormous variety of tongue sizes also shapes in connection to oral cavity between various pictures. The mean region of tongue was 17.46 ± 5.86 cm2 (10.37-23.65 cm2). The average zone of oral hole was 29.09 ± 9.42 cm2 (15.62-39.13 cm2) (see Figure 2a). See Figure 2b for the assortment of tongue shapes. The proportion of vacant zone to oral cavity Table 3 displays estimations of proportion of vacant territory in oral cavity for every one of nine pictures. The proportions were somewhere in the range of 20.8 and 48.7, with 20.8%. The figures were 20.8 % and 48.7 %, separately, speaking to the oral

depression with the littlest accessible vacant zone and 48.7 % speaking to the oral hole with the biggest accessible abandoned region. Figure 3 shows the proportion determined with its particular picture.

Exactness controlled by dependability inside and between singular rates.

Intra-and interramal dependability was 1.639 × 11-5 and 4.348 × 11-5, showing high exactness of the technique (Box 2).

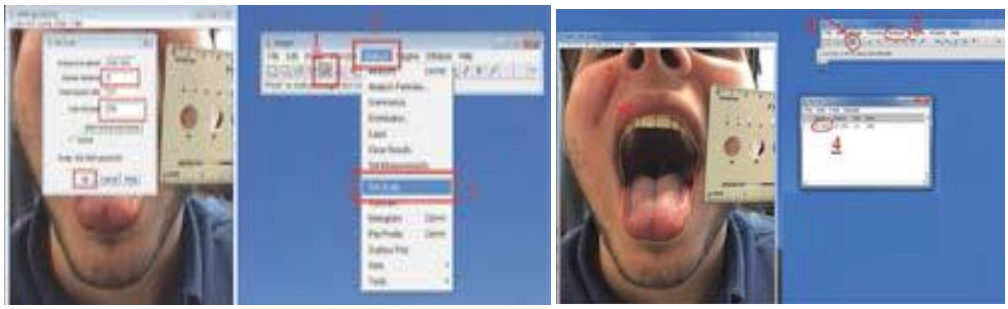

Table 3: Ratio of the unoccupied space available in the oral cavity;

Image	Area of teeth	Area of tongue	Ratio unoccupied	Area of unoccupied space
1	1.634	30.1	17.049	20.4
2	2.777	23.003	6.479	30.1
3	0.192	10.714	21.1	3.210
4	1.750	7.943	19.643	27.9
5	5.816	27.460	21.1	8.052

DISCUSSION:

We discovered of there is an extraordinary fluctuation in the advanced picture investigation of the sizes and states of tongues. Researchers found of size of tongue remained significant just when it was comparative with the remainder of the oral cavity [6]. In this manner, we determined the proportion of the empty region to the absolute oral depression, where little numbers imply of the tongue possesses a huge piece of the oral hole and stays a little vacant region to move a respiratory gadget for intubation [7]. We felt it was imperative to build up an increasingly exact, target evaluation of the aviation routes to measure the tongue, as it is known to assume a significant job in anticipating troublesome aviation routes. The tongue is primary part of standard preoperatively aviation route appraisal at the bedside (Mallampati grouping) [8]. The subjectivity of aviation route tests, including the Mallampati arrangement, and the inconstancy of evaluations of troublesome aviation routes by various doctors lead to errors. We accept of this relationship alludes to the abandoned region of the oral hole and not to the zone legitimately involved by the tongue [9]. The tongue size was evaluated all the more straightforwardly by the utilization of sonography in another examination, which contrasted the tongue size and various other anatomical highlights. Sonographic estimations and ImageJ didn't show of tongue size alone is measurably huge among troublesome and straightforward intubation, despite the fact of hymen separation in the head drawn position was considered factually critical. Our strategy stays in accordance with the long-standing point of reference for tongue distension utilized by Mallampati in his unique philosophy [10].

CONCLUSIONS:

In outline, our novel strategy has given another option, easy to use and dependable investigation to precisely and rapidly measure size and state of tongue, empty territory of oral hole and the proportion of abandoned region to the whole oral hole. Our option exact, target appraisal of the aviation routes had high intra-and between rateral unwavering quality. With the coming of more noteworthy utilization of cell phones, future advancements in this application give off an impression of being at the front line. It is conceivable of additional investigations with DI might correspond proportion of vacant zone to whole oral cavity with troublesome aviation route executives, effective intubation gadget or potentially entanglements.

REFERENCES:

1. Connor CW, Segal S. Accurate classification of difficult intubation by computerized facial analysis. Anesth Analg. 2011;112:84-93. [PubMed] [Free full text] DOI: 10.1213/ ANE.0b013e31820098d6
2. Naguib M, Malabarey T, AlSatli RA, Al Damegh S, Samarkandi AH. Predictive models for difficult laryngoscopy and intubation. A clinical, radiologic and three-dimensional computer imaging study. Can J Anaesth. 1999;46:748- 59. [PubMed] [Free full text] DOI: 10.1007/BF03013910
3. Wojtczak JA. Submandibular sonography: assessment of hyomental distances and ratio, tongue size, and floor of the mouth musculature using portable sonography. J Ultrasound Med. 2012;31:523-8. [PubMed] [Free full text]
4. Gupta K, Gupta PK. Assessment of difficult laryngoscopy by electronically measured maxillo-pharyngeal angle on lateral cervical radiograph: prospective study. Saudi J Anaesth. 2010;4:158-62. [PubMed] [Free full text] DOI: 10.4103/1658-354X.71572
5. Mallampati SR, Gatt SP, Gugino LD, Desai SP, Waraksa B, Freiberger D, et al. A clinical sign to predict difficult tracheal intubation: a prospective study. Can Anaesth Soc J. 1985;32:429-34. [PubMed] [Free full text]
6. Nashi N, Kang S, Barkdull GC, Lucas J, Davidson TM. Lingual fat at autopsy.Laryngoscope. 2007;117:1467- 73. [PubMed] DOI: 10.1097/ MLG.0b013e318068b566
7. Adamus M, Fritscherova S, Hrabalek L, Gabrhelik T, Zapletalova J, Janout V. Mallampati test as a predictor of laryngoscopic view. Biomed Pap Med Fac Univ Palacky Olomouc Czech Repub. 2010;154:339-43. [PubMed] [Free full text]
8. Yentis SM. Predicting difficult intubation--worthwhile exercise or pointless ritual?

Anaesthesia. 2002;57:105- 9. [PubMed] [Free full text] DOI: 10.1046/j.0003-2409.2001.02515.x

9. Shiga T, Wajima Z, Inoue T, Sakamoto A. Predicting difficult intubation in apparently normal patients: a meta-analysis of bedside screening test performance. Anesthesiology. 2005;103:429-37. [PubMed] [Free full text]
10. Karkouti K, Rose DK, Ferris LE, Wigglesworth DF, Meisami-Fard T, Lee H. Inter-observer reliability of ten tests used for predicting difficult tracheal intubation. Can J Anaesth. 1996;43:554-9. [PubMed] [Free full text]