CODEN [USA]: IAJPBB ISSN: 2349-7750

INDO AMERICAN JOURNAL OF
PHARMACEUTICAL SCIENCES

http://doi.org/10.5281/zenodo.3619622

Available online at: http://www.iajps.com *Research Article*

CORRECTION OF CUBITUS VARUS DEFORMITY, TECHNIQUES, AN OVERVIEW

[1]Ali Atiah Alzahrani
*[1]KFMC , Taif , KSA

Article Received: November 2019 **Accepted:** December 2019 **Published:** January 2020

Abstract:
Complex defects of the distal humerus as well as lower arm of either posttraumatic or genetic origination have a considerable negative influence on the functional integrity of the impacted limb. Various techniques of osteotomy have been proposed for the therapy of cubitus varus, which can lead to some complication and most notable aesthetic ones. In this review we highlight available management methods and in details discuss some surgical approaches, their advantages and disadvantages.An electronic search was conducted through; PubMed, EMBASE, CINAHL, SCOPUS, databases, from inception until end of 2019, this search was concerning the Cubitus Varus Deformity. Cubitus varus is one of the most popular difficulty of supracondylar fracture of the humerus it is virtually always second to uncorrected or persistent medial tilting of the distal part of the fracture. It is an avoidable consequence if medial tilt is acknowledged early by cautious medical and radiological evaluation.

Corresponding author:
Ali Atiah Alzahrani,
KFMC, Taif , KSA

QR code

Please cite this article in press Ali Atiah Alzahrani et al., ***Correction Of Cubitus Varus Deformity, Techniques, An Overview.,*** *Indo Am. J. P. Sci, 2020; 07(01).*

INTRODUCTION:

External angulation of supinated flower arm with elbow stretched is named carrying angle (Figure 1). Natural carrying angle is 6 °- 14 ° with even more angle in girls than in boys [1]. Any kind of reduction in the standard bring angle of the elbow joint generates cubitus varus defect. One of the most common source of this deformity is late complication of supracondylar break of the humerus [1]. Supracondylar fractures of the humerus make up about 10% of all paediatric fractures and, with breaks of the lateral condyle, are one of the most typical fractures of the elbow in children [1],[2].

It is a poorly tolerated aesthetic deformity with almost no functional difficulties in performing, although there is some problem in bring heavy weights. This defect can be progressive or non-progressive. The defect following humeral supracondylar fracture is non-progressive, while progressive defect could be because of physeal trauma of medial condyle, malunited fracture of lateral condyle and also congenital cubitus varus deformity [2].

Non-progressive defect is usually handled by one surgical treatment while progressive cubitus varus deformity might require repeated surgical treatments. Numerous restorative osteotomies have actually been described for the cubitus varus such as lateral closing wedge osteotomy, medial opening wedge osteotomy, dome osteotomy, step-cut osteotomy as well as pentalateral osteotomy [1],[2].

Complex defects of the distal humerus as well as lower arm of either posttraumatic or genetic origination have a considerable negative influence on the functional integrity of the impacted limb. Various techniques of osteotomy have been proposed for the therapy of cubitus varus, which can lead to some complication and most notable aesthetic ones. In this review we highlight available management methods and in details discuss some surgical approaches, their advantages and disadvantages.

METHODOLOGY:

An electronic search was conducted through; PubMed, EMBASE, CINAHL, SCOPUS, databases, from inception until end of 2019, this search was concerning the Cubitus Varus Deformity, and performed using the following keywords in various combinations: “Cubitus Varus Deformity”, “treatment, methods, techniques,”. English language restrictions were applied with human subjects only. References from identified articles were searched for additional relevant studies.

DISCUSSION:

Examining the patient and analyzing the deformity:

Posttraumatic elbow and lower arm deformity can happen following either non-operative or operative treatment of severe bone fractures, along with adhering to deformity adjustment surgical procedure (iatrogenic); it provides as impairment of function that is typically intensified during growth [4]. While one of the most common defect at the elbow joint, varus impairment, was seen for many years as a "completely" aesthetic issue, current publications and the monitoring in the authors' multidisciplinary team from Hamburg, Düsseldorf, as well as Markgröningen, Germany, have actually revealed that longstanding varus deformity of the elbow joint can result in ulnar neuritis, medial lack of stability, and practical impairment of the influenced upper extremity [3] Nonunion of the radial or ulnar condyle brings about extreme arthrosis of the influenced elbow joint, causing pain, reduction of movement, as well as handicap in daily life and also professional tasks [4].

Clinical assessment ought to examine as well as objectively record the restriction in range of elbow and also lower arm motion, specifically pronation and supination, and also identify signs of proximal and distal radioulnar joint lack of stability and ache with and also without motion or strenuous exercise. Painful clicking at both the elbow and also wrist joint during pro- and supination, hard or weak ending of activity (typically with a visible and apparent subluxation of the joint structure, particularly at the elbow), along with motion and also stability of both the wrist and elbow joint are recorded. The elbow axis is recorded both medically and also radiologically by measuring the humerus-elbow-wrist angle, the Baumann angle, and also the carrying angle (Figure 1) [6]. Information about leisure activities, day-to-day limitations brought on by the condition, pain drug use, capability to execute workouts, and the importance of having a "normal-looking" forearm (the aesthetic aspects) should already be documented at an onset. Grading of Cubitus varus can be used to evaluate as well (Table 1) [7].

In the last 5 years, in cases of challenging deformities in greater than one plane at the distal humerus, along with in cases with rotational deformity in the forearm (e.g., after malunion), the authors execute computerized three-dimensional (3D) planning, because rotational defects can not regularly and also accurately be determined by traditional planning strategies [5].

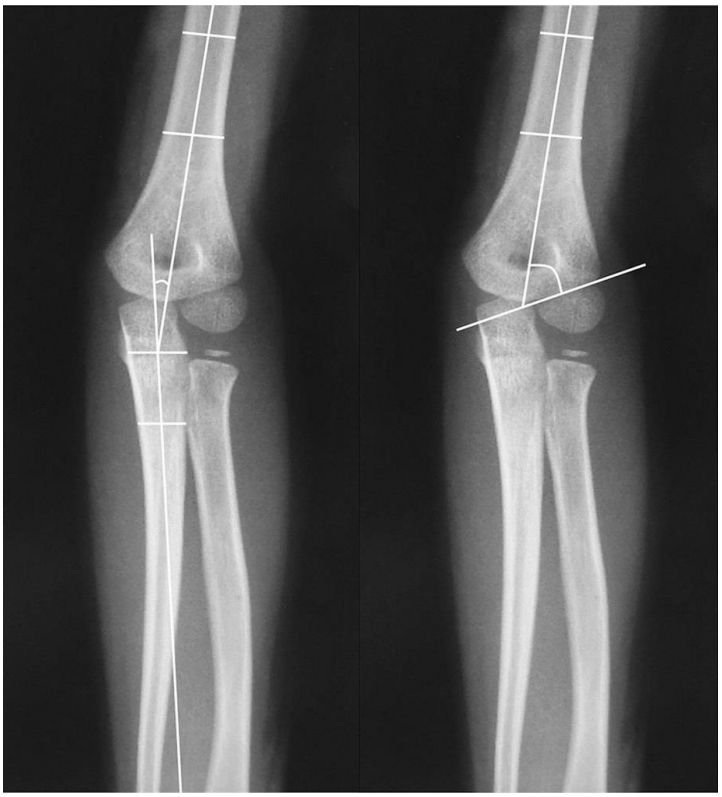

Figure 1. Radiograph illustrating the carrying angle on the left side and Bauman angle on the right [6].

Table 1. Grading of Cubitus varus [7].

Grade I	Physiological Cubitus valgus was lost.
Grade II	Cubitus Varus upto 5°
Grade III	Cubitus Varus of more than 5°

Current Surgical Techniques:

The treatment for both cubitus varus and valgus is through carrying out an osteotomy at the distal portion of the humerus. Nonetheless, there are numerous variations of this surgical approach that can be used to correct these deformations, and all of them have different configurations for the osteotomy, various fixation approaches as well as various methods to the defect [5]. Cubitus varus deformity has no propensity for spontaneous improvement but it always needs to be remedied.

One of the most common, easy and also much safer strategy is the Lateral Closing Wedge Osteotomy with K-wire fixation. The biggest issue linked to this approach is the rise of the notability of the lateral condyle (when it comes to cubitus varus) and also of the notability of the medial epicondyle (for the cubitus valgus). An alteration of this approach that seems to lower this notability is the Lateral Closing Wedge Osteotomy with a medial displacement of the distal portion resulting from the osteotomy [8].

Another strategy whose main objective is to manage the prominence of the condyles is the Lateral Closing Wedge Osteotomy however with equal limbs, a technique that, besides being able to fix this issue, is not difficult to reproduce [8].

The Dome Osteotomy is one more choice, and is a different technique given that the osteotomy is made along a semicircle, with an about 3cm radius, that is centred at a place positioned 1cm distal from the olecranon [9].

The Step Cut Osteotomy is likewise a sensible choice, considering that it makes it possible to stay clear of any type of lateral prestige [10]. For grownups, the Oblique Closing Wedge Osteotomy represents a great choice because of the increased area of contact in

between the proximal and also distal components after the osteotomy, which assists with the recovery procedure of the bone [11]. Finally, there is also the Medial Opening Wedge Osteotomy with Bone Graft, where the correction of the defect is based upon the Illizarov technique. However, this technique has a high risk of damages to the ulnar nerve because of its stretching and extending [12].

The preoperative planning of the surgical procedure in all these techniques is made based on radiographs acquired at an anteroposterior view (AP) and a lateral viewpoint. The AP radiograph is acquired with the elbow completely extended as well as the forearm supinated, while the lateral view one is obtained with a 90º elbow flexion as well as the palm and also the lower arm relaxed at a table [13]. To establish the restorative osteotomy angles, various measurements can be made: on the AP view, the carrying angle and the Baumann's angle can be measure; for the lateral view, the humerotrochlear angle is the one used. The carrying angle of the joint represents the angle developed in between the crossway of the prolonged axis of the humeral shaft as well as the long axis of the forearm on the anteroposterior view [6].

The numerous osteotomies performed can be dealt with utilizing metallic plates, stainless steel cords, screws and staples. Unstable inner fixation enables the osteotomy piece to slip into a varus setting in a number of people [7].

Table 2. Summary of the treatment options of cubitis varus [7-13].

Treatment options include: **(a) Observation with expectant remodelling:** Not right due to the reason that hyperextension can remodel to some degree in a young children, in an older children only little remodelling take place even in the joint's plane of movement. Hence, it is not recommended. **(b) Hemiepiphysiodesis and growth alteration:** It is applied to prevent cubitus varus deformity in a individuals with medial growth arrest and progressive deformity, instead of correcting it. It has no role in a child with a normal physis. **(c) Corrective Osteotomy:** Osteotomy is the only way to correct a cubitus varus deformity with a high probability of success. Options include; • Medial open wedge osteotomy • Lateral closing wedge osteotomy with or without simultaneous correction of rotation, also known as French osteotomy • Step cut osteotomy. • Arch osteotomy • Pentalateral osteotomy • Oblique osteotomy with derotation. • Dome osteotomy • Reverse V osteotomy.

Surgical management approaches:
The surgical strategies which have actually been explained for the adjustment of cubitus varus vary in their strategy to the distal humerus, the approach of osteotomy and the type of fixation. A few of them will be discussed below.

A lateral closing-wedge osteotomy:
The very first description of a lateral closing-wedge osteotomy for the improvement of cubitus varus was by Siris in 1939, which brought about several other techniques being established [14]. These strategies have actually been organized right into two classifications: osteotomy approaches and fixation methods. The techniques utilized for fixation consist of exterior fixation and interior fixation. Inner fixation is a one-stage procedure and also further modifications are not possible after the procedure, which is thought about the main drawback of interior fixation. Thus, precise preparation is highlighted before surgical treatment. In addition, some writers have actually reported one more disadvantage, hypertrophic scars, compared with the exterior fixation methods [15]. The exterior fixation procedure has some advantages: additional modification as well as modification are feasible after the procedure and it does not have bone loss or a prominent device; nevertheless, it can cause pin system infection or elbow joint tightness and also is not tolerated as well as interior fixation [15].

Dome osteotomy using the paratricipital (triceps-sparing):
Dome osteotomy for modification of cubitus varus deformity was first explained by Tachdjian, who did not report any outcomes [16]. Good outcomes with no problems were documented by Kanaujia et al. [17].

The osteotomy has improved mechanical support compared with the formerly mentioned techniques since it has a center of rotation in the midline of the humerus [17]. As a result of the location of the center of turning, there is no condylar notability after deformity adjustment. The broad, bony contact surface area as well as no shortening of the humerus after modification can additionally be considered as advantages. It is easy to control the correction angle after finalization of the osteotomy using the image intensifier before the supreme fixation. Furthermore, dome osteotomy remedies the deformity in the coronal and horizontal planes all at once with just one bone cut.

Previous detectives of the triceps-splitting or peeling strategies have proposed an adverse result on muscle mass power on the basis of the possible direct muscular tissue injury with resultant fibrosis and injury to intramuscular nerve branches [21]. The research study outcome contrast positively with other studies using various methods as this technique maintains the triceps attachment to the olecranon and also gets rid of the need for triceps restore and also security postoperatively, allowing active ROM in the injured elbow [22].

Tien et al., applying the triceps-splitting strategy, reported lowered ROM in flexion in nine of their 15 individuals, which was considered the most important aspect affecting the end result in their sequence [18]. Hahn et al. reported lowered postoperative flexion in 18 of their 19 people after the triceps-splitting approach for the dome osteotomy [19]. Likewise, Kumar et al., utilizing the triceps-splitting approach, documented a typical reduction in flexion of 9 ° postoperatively [20].

Step-cut translation osteotomy:

The step-cut translation osteotomy is naturally steady and also the wide osteotomy surface helps with an early union of the osteotomy spot in 4- 6 weeks in the majority of the instances [23]. Medial translation of the distal piece fixes the defect without creation of a notability of lateral condyle; this in addition to the posterior mark develops a cosmetically acceptable deformity modification. Medial translation of distal portion may also stabilize the subluxation of the median head of triceps muscles and the ulnar nerve. Fixation of the osteotomy site with Y plate supplies stiff fixation as well as allows very early mobilization of the arm joint; for that reason, minimizing possibilities of elbow tightness. Song et al. stresses the value of maintaining variety of activity during treatment to acquire a good functional outcome [25],[23].

In Kans et al., research, 62.5% (20/32) of patients remained in the age of 5-12 years at the time of osteotomy with growth remaining [24]. Follow-up programs no reoccurrence of the deformity as well as they posit that this osteotomy can be done before the second growth spurt without the fear of reoccurrence of deformity. Kans KS et al., show that a step-cut translation osteotomy has the capability to correct cubitus varus as well as valgus defects without any precedence of the medial or side condyle in the many of individuals [24]. Furthermore, a broad osteotomy surface area as well as rigid fixation permits earlier motion than is possible with various other osteotomy methods. In that study, 96.2% situations of the cubitus varus and all situations of cubitus valgus defect had excellent-to-good results.

Reverse V osteotomy:

Reverse V osteotomy was explained by Yun and also Shin for dealing with cubitus varus [26]. This technique shows benefit over step-cut osteotomy due to the reason that it supplies a lot more accessible space for fixation over distal sector. Because it is done at little bit higher level, more offered space at distal part might involve screws of plates, if it is being performed in grownups. Its fundamental reliability appears due to appropriate fitting of its firm wedge on both medial and also side columns. Configuration of reverse V osteotomy itself provides restraint to valgus and also varus forces. Cross K-wire as well as wires (from lateral side) or Y-plating further multitudes its stableness of form [26]. Based on this osteotomy, Yun and Shin in their research study found excellent result in 91% and also good outcomes in 9% situations. In another study of Oner et al., they also revealed 78% outstanding as well as 22% good outcomes by using reverse V osteotomy for correcting childhood cubitus varus [27].

Complications of varus osteotomy:

Even though cubitus varus has recently been documented to be connected with ulnar neuropathy, avascular necrosis of the distal humeral epiphysis, snapping of the medial section of the triceps muscles, as well as tardy posterolateral rotatory unsteadiness of the elbow, in most of the patients, the common providing complaint is an undesirable deformity rather than a practical disability [16].

The primary problems are lateral precedence, incomplete improvement, lack of correction, nerve palsies, contamination as well as re-operations [28]. Lateral projection was stated in French osteotomy as a

result of prominence of distal portion laterally. An equal limb oblique osteotomy minimizes this issues. Medialization of the distal particle may likewise decrease the side portion projection [29]. In a recently released researches of French osteotomy it is indicated that the lateral eminence does remodel in more youthful kids (less than 11 years of age) [30]. Dome as well as step cut osteotomies do not have issues of lateral prominence.

Incomplete Modification is typically a complication of incomplete planning and implementation and also is not a feature of electing the osteotomy. It is revealed in 5.9% of patients [28]. Loss of correction is a function of sort of osteotomy and kind of fixation used. As stated previously screws with tension loop wires may fail if the median proceeded is jeopardized. In a similar way fixation with smooth K wires have much more chances of losing of fixation. Nerve palsies have actually been documented in concerning 2.5% of situations of cubitus varus correction osteotomies with reducing frequencies of involvement of ulnar, radial and median nerves [28]. Almost 78% of these palsies are short-lived and recover. Nerve injuries are extra generally seen in dome osteotomies with marginal threat in disturbance osteogenesis [28]. General problem rate for osteotomies is documented to be 14.5% with poor outcomes are seen around 12% cases [28]. Most issues are seen in situations with K wire fixation and cheapest total complication rate is seen in external fixation. Nevertheless, outside fixation patients have greatest rate of infection. The complexity of osteotomy does not influence the general problem rate but certain difficulties may be more with particular osteotomies, like nerve injuries in dome osteotomies. Result can be graded by the criteria as Excellent, Good and Poor (Table 3) [7].

Table 3. Evaluation of final results [7].

Excellent	Correction to within 5° of the Contralateral elbow. Maintenance of preoperative elbow motion. No perioperative complication.
Good	Demonstrated a valgus elbow position Motion to within 10° of the preoperative level.
Poor	Any perioperative complication including residual varus. Loss of greater than 10° of elbow motion.

CONCLUSION:

Cubitus varus is one of the most popular difficulty of supracondylar fracture of the humerus it is virtually always second to uncorrected or persistent medial tilting of the distal part of the fracture. It is an avoidable consequence if medial tilt is acknowledged early by cautious medical and radiological evaluation. Even though cubitus varus has actually lately been reported to be related with ulnar neuropathy, avascular necrosis of the distal humeral epiphysis, snapping of the median part of the triceps muscles, as well as tardy posterolateral rotatory vulnerability of the elbow joint, in most of the patients, the typical offering problem is an undesirable defect instead of a functional impairment.

Humeral osteotomy is applied to fix this deformity and also to prevent later on difficulties, such as ulnar nerve palsy, posterolateral rotary irregularity as well as second distal humeral fracture. A range of osteotomies has been proposed to remedy the complex deformity. Preoperative planning is significant step because the surgeon has to take into consideration the risks in advance maintaining the medial cortex is of paramount significance in obtaining stability with use of minimal interior fixation.

REFERENCE:

1. Smith L. Deformity following supracondylar fractures of the humerus. J Bone Jt Surg Am. 1965;47:1668.
2. Theruvil B., Kapoor V., Fairhart J. Progressive cubitus varus due to bony physeal bar in a 4 year old girl following a supracondylar fracture. J Orthop Trauma. 2005;19:669–672.
3. Ham J, Flipsen M, Koolen M, van der Zwan A, Mader K Multiple. Osteochondromas (MO) in the forearm: a 12 years' single center experience. Strategies in Trauma and Limb Reconstruction 2016;11:169–175.
4. Fernandez F, Mader K Posttraumatische Deformitäten am Ellenbogen des Kindes. Expertise Ellenbogen. Thieme, Stuttgart, 2006.
5. Myake J et al.In vivo three-dimensional analysis of chronic radial head dislocations. Clin Orthop 2002; 470:2746–2755.
6. Inabaa N, Suzukia T, Iwamotoa T et al. Normal value and range of the humerus-elbow-wrist angle in a sample of healthy children with even distributions of age, sex, and laterality. J Pediatr Orthop B, 2018;28:57–61.

7. Dudhekar U. Prospective study of cubitus varus deformity, its etiopathology, clinical study and treatment. Int J Res Med Sci. 2017 Jan;5(1):201-205.
8. El-Adl, Wael. "The equal limbs lateral closing wedge osteotomy for correction of cubitus varus in children." Acta Orthopaedica Belgica 73 (2007): 5.
9. Hahn, Soo Bong, Yun Rak Choi, and Ho Jung Kang. "Corrective dome osteotomy for cubitus varus and valgus in adults." Journal of Shoulder and Elbow Surgery 18 (2009): 38-43.
10. Bali, K., P. Sudesh, A. Sharma, S.R.R. Manoharan, and A.K. Mootha. "Modified step-cut osteotomy for posttraumatic cubitus varus: Our experience with 14 children." Elsevier Masson, May 2011.
11. Gong, Hyun Sik, Moon Sang Chung, Joo Han Oh, Hoyune Esther Cho, and Goo Hyun Baek. "Oblique Closing Wedge Osteotomy and Lateral Plating for Cubitus Varus in Adults." Clinical orthopaedics and related research 466.4 (2008): 899-906.
12. Babhulkar, Sudhir. Elbow Injuries. New Delhi: Jaypee Brothers Medical Publishers, 2015.
13. Park, Shinsuk, and Eugene Kim. "Estimation of carrying angle based on CT images in preoperative surgical planning for cubitus deformities." Acta Medica Okayama 63.6 (2009): 359-365.
14. Siris IE. Supracondylar fracture of the humerus. Surg Gynecol Obstet. 1939;68:201–222.
15. Handelsman JE, Weinberg J, Hersch JC. Corrective supracondylar humeral osteotomies using the small AO external fixator. J Pediatr Orthop B. 2006;15:194–197.
16. Tachdjian MR. Osteotomy of distal humerus for correction of cubitus varus. In: Smith AB, editor. Pediatric orthopedics. Philadelphia, PA: WB Saunders; 1972. pp. 1588–1591.
17. Kanaujia RR, Ikuta Y, Muneshige H, Higaki T, Shimogaki K. Dome osteotomy for cubitus varus in children. Acta Orthop Scand 1988; 59:314–318.
18. Tien YC, Chih HW, Lin GT. Dome corrective osteotomy for cubitus varus deformity. Clin Orthop Relat Res 2000; 380:158–166.
19. Kumar K, Sharma VK, Sharma R, Maffulli N. Correction of cubitus varus by French or dome osteotomy: a comparative study. J Trauma 2000; 49:717–721.
20. Hahn SB, Choi YR, Kang HJ. Corrective dome osteotomy for cubitus varus and valgus in adults. J Shoulder Elbow Surg 2009; 18:38–43.
21. Kasser JR, Richards K, Millis M. The triceps-dividing approach to open reduction of complex distal humerus fractures in adolescents: a Cybex evaluation of triceps function and motion. J Pediatr Orthop 1990; 19:93–96.
22. Bellemore MC, Barrett IR, Middleton RW, Scougall JS, Whiteway DW. Supracondylar osteotomy of the humerus for correction of cubitus varus. J Bone Joint Surg Br 1984; 66:566–572.
23. Kim HT, Lee JS, Yoo CI. Management of cubitus varus and valgus. J Bone Joint Surg Am 2005;87:771-80.
24. Kant KS, Gupta V. Step-cut translation osteotomy and Y-plate fixation: A novel method for correction of cubitus varus and valgus deformity. Paediatr Orthop Relat Sci 2017;3:12-5.
25. Song HR, Cho SH, Jeong ST, Park YJ, Koo KH. Supracondylar osteotomy with Ilizarov fixation for elbow deformities in adults. J Bone Joint Surg Br 1997;79:748-52.
26. Yun YH, Shin SJ, Moon JG. Reverse V osteotomy of the distal humerus for the correction of cubitus varus. J Bone Joint Surg Br. 2007;89(4):527–531.
27. Oner M, Guney A, Halici M, Turk CY. The results of reverse V osteotomy of the distal humerus for the correction of childhood cubitus varus deformity. Eklem Hastalik Cerrahisi. 2009;20(2):85–89.
28. Solfelt DA, Hill BW, Anderson CP, Cole PA. Supracondylar osteotomy for the treatment of cubitus varus in children: a systematic review. Bone Joint J. 2014 May;96-B(5):691-700.
29. Moon MS, Kim SS, Kim ST, Lee SR, Lee BJ, Jin JM, Moon JL. Lateral closing wedge osteotomy with or without medialisation of the distal fragment for cubitus varus. J Orthop Surg (Hong Kong). 2010 Aug;18(2):220-3.
30. Cho CH, Song KS, Min BW, Bae KC, Lee KJ. Long-term results of remodeling of lateral condylar prominence after lateral closed-wedge osteotomy for cubitus varus. J Shoulder Elbow Surg. 2009 May-Jun;18(3):478-83.