CODEN [USA]: IAJPBB ISSN: 2349-7750

INDO AMERICAN JOURNAL OF
PHARMACEUTICAL SCIENCES

http://doi.org/10.5281/zenodo.3630128

Available online at: http://www.iajps.com *Research Article*

STUDY OF FUNCTIONAL OUTCOME OF REVERSE LOCKING PLATE IN EXTRA-CAPSULAR FRACTURES OF THE PROXIMAL FEMUR

[1]Dr. Abdul Munaf Saud, [2]Dr. Syed Hahib Ullah , [3]Dr. Mohammad Abid

[1]Assistant Professor, Department of Orthopedic Surgery, Quaid-e-Azam Medical College, Bahawalpur

[2]Associate Professor, Department of Orthopedic Surgery, DG Khan Teaching Hospital, DG Khan

[3]Assistant Professor, Department of Orthopedic Surgery, Shahida Islam Medical College Lodhran

Article Received: November 2019 **Accepted:** December 2019 **Published:** January 2020

Abstract:

Objective: *To study the functional outcome of reverse locking plate in extra-capsular fractures of the proximal femur.* ***Material and methods:*** *This cross sectional study was conducted at Department of Orthopedic Surgery, Civil Hospital, Bahawalpur from January 2018 to December 2018 over the period of 1 year. Total 17 patients with extra-capsular fracture of proximal femur with one or more of the following: unstable fracture pattern, bowed femur, deformed femur, short skeleton, narrow femoral canal (diameter <8mm), open fracture presenting within 24 hours having age 10-80 years either male or female were selected for this study and functional outcome of reverse locking plate was assessed.* ***Results:*** *In present study union of fracture was achieved in all the cases. The mean duration of surgery in inter-trochanteric fractures was 135 ± 24.8 minutes and for sub-trochanteric fractures was 115 ± 22.8 minutes. Male patients were 13 and female patients were 3. Total 15 out of 17 patients attended follow-up for a minimum of 1 year. Partial weight bearing walking was started at 2 months in 6 patients, 3 months in 4 patients and at more than 4 months in 3 patients. Full weight bearing walking was started at 5 months in 11 patients, at 9 months in 3 patients and at 1 year in 1 patient.* ***Conclusion:*** *From this study, we conclude that unstable fractures unite satisfactorily within reasonable period of time by use of reverse distal femur locking plate. There were fewer complications, early mobilization and high patient satisfaction. Reverse distal femoral locking plate is a treatment option that needs to be evaluated further in order to recommend this surgery for specific subset of patients with hip fractures.*

Keywords: *Unstable proximal femoral fractures, Extra-capsular fracture*

Corresponding author:

Dr.Abdul Munaf Saud,

Assistant Professor, Department of Orthopedic Surgery, Quaid-e-Azam Medical College, Bahawalpur

QR code

Please cite this article in press Abdul Munaf Saud et al., ***Study Of Functional Outcome Of Reverse Locking Plate In Extra-Capsular Fractures Of The Proximal Femur.,*** *Indo Am. J. P. Sci, 2020; 07(01).*

INTRDUCTION:

Hip fractures in the elderly occur in significant numbers, with 1.6 million fractures worldwide annually and a projected increase to over 6 million hip fractures yearly by 2050.[1] Hip fractures can be broken down into two generic categories: intracapsular and extracapsular, depending on where the fracture occurs about the proximal femur. Femoral neck fractures are classified as intracapsular, while extracapsular hip fractures can be further broken down into intertrochanteric and peritrochanteric, with possible subtrochanteric extension depending on the fracture line exit point about the greater and lesser trochanters.[2] An accepted terminology to encompass all extracapsular hip fractures is peritrochanteric femur fracture, with the fracture occurring about the greater and lesser trochanter and not extending greater than 5cm from the lesser trochanter.[3]

Every proximal femur fracture must be assessed individually and it will be irrational to establish fixed routines of treatment. Numerous difficulties may arise in the management of unstable intertrochanteric fractures because of the degree of osteoporosis, reverse obliquity of the fracture line, comminution on the medial side.[4]

By using proximal femur nails, better functional outcome can be achieved as compared to dynamic hip screw.[5] The intra-medullary locked nailing was technically demanding in proximal femur fractures and may result in iatrogenic propagation of the fracture with the risk of varus malunion.[6]

The main advantages gained after use of reverse distal femoral locking compression plate are the plate and screw form a stable construct and the stability of the fracture depends on the stiffness of the construct. There is improved stability in multi-fragmentary compressed fractures with loss of medial/lateral buttress or bone loss.[7-9] In unstable proximal femur fractures that were difficult to nail and were therefore, were managed with reverse distal femoral locking plate was observed that the complications like pain, delayed union were less frequent.[4]

MATERIAL AND METHODS:

This cross sectional study was conducted at Department of Orthopedic Surgery, Civil Hospital, Bahawalpur from January 2018 to December 2018 over the period of 1 year. Study was approved by the ethical committee and written informed consent was taken from every patient.

Total 17 patients with extra-capsular fracture of proximal femur with one or more of the following: unstable fracture pattern, bowed femur, deformed femur, short skeleton, narrow femoral canal (diameter <8mm), open fracture presenting within 24 hours having age 10-80 years either male or female were selected for this study.

After the initial resuscitation, all patients were assessed in details for any other injuries and medical ailments and managed accordingly. Pre-operative investigations and pre-anaesthetic checkup was done.

The surgery was conducted under anesthesia, with the patient in the supine position on radiolucent table with traction attachment. Traction was applied to the injured leg by a padded holder on the foot. A padded perineal post was used for counter traction. The unaffected limb was placed in hip abduction and knee flexion. An accurate closed reduction was done under fluoroscopic control and maintained by traction with a boot.

The reverse locking plates are separately available for right and left side and in various lengths. The reverse locking plate is pre-shaped to account for the anterior bow of the shaft zone of the femur. A contralateral side distal femoral locking plate was used 'upside down' for stabilization of the proximal femur fracture. Depending on the patient's body habitus, a 2.5-8 cm incision was given just proximal to the greater trochanter, and taken to the level of the fascia. Submuscular plane was developed under vastus lateralis and reverse locking plate was inserted submuscularly across the fracture site while maintaining slight contact with the bone under image guidance. In cases where closed reduction fails, open reduction was carried out by extending down incision over the middle of greater trochanter to the lateral side of the thigh over lateral aspect of femur in standard manner. The length of the incision varied with the requirements of the surgery. After ensuring an optimal placement of the plate on the femur, it was temporarily fixed to the bone with Kirschner wire via proximal and distal connected trocars. In closed procedures, position of the reverse locking plate was checked again radiographically before inserting. Thereafter first non-locking screw was inserted and then locking head screws using the appropriate drill bits were inserted. To ensure secure fixation, four to six screws were placed into the proximal component of the fracture and three to four screws were placed into the distal component of the fracture. Optimal placement and screw length was ensured under fluoroscopy in two planes. Finally, the incisions in the vastus fascia were closed with or without drainage, in the standard fashion.

Post-operatively, non-weight-bearing toe-touch ambulation was started as soon as pain was bearable. Check X-rays were done at regular intervals. More than 50% visible bridging callus across the fracture on plain radiograph was regarded as indicator of fracture healing. Neck shaft angle was measured post operatively and at follow-up visits. Complications like non-union, shortening, infection were recorded.

All the collected data was entered in SPSS version 20 and analyzed. Mean and SD was calculated for numerical data and frequencies were calculated for categorical data.

RESULTS:

Total 17 cases of proximal femur fracture were enrolled in the study. In our study, there were 6 sub-trochanteric and 11 inter-trochanteric fractures. Total 4 out of 6 sub-trochanteric fractures were under 40 years age and 9 out of 11 intertrochanteric fractures were over 40 years age. There were 14 male and 3 female patients. The age distribution of the patients is shown in Figure 1.

In 8 out of 17 patients, the duration of surgery was more than 2 hours. The mean duration of surgery in inter-trochanteric fractures was 135 ± 24.8 minutes and for sub-trochanteric fractures was 115 ± 22.8 minutes.

Total 15 out of 17 patients attended follow-up for a minimum of 1 year. Partial weight bearing walking was started at 2 months in 6 patients, 3 months in 4 patients and at more than 4 months in 3 patients. Full weight bearing walking was started at 5 months in 11 patients, at 9 months in 3 patients and at 1 year in 1 patient, as explained in Figure 2.

One patient had early infection, which was managed with debridement and IV antibiotics. Early loss of fixation and wound breakdown was seen in one patient, which was managed with IV antibiotics and skeletal traction. Hip flexion was >90º in 11 patients, hip abduction was >20□ in 12 patients. Internal rotation was >15º in 9 patients and external rotation was >15º in 13 patients.

One patient, who had loosening of the screw and persistent pain on lateral thigh, achieved bony union after 9 months. One patient had shortening of about 2 cm with varus angulation due to ipsilateral shaft femur tibia fracture and early weight bearing. This patient had stiffness of the knee joint due to retrograde intramedullary nailing for shaft femur and nailing for tibia. One more patient had shortening of <1 cm along with varus malunion. Stiffness of hip was noted in one patient as the patient had associated secondary degeneration of bilateral hip joints, which required rigorous physiotherapy. The delayed complications are described in Table 1. Distribution of subjects according to Palmer and Parker mobility score was shown in table 2

Figure 1: Age distribution of patients

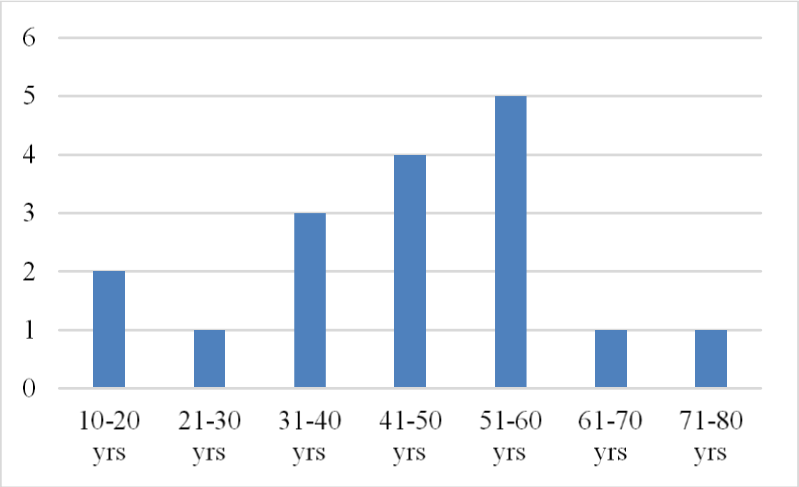

Figure 2: Distribution according to full weight bearing walking

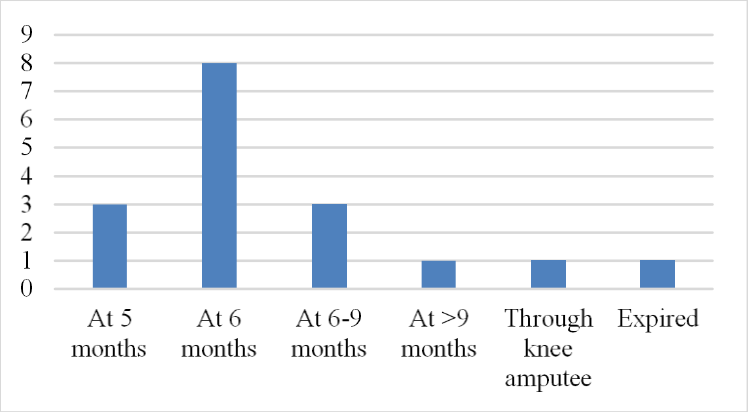

Table 1: Delayed complications.

Delayed complications	No. of patients
Delayed infection	1
Shortening	2
Loosening of screws	1
Stiffness of hip	1
Knee stiffness	1
Delayed union	5
Varus angulation	2
Implant breakage	0

Table 2: Distribution of subjects according to Palmer and Parker mobility score.

Functional results	Subtrochanteric fractures	Intertrochanteric fractures	Total
	N (%)	N (%)	N (%)
9	5 (83.33)	7 (63.64)	12 (70.59)
6-8	1 (16.67)	3 (27.27)	4 (23.53)
3-5	0 (0.00)	0 (0.00)	0 (0.00)
<3	0 (0.00)	0 (0.00)	0 (0.00)
Expired	1 (0.00)	1 (9.99)	1 (5.88)

DISCUSSION:

While there are several methods for fixation of hip surgery, the optimal method is unclear because of high rate of complications in all the methods. Fixation of hip fracture with plating is a good method for inter-trochanteric femur. But intramedullary nailing is becoming popular. So we reviewed the literature to look for new recommendations for hip fracture fixation.

Kummer et al compared intramedullary hip screw system and extra-medullary screw plate system. They found similar stability for fixation of two part and three part sub-trochanteric fractures.[10]

Simmermacher et al observed that the intramedullary devices for the treatment of unstable trochanteric femoral fractures were technically demanding and had considerable failure rate.[11] Kish et al concluded that PFN (proximal femoral nail) allowed full weight bearing immediately after surgery and it appears advantageous compared the DHS (dynamic hip screw).[12] Jeffrey et al noted that the patients with intra-medullary nailing had more procedure related complications.[13] Yao et al compared reverse less invasive stabilization system (LISS) plating to intramedullary nailing and concluded that reverse LISS plating be reserved for

rapid fixation and damage control in poly trauma patients.[14]
Ning et al concluded that LISS plating may be indicated for patients with very severe osteoporosis.[15] Lewis et al, Ozkaya et al, Zhang et al concluded that reverse LISS plating for intertrochanteric hip fractures is a safe and alternative method.[6,16,17]

In our study, the average duration of surgery was 127 ± 25 minutes, which is longer than that reported in others (average 60-70 minutes).[4,15] However in both the studies, distal targeting system was used. In our study, most of the fractures were stabilized by open method, which had no distal targeting device.

Chang et al reported a series of 20 patients had an average operating time of 115 minutes which is almost similar to our study.[18] The variation in duration of surgery can be attributed to learning curve, implant design, operation room set-up and familiarity of staff with the procedure.

Partial weight bearing (PWB) walking was started after clinical and radiological progress of the fracture. French et al started PWB walking in their patients when there was bridging callus in one view of the follow-up X-rays.[19] Similar protocols of physiotherapy were found to be followed by other authors.[4,6]

According to Parker mobility criteria, 12 patients scored 9 points and 4 patients had 6 points at final assessment performed at 1 year after fracture fixation. Our mobility score was comparable with Ning et al (average mobility score 8.25 vs. 8.11 ± 0.8) and slightly lower as compared to Ching et al (8.55 vs. 8.25) as this study had no patient with ipsilateral amputation at the final follow-up.[4,15] On excluding this patient, our average mobility score was 8.4, which is more nearer to that reported by Ching et al.[4]

The average post-operative neck shaft angle was 130.2 ± 6.38 degrees, which is less than as compared to other authors.[4,18] This could be due to excessively comminuted fractures and varus malunion in two patients. The mean time to fracture union was 6.43 ± 1.18 months, which is similar to 6-6.5 months as observed in other studies.[15,6]
One patient had superficial surgical site infection, which healed with IV antibiotics, debridement and dressings. Another patient had an infection leading to implant loosening and loss of reduction. The infection rate was higher as compared to other studies.[4,18] This could be attributed to their poor nutritional status.
Shortening of 2 cm and varus malunion was observed in one patient. This was due to lack of compliance by the patient and early mobilization. No screw breakage was reported. This is comparable to Ching et al.[4]
One patient had screw loosening but fracture union was achieved in 6 months without any secondary procedures. No implant breakage was observed in our study. No medical complications were noted perioperatively in this study.

Though all the fractures in our study healed, it is hard to say that reverse distal locking plate is substantial enough in highly unstable fractures since the small sample of our study could prevent us from observing more complications. At last, we conclude that the reverse distal femur locking plate is a good alternative to stabilize the unstable proximal fractures especially when used in conjunction with careful preoperative planning, meticulous intra-operative handling of soft tissues and active participation of the patients in rehabilitation program.

CONCLUSION:

From this study, we conclude that unstable fractures unite satisfactorily within reasonable period of time by use of reverse distal femur locking plate. There were fewer complications, early mobilization and high patient satisfaction. Reverse distal femoral locking plate is a treatment option that needs to be evaluated further in order to recommend this surgery for specific subset of patients with hip fractures. In initial studies, the results have been encouraging and patient satisfaction achieved. Further studies to look into the biomechanical aspects of reverse distal femur locking plate and the clinical outcome of the surgery should be done. This will allow well formulated indications and contra-indications for the surgery.

REFERENCES:

1. Babcock S, Kellam JF. Hip fracture nonunions: diagnosis, treatment, and special considerations in elderly patients. Advances in orthopedics. 2018;2018.
2. Evans PJ, McGrory BJ. Fractures of the proximal femur. Hospital Physician. 2002;30-8.
3. Austin CA, Lawson PJ, Gibson R, Philp I. Proximal femoral fracture: achievements and prospects. Age Ageing. 1998;27:667-70.
4. Ma CH, Tu YK, Yu SW, Yen CY, Yeh JH, Wu CH. Reverse LISS plates for unstable proximal femoral fractures. Injury. 2010;41:827-33.
5. Panjarinen J, Lindahl J, Michelsson O, Savolainen V, Hirvensalo E. Pertrochanteric femoral fractures treated with a dynamic hip

screw or a proximal femoral nail. J bone Joint Surg (Br). 2005;87:76-81.
6. Zhang CQ, Sun Y, Jin DX, Yao C, Chen SB, Zeng BF. Reverse LISS plating for intertrochanteric Hip Fractures in elderly patients. BMC Musculoskelet Disord. 2010;11;166.
7. Smith WR, Ziran BH, Anglen JO, Stahel PF. Locking plates: tips and Tricks. J Bone Joint Surg Am. 2007;89:2298-307.
8. Sommer C, Gautier E, Muller M, Helfet DL, Wagner M. First Clinical results of the locking Compression Plate (LCP). Injury. 2003;34(l2):43-54.
9. Wagner M. General principles for the clinical use of the LCP. Injury. 2003;34(2):31-42.
10. Kummer FJ, Olsson O, Pearlman CA, Cedar L, Larsson S, Koval KJ. Intramedullary versus extramedullary fixation of subtrochanteric fractures. A biomechanical study. Acta Orthop Scand. 1998;69(6):580-4.
11. Simmermacher RK, Bosch AM, Van der WC. The AO/ASIF-proximal femoral nail (PFN): A new device for the treatment of unstable proximal femoral fractures. Injury. 1999;30:327-32.
12. Kish B, Sapir O, Carmel A, Regev A, Masrawa S. Full weight bearing after unstable per and subtrochanteric fracture using proximal femur nail. J Bone Joint Surg Br. 2001;83(3):289.
13. Anglen JO, Weinstein JN. Nail or plate Fixation of Intertrochanteric Hip Fractures: Changing Pattern of Practice. A Review of the American Board of Orthopaedic Surgery Database. J Bone Joint Surg Am. 2008;90:700-7.
14. Yao C, Zhang CQ, Jin DX, Chen YF. Early results of reverse less invasive stabilization system plating in treating elderly intertrochanteric fractures: a prospective study compared to proximal femoral nail. Chin Med J (Engl). 2011;124:2150-7.
15. Ning H, Gui XS, Zeng CL, Guo FL, Qing YL, Qing HH, Xin W. Comparison of proximal femoral nail antirotation blade and reverse less invasive stabilization system–distal femur systems in the treatment of proximal femoral fractures. Orthopaedic Sur. 2011;3(1):7-13.
16. Lewis JRP, Ashcroft GP. Reverse LISS plating for proximal segmental femoral fractures in the polytrauma patient: a case report. Injury. 2007;38(2):235-9.
17. Ozkaya U, Bilgili F, Kilic, Parmaksizoglu AS, Kabukcuoglu Y. Minimally invasive management of unstable proximal femoral extracapsular fractures using reverse LISS femoral locking plates. Hip Int. 2009;19(2):141-7.
18. Oh CW, Kim JJ, Byun YS, Oh JK, Kim JW, Kim SY, Park BC, Lee HJ. Minimally invasive plate osteosynthesis of subtrochanteric femur fractures with a locking plate: a prospective series of 20 fractures. Arch Orthop Trauma Surg. 2009;700-21.
19. French BG, Tornetta P. Use of interlocked cephalomedullary nail for subtrochanteric fracture stabilization. Clin Orthop Relat Res. 1998;(348):95-100.