



CODEN [USA]: IAJ PBB

ISSN: 2349-7750

**INDO AMERICAN JOURNAL OF
PHARMACEUTICAL SCIENCES**<http://doi.org/10.5281/zenodo.1323730>Available online at: <http://www.iajps.com>**Research Article****RECENT ADVANCEMENTS IN THE TREATMENT OF
METASTATIC MALIGNANT MELANOMA****Dr. Unaiza Faizan**

Mayo Hospital Lahore, Pakistan

Abstract:

The incidence and mortality rates of melanoma have increased at annually. Disseminated disease is largely refractory to cytotoxic chemotherapy and is almost universally fatal. Several recent advances in melanoma biology offer new strategies for potentially treating this aggressive malignancy. This review focuses on the significant advances involving tumor initiation, etiology, and progression. New experimental models reveal a direct role for initiating melanomas in human skin. Studies on E- and N-cadherin elucidate the importance of local homeostatic mechanisms in regulating tumor progression. Finally, several discoveries concerning apoptotic mechanisms in melanoma suggest strategies for future treatments.

Keywords: *Melanoma, Tumor Initiation, Malignancy, Cancer, Immunotherapy, Apoptotic Mechanisms,*

*** Corresponding author:****Dr. Unaiza Faizan**

Mayo Hospital,
Lahore,
Pakistan

OR code

Please cite this article in press Unaiza Faizan., *Recent Advancements in the Treatment of Metastatic Malignant Melanoma.*, Indo Am. J. P. Sci, 2018; 05(07).

INTRODUCTION:

Cancer has been one of the major health concerns over the past few decades. A disease which was once considered incurable is now been treated and cured, all due to the efforts of the scientific community which has been working day in and day out to find new and better ways to cure cancer. Their efforts have brought revolutionary changes in the treatment options for cancer. One of such cancers is melanoma, a tumor arising from pigment producing cells called melanocytes [1]. It is usually discovered by the patient as a dark pigmented, irregular patch on the skin. Definite diagnosis is made only on histopathology; like all other cancers. Individuals with mutations in MAPK/ERK pathway are genetically prone to develop melanoma. This pathway is involved in the growth and development of the melanoma cells. Others at a higher risk include fair-skinned people (Caucasians and albinos) and those who are extensively exposed to UV radiation of the sunlight (farmers, athletes, surfers etc.) [2]. Melanoma although rare as compared to the non-melanoma skin cancers but is the most notorious all of due to its rapid rate of division and distant metastasis. Most common sites of metastasis include liver, lung, bone and brain. The recent advancements in the treatment of melanoma has made a prolonged tumor free time achievable. Treatment modality mainly depends on the stage of the disease. Surgical removal of the tumor has been the mainstay of treatment for stage 0, I and II. Stage III (irresectable) and stage IV are treated by surgically removing the disease and administering a systemic therapy.

MATERIAL AND METHODS:

Prior to the development of targeted therapy and immunotherapy, the options for systemic therapy were limited. Mutant patients can greatly benefit from targeted therapies as these therapeutic agent's act on mutated cells only. While those in which no targetable driver mutation is present they are treated with check point inhibition immunotherapy. Targeted drugs include inhibitors of KIT, RAS, BRAF, MEK and ERK proteins, these agents act on a specific protein in the signal transduction pathway inhibiting

them hence slowing down the proliferation of the tumor. Many drugs of this group have been approved by the FDA for the treatment of metastatic malignant melanoma.

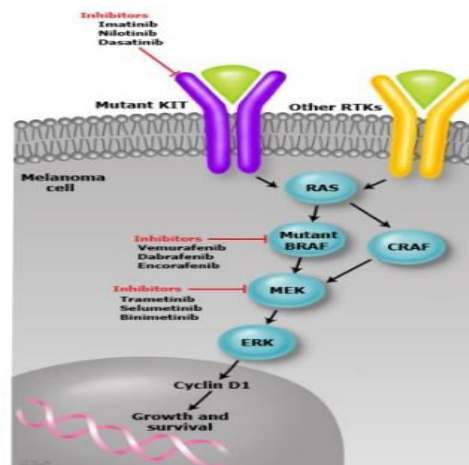
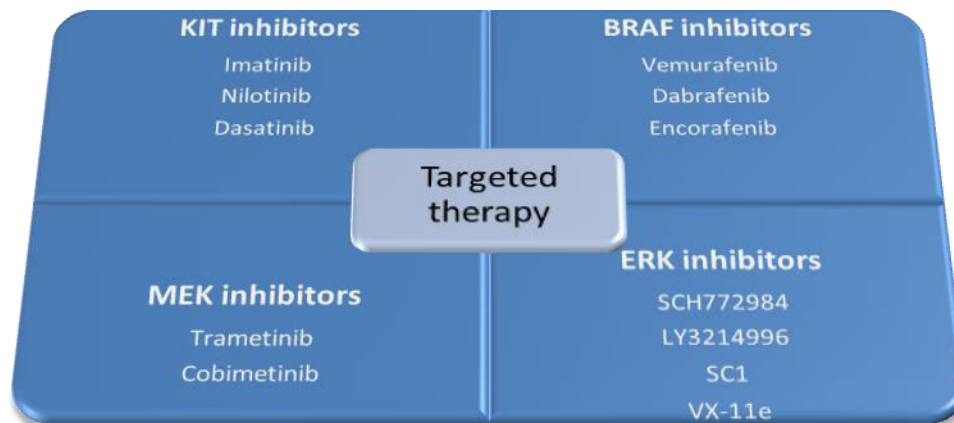


Figure 1. MAPK/ERK signal transduction pathway

KIT mutations occur in 2-8% of all melanoma, being more common in acral and mucosal subtypes. KIT receptor is a trans-membrane protein which when mutated activates the MAPK/ERK pathway, enhancing the DNA transcription, which results in the uncontrolled division of melanoma cells. Most of the mutations occur in exon 11 and 13 encoding for juxtamembrane and kinase domains respectively. Dasatinib (Sprycel), Imatinib (Gleevec), and Nilotinib (Tasigna) are some of the available KIT inhibitors. Imatinib is used for the treatment of c-KIT mutated malignant melanoma and has given promising results as it has shown that more than 50% of c-KIT mutated melanomas respond to Imatinib mesylate. In a cohort study done on 51 patients having c-KIT mutated melanoma, 16% had a durable response. In another phase II trial 43 patients carrying c-KIT mutated melanoma were enrolled out of which 23% had an objective response to imatinib. Nilotinib is used in imatinib resistant chronic myeloid leukemia and is currently under study as a possible treatment option for imatinib resistant c-KIT mutated melanoma.



BRAF mutated melanoma is the most common of all accounting for almost 80% of all melanoma. V600E and V600K are most frequently seen, patient having tumor that contains these mutations can greatly benefit from BRAF inhibitors [3]. These include vemurafenib and dabrafenib, which were approved by federal drug authority (FDA) in 2011 for the treatment of metastatic malignant melanoma. These drugs have shown exceptional results on BRAF mutated tumors including early regression of the tumor and prolonged survival of the patient. Both these drugs were compared to an older chemotherapeutic agent dacarbazine in two separate phase III trials. In one of those trials 337 patients were administered vemurafenib while 338 were given dacarbazine; the results showed a prolonged overall survival for vemurafenib (13.2 months compared to 9.6 months for those on dacarbazine) [4]. As for dabrafenib, the progression free survival was 5.1 months as compared to 2.7 months with dacarbazine. Another astonishing result was the shrinkage of tumor in 52% of the patients on dabrafenib as compared to 17% of those on dacarbazine. Most common side effect experienced by patients on Zelboraf (vemurafenib) is the development of squamous cell carcinoma (occurs in almost 24% of patients) this can be surgically removed without discontinuation of the therapy. Patients on Zelboraf are advised to get regular dermatological checkup every 2 months while on therapy. Another frequently seen side effect is skin allergy in the form of itching and rash. Some people may also experience photosensitivity, it is suggested that the patient

avoids sun as much as possible, covers up skin with clothing and use sun screen while exposed to the sun. Less frequently occurring side effects include prolongation of QT interval, drug induced hepatitis, uveitis and alopecia [5].

Patients on dabrafenib may experience fever, the most common side effect, occurring in almost 28% of patients on therapy. This is managed symptomatically until associated with hemodynamic instability or other complications. Patients may develop new primary tumors (including squamous cell carcinoma) hence regular skin examination should be done, preferably every 2 months while on therapy and up to 6 months after discontinuation of the drug. Other frequently seen adverse effects include diabetes mellitus (high blood glucose levels) and eye problems including uveitis and conjunctivitis. a study conducted in japan showed that BRAF and MEK inhibitors when used in combination had a higher response rate (60-70%) [6].

RESULTS:

MEK inhibitors include trametinib and comitenib approved by FDA in 2013 and 2015 respectively. Trametinib is used in combination with dabrafenib while cometinib is used in combination with vemurafenib (both BRAF inhibitors) in the treatment of unresectable and metastatic melanoma containing BRAF V600E or V600K mutations. Trametinib when compared to standard chemotherapy in a trial proved to be far superior with a progression free survival of

4.8 months and tumor shrinkage in 22% of the patients as compared to 1.5 tumor free survival and tumor shrinkage in only 8% of patients on standard chemotherapy. Side effects include dermatological toxicity occurring in almost 87% of the patients, cardiac toxicity and eye problems. Patient on therapy should get regular dermatological, cardiac and ophthalmological follow ups for timely recognition

of the side effects and prompt treatment. Those on comitinib and vemurafenib combination therapy may experience skin rash, photosensitivity, new onset skin cancers, increased bleeding tendency, retinal damage and elevated CPK levels. It should be made sure that female patients on targeted therapy are not planning to get pregnant before or during the therapy.

DRUG	CLASS	DOSE
Vemurafenib	BRAF inhibitor	960mg twice daily
Dabrafenib	BRAF inhibitor	150mg twice daily
Trametinib	MEK inhibitor	2mg once a day
Cobimetinib	MEK inhibitor	60mg once a day for the first 21 days of each cycle consisting of 28 days

Table 1. Targeted therapies and their dosage.

Table 2. List of FDA approved therapies.

Drug	Approved in	For treatment of
<i>Nilotinib</i> (KIT inhibitor)	2010	<ul style="list-style-type: none"> Ph+ CML in chronic phase
<i>Dasatinib</i> (KIT inhibitor)	2010 (first approved in 2006 for imatinib resistant CP-CML) 2017	<ul style="list-style-type: none"> Ph+ CML in chronic phase in adults (dose:100mg once a day) Ph+ CML in chronic phase in pediatric patients
<i>Ipilimumab</i> (CTLA 4 inhibitor)	2011 2015	<ul style="list-style-type: none"> Unresectable/metastatic melanoma As adjuvant therapy for cutaneous melanoma with lymph node involvement of more than 1mm after complete resection which involves total lymphadenectomy
<i>Peginterferon alpha 2 b</i>	2011	<ul style="list-style-type: none"> Melanoma with lymph node involvement within 84 days of complete surgical removal
<i>Vemurafenib (Zelboraf)</i> (BRAF inhibitor)	2011 2017	<ul style="list-style-type: none"> Unresectable/metastatic melanoma with BRAF V600E mutation Erdheim-Chester disease with BRAF V600E mutation
<i>Imatinib mesylate</i> (KIT inhibitor)	2012	<ul style="list-style-type: none"> KIT+ Gastrointestinal stromal tumor
<i>Dabrafenib</i> (BRAF inhibitor)	2013 2017	<ul style="list-style-type: none"> Unresectable/metastatic melanoma with BRAF V600E mutation To be used in combination with trametinib for metastatic non-small cell lung cancer having BRAF V600E mutation

<i>Trametinib</i> <i>(MEK inhibitor)</i>	2013	<ul style="list-style-type: none"> • Unresectable/metastatic melanoma with BRAF V600E or V600K mutation
	2014	<ul style="list-style-type: none"> • Approved to be used in combination with dabrafenib for BRAF V600E or V600K mutated metastatic melanoma
	2015	<ul style="list-style-type: none"> • Accelerated approval for using it in combination with dabrafenib for unresectable/metastatic melanoma with BRAF V600E or V600K mutation
<i>Nivolumab</i> <i>(PD 1 inhibitor)</i>	2014	<ul style="list-style-type: none"> • Unresectable/metastatic melanoma following treatment with ipilimumab or BRAF inhibitor (if BRAF mutated)
	2015	<ul style="list-style-type: none"> • Approved to be used in combination with ipilimumab in BRAF wild type melanoma
	2015	<ul style="list-style-type: none"> • Non-small cell lung carcinoma
	2015	<ul style="list-style-type: none"> • Renal cell carcinoma previously treated with anti-angiogenic therapy
	2016	<ul style="list-style-type: none"> • Classical Hodgkin lymphoma
	2016	<ul style="list-style-type: none"> • For treatment of renal cell carcinoma, metastatic melanoma and non-small cell lung cancer at dose of 240mg intravenous 2 weekly
	2016	<ul style="list-style-type: none"> • Head and neck squamous cell carcinoma resistant to platinum based chemotherapy
	2017	<ul style="list-style-type: none"> • Advanced urothelial carcinoma resistant to platinum based chemotherapy
	2017	<ul style="list-style-type: none"> • For MSI-high or d MMR colorectal carcinoma previously treated with fluropyrimidine, oxaliplatin and irinotecan
	2017	<ul style="list-style-type: none"> • As adjuvant therapy for melanoma with lymph node involvement or metastatic disease with complete resection

<i>Pembrolizumab</i> <i>(PD 1 inhibitor)</i>	2014	<ul style="list-style-type: none"> • Unresectable/metastatic melanoma following treatment with ipilimumab or BRAF inhibitor (if BRAF mutated)
	2015	<ul style="list-style-type: none"> • Non-small cell lung carcinoma that expresses PDL1 resistant to platinum based chemotherapy
	2015	<ul style="list-style-type: none"> • As single agent therapy in unresectable/metastatic melanoma
	2016	<ul style="list-style-type: none"> • Head and neck squamous cell carcinoma resistant to platinum based chemotherapy
	2016	<ul style="list-style-type: none"> • Non-small cell lung carcinoma
	2017	<ul style="list-style-type: none"> • Refractory classical Hodgkin lymphoma
	2017	<ul style="list-style-type: none"> • to be used in combination with penmetrexed and carboplatin in untreated metastatic non squamous non-small cell lung cancer
	2017	<ul style="list-style-type: none"> • Advanced urothelial carcinoma resistant to platinum based chemotherapy
	2017	<ul style="list-style-type: none"> • Unresectable/metastatic MSI-high or d MMR solid tumors/colorectal carcinoma previously treated
	2017	<ul style="list-style-type: none"> • Esophageal adenocarcinoma which express PD-L1
<i>Talimogene Laherparepvec</i>	2015	<ul style="list-style-type: none"> • Oncolytic viral therapy as local therapy for unresectable melanoma lesions
<i>Cobimetinib (MEK inhibitor)</i> <i>(in combination with vemurafenib)</i>	2015	<ul style="list-style-type: none"> • Unresectable/metastatic melanoma with BRAF V600E and V600K mutation
<i>Atezolizumab</i> <i>(PD L1 inhibitor)</i>	2016	<ul style="list-style-type: none"> • Advanced urothelial carcinoma resistant to platinum based chemotherapy
<i>Avelumab</i> <i>(PD L1 inhibitor)</i>	2017	<ul style="list-style-type: none"> • Metastatic Merkel cell carcinoma

Ph+=Philadelphia chromosome positive, CML= Chronic myeloid leukemia

Immune check point inhibitors have revolutionized the systemic therapy for metastatic malignant melanoma, these therapeutic agents act on down regulatory T cell receptors and block them. Blockage of the receptors prevent the “switching off” of the T cells and hence produce appropriate response needed to eliminate the tumor cell [7]. One such receptor is the CTLA 4 receptor present on the surface of T cells which when activated down modulates the immune response letting the tumor cell escape the natural immune surveillance. A study done by Yun S. et al suggests that immunotherapy gives superior results versus older chemotherapeutic agents with progression-free survival (PFS) rate at 6 months of 28.5% compared to 17.7% (RR: 0.84, 95% CI: 0.76-0.93), overall survival (OS) rate at 1 year of 51.2% compared to 38.8% (RR: 0.72, 95% CI: 0.59-0.88), and overall response rate (ORR) at 6 months of

29.6% compared to 17.7% (RR: 0.85, 95% CI: 0.76-0.95) [8].

Ipilimumab an IgG1 type monoclonal antibody was approved by FDA under the trade name of Yervoy in 2011 it acts on the CTLA 4 receptors on T cells and inhibits them. Ipilimumab showed improved survival in patients with metastatic disease compared to older systemic therapies . Two phase III trials proved ipilimumab to increase overall survival rates in patients with advanced disease. In a randomized trial, 676 patients who had already received systemic therapy with older chemotherapeutic agents were randomly placed in three groups. Each group received a different treatment. Ipilimumab alone, glycoprotein 100(gp100) vaccine alone or both combined. The results showed that patients receiving ipilimumab alone had a better survival rate compared

to the other two groups. In another phase III trial, 502 previously untreated patients with metastatic melanoma were randomly placed in two groups. One group received ipilimumab and dacarbazine and the other received a placebo and dacarbazine. Results showed that patients receiving ipilimumab had better survival rates compared to those receiving placebo. Along with better survival rates ipilimumab receiving patients also had a prolonged tumor free period. The response of tumor cells to ipilimumab is directly proportional to the dose of the drug given ie on higher dose the response is better but as the dose is increased the frequency of immune related adverse effects also increase [9].

PD-1 receptor (programmed cell death receptor) is present on T cell and is activated when it interacts with PD-L1 (the receptor's ligand). This too is a down regulatory receptor which when activated initiates a cascade of changes within the T cells that result in a diminished immune response. Inhibitors of both PD-1 and PD-L1 are therapeutically used to achieve one goal, that is to block the activation of the PD-1 receptor. PD-L1 is usually over expressed on tumor cells and is even elevated in plasma of patients with melanoma [10]. We can conclude that activation of PD-1 receptor is one of the survival strategy of the tumor cells. FDA has approved two PD-1 and three PD-L1 inhibitors for the treatment of unresectable melanoma. Pembrolizumab an IgG4 monoclonal antibody is used in treatment of metastatic

melanoma, non small cell lung carcinoma, metastatic head and neck squamous cell carcinoma, advanced urothelial carcinoma, refractory hodgkinlymphoma, esophageal adenocarcinoma and any solid tumor or colorectal carcinoma containing micro satellite instability high (MSI-high) or mismatch repair defect (d MMR). In a phase III KEYNOTE-006 study pembrolizumab proved to be far superior to ipilimumab, and it came forward as the standard treatment for advanced melanoma [11].

Nivolumab is also an IgG4 humanized monoclonal antibody that acts on PD 1 but because these two are of the same pharmacological group these are never given in combination. Nivolumab is given along ipilimumab in patients with BRAF wild type melanoma. It is used as a first line treatment in malignant melanoma not containing BRAF mutation and as a second line drug in patients with malignant melanoma containing BRAF mutation. A survey done in England proved that nivolumab monotherapy is the most cost effective of all. These drugs have shown promising results improving survival rates with fewer side effects compared to CTLA4 inhibitors [12]. PD L1 inhibitors include Atezolizumab and avelumab which are approved by FDA for the treatment of advanced urothelial carcinoma and metastatic Merkel cell carcinoma respectively. These agents are currently studied in trials as potential treatment for metastatic melanoma.

Table 3. Immune check point inhibitors and their dosage.

DRUG	CLASS	DOSE
Ipilimumab	CTLA 4 inhibitor	3mg/kg given intravenously over 90 minutes, 3 weekly, total of 4 doses
Pembrolizumab	PD 1 inhibitor	2mg/kg given intravenously over 30 minutes, 3 weekly
Nivolumab	PD 1 inhibitor	240mg given intravenously Over 60 minutes, 2 weekly

All immune check point inhibitors can result in immune related adverse effects (IrAEs) these adverse effects occur in result of over activation of T cells which start acting against normal cells and destroy them in result. A meta analysis show that <75% of patients on CTLA 4 therapy experience these side effects. IrAEs occurring with CTLA 4 inhibitors are diverse and often severe which is one of the reasons ipilimumab has lost its popularity after the development of PD-1 inhibitors. The results of a phase III trial state that <30% of patients on PD1/PDL1 therapy develop these side effects, these are often mild to moderate and are easily managed.the severity of immune related side effects is determined by sorting them out into grades. The severity increases as the grade does [13].

Table 4. Grades of IrAEs.

ADVERSE EFFECT	GRADE 1	GRADE 2	GRADE 3	GRADE 4
Dermatological	Mild to moderate localized rash/pruritis/papules/pustules Covering , 10- 30% of the body surface	Nonlocalized diffuse rash covering <50%of body surface	Intense rash >30% Skin sloughing <10-30% Epidermal or mucosal surface detachment	Steven johnson syndrome Toxic epidermal necrolysis Full thickness skin ulcertaion, necrosis, bulla or hemmorhage
Diarrhea (baseline bowel habits should be known)	Increased frequency of stools <4 per day over baseline Mild increase in ostomy output over baseline	Increased frequency of stools 4-6 per day over baseline Moderate increase in ostomy output over baseline Not interfering with ADL	Increased frequency of stools >7 per day over baseline Severe increase in ostomy output over baseline Interfering with ADL Hospitalization required	Life threatening complication; including hypotension , hemodynamic collapse and acute renal filure
hepatotoxicity	Assymptomatic or mild symptoms	Liver enzymes (AST and ALT) >2.5 to 5 times the upper normal limit And/or total bilirubin >1.5 to 3 times the upper normal limit	Liver enzymes (AST and ALT) > 5 times the upper normal limit And/or total bilirubin > 3 times the upper normal limit	Encephalopathy Abnormally elevated plasma levels of LDH, ALP and ammonia
Endocrine toxicity	Assymptomatic or mild symptoms	Moderate symptoms that need medical intervention	Severe symptoms requiring hospitalization	Life threatening consequences including adrenal crisis, hypotension, shock and dehydration.

ADL= Activities of daily living, AST= Aspartate aminotransferase, ALT= Alanine aminotransferase, ALP= Alkaline phosphatase

It is seen that the percentage of severe adverse effects (grade 3 or above) occur more commonly in patients on ipilimumab compared to PDI/PDL1 inhibitors, 43% compared to only 20% to be precise. Immune mediated adverse effects commonly involve skin, gut, endocrine, musculoskeletal and pulmonary tissues. Cardiovascular, renal, neurological and ophthalmoc side effects also occur but are less frequent. These adverse effects may have a delayed onset and a prolonged duration as compared to the side effects occurring after chemotherapy. These are usually treated by administering steroids (immunosuppressants) and rarely by discontinuation of the drug. Corticosteroids can be given orally or intravenously but their prolonged use can result in

development of diabetes mellitus, hypertension, osteoprosis and immunosuppression [14]. Patients on immunosuppressant therapy are often given prophylactic antibiotics and supplements of calcium and vitamin D. National Cancer Institute (NCI) and National Institute of Health (NIH) came up with "Common Terminology Criteria for Adverse Effects" (CTCAE). The main idea behind it was to standardize the severity of adverse effects but this criteria has a lot of limitations when it comes to the adverse effects of immunotherapy specially rheumatological and dermatological IrAEs. The society for immunotherapy of cancer (SITC) met in a workshop last year to develop management strategies for the immune mediated drug side effects. A diverse group

of professionals took part in the workshop including medical oncologists, surgeons, pharmacists, nurses, disease subspecialists, and safety experts [15]. These were divided into groups and were assigned one group of IrEAs each, they conducted discussions within the group and then one representative who

was selected by the group presented the recommendations made regarding the monitoring and management of that group of toxicities. Guidelines for general use of corticosteroids recommended is shown in the table below.

Table 5. General recommendations by SITC on corticosteroid use.

GRADE OF IrEA	CORTICOSTEROID MANAGEMENT	IMMUNOTHERAPY
1	Not required	Continue therapy
2	Oral prednisone 0.5mg/kg/day If IV required then methylprednisolone 0.5-1mg/kg/day If no improvement after 2-3 days increase dose of prednisone to 2mg/kg/day Once grade of IrEA <1 start tapering steroids over 4 to 6 weeks	Temporarily hold therapy Continue therapy once IrEA is <1 grade Give PPI for GI prophylaxis
3	Oral prednisone 1-2mg/kg/day If IV required then methylprednisolone (equivalent) If no improvement after 2-3 days add additional immunosuppressants Once grade of IrEA <1 start tapering steroids over 4 to 6 weeks Supportive medical therapy if required	Temporarily hold therapy, but if symptoms do not improve even after 4-6 weeks of steroid therapy then discontinue permanently Give IV corticosteroids Give PPI for GI prophylaxis If more than 3 weeks of corticosteroids given (or equivalent of 30mg prednisone/day) give PCP prophylaxis
4	Oral prednisone 1-2mg/kg/day If IV required then methylprednisolone (equivalent) If no improvement after 2-3 days add additional immunosuppressants Supportive medical therapy if required	Discontinue therapy Continue corticosteroids (IV) PPI for GI prophylaxis If more than 3 weeks of corticosteroids given (or equivalent of 30mg prednisone/day) give PCP prophylaxis

PPI= Proton pump inhibitors, GI= Gastrointestinal, PCP=Pneumocystis carinii pneumonia

DISCUSSIONS:

American society of clinical oncology issued general recommendations for the management of adverse effects of immunotherapy. It states that for grade 1 toxicities, immunotherapy can be continued with close monitoring (with exception of a few toxicities). For grade 2 temporary withholding of the drug and administration of steroids should be done, as the severity decreases to grade 1 immunotherapy should be continued [16]. For grade 3 withholding of the drug and administration of steroids should be done if the symptoms fail to settle additional immunosuppressants (eg. Infliximab) can be given. After the settling of the symptoms steroid should be tapered off over a period of 4-6 weeks. For grade 4 permanent withholding of the drug and

immunosuppressants are recommended [17].

Dermatological toxicity is the most common of all occurring in almost 50% of patients on CTLA4 inhibitors and 30-40% on PD-1/PD-L1 inhibitor therapy. These occur earlier in the course of treatment and consist of a diverse range of adverse effects. 13-20% of the patients experience rash and pruritis which can be of varying severity. 8% of patients have been recorded to get vitiligo which is the appearance of amelanotic patches on skin these correlate with the immune response ie those patients who are responding well to the immune checkpoint inhibitor therapy are more likely to get it [18]. A few cases of re pigmentation of hair have been reported as well. Severe adverse effects (grade 4 IrEAs) include

Steven-Johnson syndrome, toxic epidermal necrolysis and drug rash with eosinophilia and systemic symptoms. these should be treated as an emergency with discontinuation of the drug and administration of immunosuppressants [19].

Gastrointestinal adverse effects can occur weeks or even months after the initiation of therapy and can continue even after the discontinuation of the drug. Diarrhea is the most frequent complaint, occurring in 23-33% of patients on CTLA4 inhibitors, <19% of those on PD-1 inhibitors and 44% of those on combination therapy. Infective causes of diarrhea especially *Clostridium difficile* should be ruled out prior to labelling it as drug induced. Colitis is also common occurring more frequently with CTLA 4 therapy this can be classified into two distinct types based on findings of abdominal CT (diffuse and segmental) [20]. Colonoscopy is gold standard and during the procedure multiple biopsies should be taken. Histopathology along with immunohistochemical staining should be done to rule out other causes including Cytomegalo viral infection. Hepatitis although less frequent may also occur [21]. The most common presentation being asymptomatic immune hepatitis. Elevated levels of hepatic enzymes (ALT and AST) and total bilirubin should raise suspicion of hepatic damage. it is proven that ipilimumab at higher dose (10mg/kg) is more hepatotoxic as compared to standard dose (3mg/kg). Changes on MRI including enlarged hepatic size, periportal lymphadenopathy and parenchymal changes [22].

A chunk of immune checkpoint inhibitor induced endocrinopathies is represented by hypopituitarism (hypophysitis) and hyperthyroidism (thyroiditis). Adrenal insufficiency, hypothyroidism and hypogonadism also occur but are rare. Acute hypophysitis most frequently occurs with combination immunotherapy (13%). Ipilimumab also causes hypophysitis, almost 10% of patients on standard dose (3mg/kg) and 17% on increased dose (10mg/kg) develop it. It leads to hypothyroidism in >90% of cases (TSH nad free T4 both below normal levels) and at most instances is diagnosed upon thyroid function tests [23]. Adrenal insufficiency can also result from decreased ACTH production after pituitary destruction. Baseline hormonal assays are necessary for the determination of the accurate etiology hence it is suggested that baseline TFTs, ACTH, cortisol, testosterone (in males), estradiol (in females), FSH, LH and MRI brain should be done prior to the initiation of the therapy. In a case study published, a 52 years old male on combination therapy developed hypophysitis, type I diabetes

mellitus and diabetes insipidus all only after 2 cycles of therapy. He presented with headache myalgia and fatigue and was diagnosed on brain MRI and hormonal assays [24].

Most common cause of primary hyperthyroidism (elevated TSH and decreased freeT4) is immune mediated thyroiditis, this occurs more frequently with PD-1/PD -L1 inhibitors. Although Grave's disease can also result in hyperthyroidism but is rare and is seen with CTLA 4 inhibitor use. Steroids and hormone replacement therapy is the mainstay of treatment. Rarely development of type 1 diabetes mellitus is also noticed in patients on immune checkpoint inhibitor therapy, timely diagnosis should be made and insulin therapy should be started before the complications occur. In another case study a 80 years old female who had already taken 20 cycles of nivolumab switched to ipilimumab, she developed fulminant type I diabetes mellitus only after 3 weeks on therapy [25].

Lungs are also at risk during the course of treatment. <5% of patients develop pneumonitis with grade 3 or more occurring in only 1-2% of them. Chances of developing pneumonitis increases with combination therapy and between PD -1 and PD-L1 patients taking PD-1 inhibitors are at a higher risk. A study done by Koyama N. et al states that nivolumab therapy has a higher risk of developing pneumonitis which is early onset [26]. Other pulmonological toxicities include pleural effusion, pulmonary fibrosis and Sarcoid like disease (hilar lymphadenopathy, non caseating granuloma and increased Th17.1 cells on bronchoalveolar lavage). If patients complain of pulmonary symptoms chest CT, pulmonary function test (PFT) AND 6 minute walk test (6MWT) are conducted to evaluate the function of the lungs. Rheumatological adverse effects usually present as myalgia, arthralgia and arthritis. Inflammatory oligo/poly arthritis is often seen which later leads to development of joint deformity and then disability. Presentation of arthritis is divided into three subtypes.

- 1) Involvement of large joints with uveitis and or conjunctivitis
- 2) Polyarthritis involving small joints mimicking rheumatoid arthritis
- 3) Seronegative arthritis with synovitis, tendons and entheses are usually involved

Rheumatological IrAEs are more common when combination immunotherapy is taken these may take months or years to resolve even after the discontinuation of the drug. Steroids and DMARDs are usually advised for its treatment. Infusion

reactions are the immediate side effects of the drug experienced by the patient during or a few hours after the administration of the drug. Avelumab is the most notorious of all, 25% of patients receiving this drug develop infusion reactions, while only <10% of patients on other types of immunotherapy develop such reactions. Infusion reactions can be diverse, ranging from rash, fever, shortness of breath to hypotension and angioedema. Rarely some patients may also develop anaphylactic reaction to these drugs [26].

Cardiovascular, hematological, renal, neurological and ophthalmological adverse effects are uncommon. Neurological side effect including autoimmune encephalitis, Myasthenia Gravis, Guillain Barre syndrome, peripheral neuropathy, meningitis and transverse myelitis occur in 4% of those on CTLA 4 therapy, 6% of those on PD1 and 12% of those on combination therapy. Clinical sign and symptoms along with lumbar puncture and CT/MRI of the brain can lead to the correct diagnosis. Renal toxicity is more common with combination therapy than monotherapy (5% compared to 2%). It includes interstitial nephritis and even acute renal failure. Lupus nephritis and granulomatous nephritis is rarely seen in patients on ipilimumab therapy [27].

Cardiotoxicity occurs in only <1% of all patients and usually includes rhythm disturbances eg. Arrhythmia and heart block. Myositis, myocarditis and pericarditis have also been seen in few patients. Eye problems including uveitis (occurring in <1% of all patients), episcleritis, blepharitis, optic nerve swelling and retinal detachment are also recorded. Hematological side effects include suppression of bone marrow (neutropenia, thrombocytopenia and anemia), myelodysplasia, hemolytic anemia and hemophilia A have also been seen [28]. Apart from the newer systemic therapies an oncolytic viral therapy, Talimogene Laherparepvec was also approved by the FDA in 2015 for the treatment of unresectable melanoma lesions (cutaneous, subcutaneous and nodal). This vaccine is directly injected into the tumor where it causes cell lysis. It is used as a local therapy and has no effect on the distant metastasis. A study was conducted and comparison was made between Talimogene Laherparepvec and granulocyte-macrophage colony-stimulating factor (GM-CSF), patients were divided into two groups each group received only one kind of injection for at least six months or till the lesion disappeared. Tumor shrinkage was seen in 16.4% of patients receiving Talimogene Laherparepvec compared to only 2.1% receiving GM-CSF [29].

CONCLUSION:

Recent advancements in the treatment for melanoma have given hope to patients with metastatic malignant melanoma. Targeted therapies have been the breakthrough drugs for mutated melanoma, the major concern at present is the resistance that the tumor develops a few months into the therapy. Studies are being conducted to explore the exact mechanism of resistance. Check point inhibitors (CTLA 4 and PD-1/PD-L1 inhibitors) have given great results, although they do result in immune related side effects but these are usually mild and easily managed. Single agent PD 1 therapy (Keytruda) is the standard treatment for advanced melanoma without any driver mutation. Newer agents eg. Oncolytic viral therapy have also been approved which acts as local therapy. The past few years have been crucial for the development of therapeutic agents against melanoma and hopefully the upcoming years will bring even more efficient modalities for its treatment.

REFERENCES:

1. Middleton, M.R., et al., Randomized phase III study of temozolomide versus dacarbazine in the treatment of patients with advanced metastatic malignant melanoma. *Journal of Clinical Oncology*, 2000. 18(1): p. 158-158.
2. Eccles, S.A. and D.R. Welch, Metastasis: recent discoveries and novel treatment strategies. *The Lancet*, 2007. 369(9574): p. 1742-1757.
3. Gray-Schopfer, V., C. Wellbrock, and R. Marais, Melanoma biology and new targeted therapy. *Nature*, 2007. 445(7130): p. 851.
4. Goldberg, S.B., et al., Pembrolizumab for patients with melanoma or non-small-cell lung cancer and untreated brain metastases: early analysis of a non-randomised, open-label, phase 2 trial. *The lancet oncology*, 2016. 17(7): p. 976-983.
5. Franklin, C., et al., Immunotherapy in melanoma: recent advances and future directions. *European Journal of Surgical Oncology (EJSO)*, 2017. 43(3): p. 604-611.
6. Postow, M.A., et al., Nivolumab and ipilimumab versus ipilimumab in untreated melanoma. *New England Journal of Medicine*, 2015. 372(21): p. 2006-2017.
7. Maverakis, E., et al., Metastatic melanoma—a review of current and future treatment options. *Acta dermato-venereologica*, 2015. 95(5): p. 516-527.
8. Eggermont, A.M., et al., Prolonged survival in stage III melanoma with ipilimumab adjuvant therapy. *New England Journal of Medicine*, 2016. 375(19): p. 1845-1855.
9. Miller, K.D., et al., Cancer treatment and survivorship statistics, 2016. CA: a cancer

- journal for clinicians, 2016. 66(4): p. 271-289.
10. Field, M.G. and J.W. Harbour, Recent developments in prognostic and predictive testing in uveal melanoma. *Current opinion in ophthalmology*, 2014. 25(3): p. 234.
 11. Azijli, K., et al., New developments in the treatment of metastatic melanoma: immune checkpoint inhibitors and targeted therapies. *Anticancer research*, 2014. 34(4): p. 1493-1505.
 12. Garbe, C., et al., Diagnosis and treatment of melanoma. European consensus-based interdisciplinary guideline—Update 2016. *European Journal of Cancer*, 2016. 63: p. 201-217.
 13. Okwan-Duodu, D., et al., Role of radiation therapy as immune activator in the era of modern immunotherapy for metastatic malignant melanoma. *American journal of clinical oncology*, 2015. 38(1): p. 119-125.
 14. Rahib, L., et al., Projecting cancer incidence and deaths to 2030: the unexpected burden of thyroid, liver, and pancreas cancers in the United States. *Cancer research*, 2014.
 15. Sequist, L.V., et al., Rociletinib in EGFR-mutated non-small-cell lung cancer. *New England Journal of Medicine*, 2015. 372(18): p. 1700-1709.
 16. Turajlic, S. and C. Swanton, Metastasis as an evolutionary process. *Science*, 2016. 352(6282): p. 169-175.
 17. Davey, R.J., A. van der Westhuizen, and N.A. Bowden, Metastatic melanoma treatment: combining old and new therapies. *Critical reviews in oncology/hematology*, 2016. 98: p. 242-253.
 18. Li, J., et al., Recent advances in targeted nanoparticles drug delivery to melanoma. *Nanomedicine: Nanotechnology, Biology and Medicine*, 2015. 11(3): p. 769-794.
 19. Larkin, J., et al., Combined nivolumab and ipilimumab or monotherapy in untreated melanoma. *New England Journal of Medicine*, 2015. 373(1): p. 23-34.
 20. Li, Y., et al., Tumor DNA in cerebral spinal fluid reflects clinical course in a patient with melanoma leptomeningeal brain metastases. *Journal of neuro-oncology*, 2016. 128(1): p. 93-100.
 21. Lo, J.A. and D.E. Fisher, The melanoma revolution: from UV carcinogenesis to a new era in therapeutics. *Science*, 2014. 346(6212): p. 945-949.
 22. Muñoz-Couselo, E., et al., Recent advances in the treatment of melanoma with BRAF and MEK inhibitors. *Annals of translational medicine*, 2015. 3(15).
 23. Tsao, A.S., et al., Scientific advances in lung cancer 2015. *Journal of Thoracic Oncology*, 2016. 11(5): p. 613-638.
 24. Mahendraraj, K., et al., Trends in incidence, survival, and management of uveal melanoma: a population-based study of 7,516 patients from the Surveillance, Epidemiology, and End Results database (1973–2012). *Clinical ophthalmology (Auckland, NZ)*, 2016. 10: p. 2113.
 25. Hendry, S., et al., Assessing Tumor-Infiltrating Lymphocytes in Solid Tumors: A Practical Review for Pathologists and Proposal for a Standardized Method from the International Immuno-Oncology Biomarkers Working Group Part 2 TILs in Melanoma, Gastrointestinal Tract Carcinomas, Non-Small Cell Lung Carcinoma and Mesothelioma, Endometrial and Ovarian Carcinomas, Squamous Cell Carcinoma of the Head and Neck, Genitourinary Carcinomas, and Primary Brain Tumors. *Advances in anatomic pathology*, 2017. 24(6): p. 311-335.
 26. Vennepureddy, A., et al., Novel drugs and combination therapies for the treatment of metastatic melanoma. *Journal of clinical medicine research*, 2016. 8(2): p. 63.
 27. Gross, S., et al., Targeting cancer with kinase inhibitors. *The Journal of clinical investigation*, 2015. 125(5): p. 1780-1789.
 28. Nikolaou, V. and A. Stratigos, Emerging trends in the epidemiology of melanoma. *British journal of dermatology*, 2014. 170(1): p. 11-19.
 29. Stadler, S., et al., New therapeutic options for advanced non-resectable malignant melanoma. *Advances in medical sciences*, 2015. 60(1): p. 83-88.