



CODEN [USA]: IAJ PBB

ISSN: 2349-7750

INDO AMERICAN JOURNAL OF  
**PHARMACEUTICAL SCIENCES**

<http://doi.org/10.5281/zenodo.3266209>

Available online at: <http://www.iajps.com>

*Research Article*

## PATTERN OF STRUCTURAL BRAIN LESION IN PATIENTS PRESENTING WITH NON-FOCAL DEFICIT HEADACHE ON CT BRAIN

<sup>1</sup>Rabia Nazir, <sup>2</sup>Javaria Zulfiqar, <sup>3</sup>Mehek Mushtaq.

Article Received: April 2019

Accepted: May 2019

Published: June 2019

**Abstract:**

**Objective;** To determine the frequency and pattern of structural brain lesion in patients presenting with non-focal deficit headache on CT brain.

**Methods:** It was a cross sectional study which was conducted at Mayo Hospital & LGH Lahore in which 80 cases selected via non probability consecutive sampling, presenting with non focal deficit headache were included. Their detailed demographic data and other history regarding focal lesions was taken and recorded. They then underwent CT brain plain at Radiology department of the same institute. The different lesions detected were noted.

**Results:** In this study there were total 80 cases presenting with the history of headache and out of these 48 (60%) were females and 32 (40%) males. The mean age at presentation was  $28.42 \pm 5.40$  years. In 55 (68.75%) cases, the CT was absolutely normal. Regarding different lesions detected sinusitis was seen in 19 (23.75%) cases, CSOM in 3 (3.75%), brain abscess in 2 (2.50%) and SOL in only 1 (1.25%) case. Regarding the lesions among gender stratification 38 (69.09%) females had normal CT as compared to 17 (30.91%) males while sinusitis was common in males affecting 12 (63.16%) cases as compared to 7 (36.84%) females with a near significance of 0.07.

**Conclusion:** Headache is a common presentation at hospitals and in two third of cases the CT brain done reveals no pathology. Serious disease was seen in only 3 cases.

**Key words:** Headache, CT, CSOM, SOL

**Corresponding author:**

**Rabia Nazir,**

QR code



Please cite this article in press Rabia Nazir et al., *Pattern of Structural Brain Lesion in Patients Presenting with Non-Focal Deficit Headache on Ct Brain.*, Indo Am. J. P. Sci, 2019; 06(07).

**INTRODUCTION:**

Headache is the most often reported neurological symptom in emergencies and outpatient departments. [1] It has two types primary and secondary and the latter is defined as the headache which is secondary to some underlying cause. Secondary headache can again be sub-classified to structural brain lesion (infarct, bleed, malignancies, abscesses, hydrocephalus, and aneurysm) or have referred pain due to sinusitis, otitis media or some bony pathology). [2] There is a great degree of fear among some patients that they suffer from a severe disease and therefore warrant further diagnostic investigations.

Patients with structural brain lesions or referred pain usually present with focal deficit like hemiplegia, monoplegia, cranial nerve abnormalities or associated symptoms of ear discharge or pain respectively. But there are cases that report headache even without such deficit and are diagnosed on neuroimaging with such lesion and intervention have avoided unwanted serious CNS damage. [3-4]

CT and MRI both have been used in the diagnosis of lesions with structural lesions of the brain and have shown good results. But the issue is headache without focal deficit, which on one hand can diagnose the lesion early and on the other hand undue investigations can put a lot financial burden on patients in developing country like Pakistan. [5-7]

A large review of 3026 scans of patients with headache assessed by CT brain showed only a minority of patients suffered from a serious disease accounting for only 2.8% in the form of brain tumors, arteriovenous malformations, hydrocephalus, aneurysm, subdural hematoma strokes and malignancies. [8]

**Objective:** To determine the frequency and pattern of structural brain lesion in patients presenting with non-focal deficit headache on CT brain.

**MATERIALS AND METHODS:**

It was a cross sectional study which was conducted at Mayo Hospital & LGH Lahore in which 80 cases selected via non probability consecutive sampling, presenting with non focal deficit headache were included. Their detailed demographic data and other history regarding focal lesions was taken and recorded. They then underwent CT brain plain at Radiology department of the same institute. The

different lesions detected were noted.

**SAMPLE SELECTION:**

The sample was selected according to the following criteria;

**Inclusion Criteria:**

1. Age 20-60 years
2. Both genders
3. Patients with history of headache lasting more than 1 month without any focal deficit.

**Exclusion Criteria:**

- 1- Already documented case of any structural abnormality like brain abscess, sinusitis, brain tumor, hydrocephalus, infarct or hemorrhage (assessed by history and medical record)
- 2- Cases with history of head trauma of any extent in last one month (assessed by history and medical record).
- 3- Cases with any focal neurological deficit like weakness of any duration in nay limb or other part of the body. (assessed by history and medical record).

**Statistical analysis;**

All the data was analyzed on SPSS version 20.0 and chi square test was applied to see for significance and p value less than 0.05 was considered as significant.

**RESULTS:**

In this study there were total 80 cases presenting with the history of headache and out of these 48 (60%) were females and 32 (40%) males. The mean age at presentation was 28.42±5.40 years. In 55 (68.75%) cases, the CT was absolutely normal. Regarding different lesions detected sinusitis was seen in 19 (23.75%) cases, CSOM in 3 (3.75%), brain abscess in 2 (2.50%) and SOL in only 1 (1.25%) case (Figure 1). Regarding the lesions among gender stratification 38 (69.09%) females had normal CT as compared to 17 (30.91%) males while sinusitis was common in males affecting 12 (63.16%) cases as compared to 7 (36.84%) females with a near significance of 0.07 (table 1).

**DISCUSSION:**

Headaches are well-reported entities in the emergency departments and add to the high burden regarding investigations. On one hand it is just a subjective feeling and there is no underlying disease or cause found even in the context of extensive investigations, but on the other hand it is predictor of sever or mild underlying causes.

In the present study there were 55 (68.75%) cases that did not have any abnormality. This was also observed by the other studies as well that revealed

that the yield of underlying disease on CT presenting with headache is very less. In a study done by Fazel R et al it was only 10%.<sup>9</sup> While in another study they used clinical warning criteria (CWC) for headache and then assessed these cases with CT brain and they found that 64.3% had absolutely normal CT and 35.7% had finding.<sup>10</sup> Similar was reported from a study in Nepal where the normal CT was seen in 73% of cases. [11] Regarding different lesions detected sinusitis was seen in 19 (23.75%) cases, CSOM in 3 (3.75%), brain abscess in 2 (2.50%) and SOL in only 1 (1.25%) case. This was similar to study done by Rai GS et al that conducted on 500 cases with headache and 374 had normal CT, while sinusitis was the most common finding affecting 58 cases and 13 with CSOM abscess were seen in 10 and SOL in 5 cases. [12]

Regarding the lesions among gender stratification 38 (69.09%) females had normal CT as compared to 17

(30.91%) males while sinusitis was common in males affecting 12 (63.16%) cases as compared to 7 (36.84%) females with a near significance of 0.07. Similar results were also seen by the study by Lipton RB et al that found the females to suffer from these headache with a ration of 2:1 to 3:1. [13] The headache with normal CT were also more common in females and the reason of this can be explained as migraine and tension headache are more common in females and these are the types where CT brain turns normal. A good number of cases in males also had normal CT and the reason can be cluster headache, which is also a type with normal CT and is common in males. [14]

### CONCLUSION:

Headache is a common presentation at hospitals and in two third of cases the CT brain done reveals no pathology. Serious disease was seen in only 3 cases.

**FIGURE 01**  
**TYPES OF LESION DETECTED ON CT BRAIN**

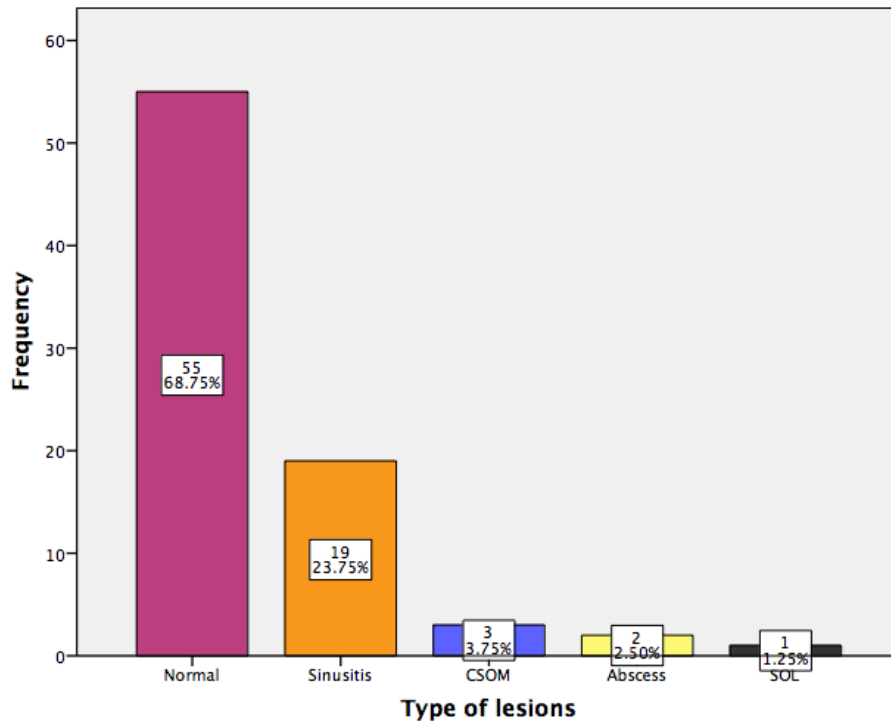


TABLE 01: TYPE OF LESION WITH RESPECT TO GENDER n= 80

TYPE OF LESION	GENDER		Total
	Male	Female	
Normal	17 (30.91%)	38 (69.09%)	55
Sinusitis	12 (63.16%)	7 (36.84%)	19
CSOM	1 (33.33%)	2 (66.67%)	3
Brain abscess	1 (50%)	1 (50%)	2
SOL	1 (100%)	0 (00%)	1
<b>TOTAL</b>	<b>32 (40%)</b>	<b>48 (60%)</b>	<b>80 (100%)</b>

p= 0.07

**REFERENCES:**

- Peters KS. Secondary headache and head pain emergencies. *Primary Care*. 2004;31(2):381-93.
- Headaches. Different types of headaches [internet]. 2016 [cited on 15-06-2016]. Available at [www.webmd.com/migraines-headaches/guide/migraines-headaches-basics](http://www.webmd.com/migraines-headaches/guide/migraines-headaches-basics).
- Kernick DP, Ahmed F, Bahra A, Dowson A, Elrington G, Fontebasso M, et al. Imaging patients with suspected brain tumour: guidance for primary care. *Brit J Gen Pract*. 2008;58(557):880-85.
- Diener HC, Katsarava Z, Weimar C. Headache associated with ischemic cerebrovascular disease. *Rev Neurol*. 2008;164:819-24.
- Nepal P, Shrestha A, Ghimire N. Evaluation of CT scan findings in patients presenting with headache. *J Chitwan Med Coll*. 2014;3(4):9-12.
- Sun Z, Ng KH, Vijayanathan A. Is utilization of computed tomography justified in clinical practice? : application in the emergency department. *Singapore Med J*. 2010;51(3):200-06.
- Nabhani KA, Kakaria A, Syed R. Computed tomography in management of patients with non-localizing headache. *Oman Med J*. 2014;29(1):28-31.
- Evans RW. Diagnostic testing for the evaluation of headaches. *Neurol Clin*. 1996;14(1):1-26.
- Fazel R, Krumholz HM, Wang Y, Ross JS, Chen J, Ting HH, et al. Exposure to low-dose ionizing radiation from medical imaging procedures. *N Engl J Med* 2009 Aug;361(9):849-857.
- Aygun D, Bildik F. Clinical warning criteria in evaluation by computed tomography the secondary neurological headaches in adults. *European Journal of Neurology*. 2003;10(4):437-42.
- Nepal P, Shrestha A, Ghimire N. Evaluation of CT Scan Findings in Patients Presenting with Headache. *Journal of Chitwan Medical College*. 2014;3(4): 9-12.
- Rai GS, Rai T, Jain L, Vyas MM, Roshan R. Evaluation of CT and MRI findings among patients presented with chief complaint of headache in central India. *J Clin Diag Res*. 2016;10(2):21-25.
- Lipton RB, Stewart WF, Diamond S, Diamond ML, Reed M. Prevalence and burden of migraine in the United States: data from the American Migraine Study II. *Headache: The Journal of Head and Face Pain*. 2001;41(7):646-57.
- Alders EE, Hentzen A, Tan CT. A community-based prevalence: study on headache in Malaysia. *Headache: The Journal of Head and Face Pain*. 1996;36(6):379-84.