



CODEN [USA]: IAJ PBB

ISSN: 2349-7750

**INDO AMERICAN JOURNAL OF
PHARMACEUTICAL SCIENCES**<http://doi.org/10.5281/zenodo.3936362>Available online at: <http://www.iajps.com>

Review Article

**REVIEWING DIFFERENT ASPECTS OF INFECTED
NONUNION TIBIA**

Abdulelah Abdulshakoor Saati, Omar Qurayti S Alanazi

Article Received: May 2020

Accepted: June 2020

Published: July 2020

Abstract:

In this review we discuss the diagnosis and classification methods of infected nonunion of tibia as well as the treatment approaches and advantages of some techniques over others. We conducted a narrative review of the literature using the online databases such; Medline and EMBASE. Studies involving the Infected nonunion of the tibia were targeted in our search. We included studies published up to December, 2019. Infected nonunion of tibia and femur prevail in clinical method. Some coexisting issues generally make complex the nonunion consisting of consistent infection, bone and soft tissue loss, limb-length inequalities, defect, and joint stiffness. Heretofore, there has actually still been a difficulty for orthopedic surgeons about the therapy of contaminated nonunion of tibia and femur. Several various surgical therapy options have been recommended, consisting of bone grafting, free tissue transfer, antibiotic cement, and Ilizarov techniques. There are some constraints in bone grafting, such as the size of bone defects, donor site morbidity, and prolonged graft consolidation time. Although free tissue transfer appropriates for the therapy of large bone and soft tissue loss, it is a technically requiring surgical procedure, and it is typically associated with stress fractures and nonunion.

Corresponding author:

Abdulelah Abdulshakoor Saati,

QR code



Please cite this article in press Abdulelah Abdulshakoor Saati et al, Reviewing Different Aspects Of Infected Nonunion Tibia., Indo Am. J. P. Sci, 2020; 07(07).

INTRODUCTION:

Fractures of long bones are not only intricate operative problems however additionally chronic and also sometimes can be devastating problems. Nonunion of long bones is not simply a resource of functional weakness yet in addition can result in economic problem and also loss of self-worth. The event seems to be expanding, especially because raising high-velocity injury, which is additional commonly treated with internal fixation [1], [2]

Persistent infection of the diaphysis shaft of lengthy bones is just one of one of the most perplexing issues in orthopedic surgical treatment. Hard or immune infections usually need an extra radical debridement of the septic bone and soft cells along with the application of steady addiction to improve soft tissue healing as well as bony union. Papineau-type open cancellous bone grafting, tibiofibular synostosis, cancellous allograft in fibrin sealant combined with anti-biotics, and/or free microvascular soft cells and bone transplants.

Infected nonunion of the tibia posture significant difficulties for total resolution and practical restoration. The infection is chronic and resistant to treatment. In this review we discuss the diagnosis and classification methods of infected nonunion of tibia as well as the treatment approaches and advantages of some techniques over others.

METHODOLOGY:

We conducted a narrative review of the literature using the online databases such; Medline and EMBASE. Studies involving the Infected nonunion of the tibia were targeted in our search. We included studies published up to December, 2019. restriction to English language and human subject were performed in our search strategy. Moreover, we have searched the references of included studies for more relative articles.

DISCUSSION:**• Diagnostic techniques:**

Infected nonunion are very easy to detect and difficult to treat. Unusual mobility is common in many gaps nonunion of tibia. Many masquerades as malunions with little mobility, especially with a united fibula. Long leg films reveal level of bony involvement, limb positioning, and also size discrepancy. X-rays disclose sequester, osteoporosis, defects, and also extent of the bony space. Oblique X-rays can expose the space as well as confirm the medical diagnosis of a nonunion.

Elevated acute phase stimulant levels verify active infection as well as aid monitor prognosis. Serological marker screening for liver disease B surface area antigen, HIV, as well as liver disease C is necessary. High chances of dash, pinprick, and also call with body fluids or lotions of individuals make the medical group susceptible to creating infection.

Classification:

Contaminated nonunions of tibia posture numerous difficulties to the dealing with surgeon and the patient. Difficulties consist of recalcitrant infection, complex deformities, sclerotic bone ends, big bone gaps, shortening, and joint tightness. They are very easy to diagnose and difficult to treat. The ASAMI category assists decide therapy. Classification of infected nonunion should have prognostic worth and aid choose treatment. ASAMI classification is generally utilized (Table 1) [6]. Infection is classified as active or dormant.

Table 1. ASAMI classification of nonunion [6].

○ A-Aseptic nonunion without bone defect
A1 Mobile (atrophic/hypotrophic)
A2 Stiff without deformity (hypertrophic)
A3 Stiff with deformity (hypertrophic)
○ B-Aseptic nonunion with bone defect
B1 Length of limb preserved with bone defect
B2 Segment in contact with shortening of limb
B3 Combined shortening with defect
○ C-Infected nonunion

Infection severity score

The infection severity score (ISS) qualities severity of infection by evaluating 6 medical criteria [7]. The classification system (Table 2) considers the history and medical and radiological data. The score is easy to compute. Maximum score is 25, which is transformed to 100. Higher ratings point to need for a second debridement and possibility of insufficient removal or reappearance of infection. It might suggest using exterior instead of internal addiction in the 2nd phase as a conclusive method to attain union.

Lower scores point to alleviate of elimination of the infection. Lower scores can permit definitive inner fixation in the 2nd stage or outside fixation in the very same phase. ISS would help grade residual infection if any.

Table 2. Infection severity score ^[7].

Sinuses	Skin	Sequestra	Discharge	Implant	Rx needed
Nil=0	Supple=0	None=0	Ni=0	None=0	ABC beads=1
Few or dried=1	Thin/adherent=1	<5 mm/single/few=1	1-2 drops/day=1	Ex fix only=1	ABC rod=3
Multiple/active=2	Ulcerated=2	>5 mm/multiple=2	Few drops/day=2	Plating=2	ABC beads and Rod=5
		>1 cm/multiple=3	Daily dressing=3	Nailing=3	
		Whole circumference=5	Severe soakage with foul smell=7	Nailing and plating/ multiple surgeries=4	

Six parameters are measured, and score is given of a maximum of 25 points which is then converted out of 100.

• Treatment

The Ilizarov technique

This technique is regarded by numerous surgeons as a standard therapy in contaminated nonunion. It is a salvage operation, appropriate for extremely picked and inspired patients ^[8]. The technique can attend to lots of problems concurrently: bone deformities, deformity, malrotation, limb-length discrepancy, and nonunion ^[9]. It is the most reputable technique for regaining a stable and functional leg. There more than sixty patients treated with this strategy and reported in the literary works in the last decade. There are different methods of using the Ilizarov in infected nonunion; If there is no bone problem, the nonunion can be compressed and the setting kept up until union. Infection is not removed or dealt with. If there is bone deformity initially or after bone debridement, there are 2 options: acute shortening or bone transport. Acute shortening is followed by limb extending to recover length ^[10]. Acute shortening causes arteriolar occlusion and formation of scar tissue, which might trigger problem with later limb length restoration.

Bone transport is a great strategy for closure of big bone flaws. The benefit of this procedure is that

there is simultaneous soft tissue transportation, but the negative aspect is that the delivered soft tissue is atrophic and makes a poor soft tissue envelope ^[10]. This kind of soft tissue protection is not suitable for contaminated non-union as the soft tissue coverage over the docking site might be slim and oversensitive ^[13]. Soft tissue closure can also be attained by skin traction throughout bone transport. The Ilizarov strategy can be successfully applied in youngsters with great results ^[12]. The outcomes with the Ilizarov are outstanding ^[9]. On the whole, bone outcomes are great to exceptional in 80% and functional results are good to outstanding in 66.7% ^[9]. The practical outcomes are, as a basic guideline, poorer contrasted to bone results ^[11]. Practical results rely on the extent of damage endured by soft tissue at the time of injury and or throughout succeeding medical interventions. The issue rate associated with using Ilizarov method (both minor and major) might reach 87%. It should be borne in mind that these patients are neglected situations with numerous unsuccessful previous procedures, and it is challenging to choose whether these patients' limbs must be amputated or salvaged.

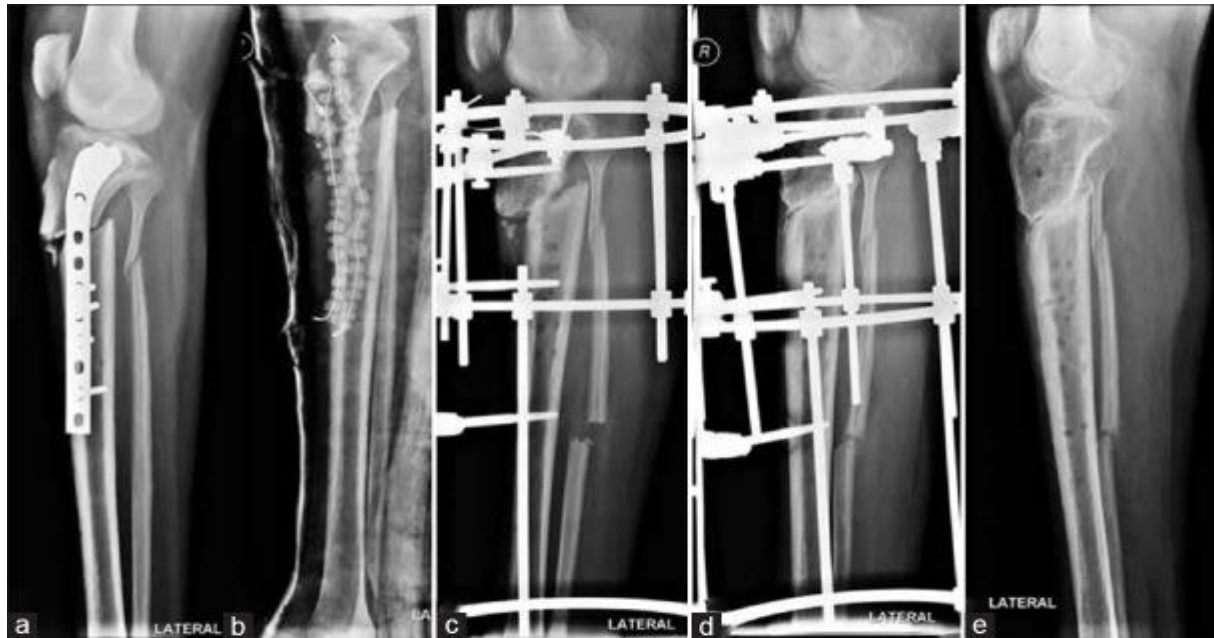


Figure 1. Oblique view of leg bones with knee showing (a) upper tibial infected nonunion (b) After infection control (c) Ilizarov apparatus in situ (d). If vertical compression is given, it causes vertical displacement of nonunion ends. With the help of washers, horizontal compression achieved perpendicular to plane of nonunion (e) Good union. No loss of length ^[14].

Intramedullary devices with or without external fixators

Bone transport over an intramedullary device is a relatively new technique in the treatment of afflicted nonunion. The advantages of this method are; fracture stabilizing, prevention of limb reducing and malrotation, and early partial weight-bearing ^[15]. There are 43 reported patients that have been treated with this type of personnel method ^[16]. This technique still requires to be evaluated. Inner fixation (plating) has not been reported in the management of infected nonunion of long bones ^[18].

Free tissue transfer

Free tissue transfer (bone, soft tissue or both) are technically requiring, and require close co-operation in between plastic and orthopedic surgeons. Choices for vascularized bone are; fibula, iliac crest, ribs, and scapula. Cheng et al. made use of vascularized two ribs graft plus serratus anterior in six patients with infected nonunion ^[19]. All cracks joined, and infection was regulated, however there were two stress cracks of the dental implanted ribs. The fractures were dealt with non-operationally and they united. Vascularized bone and tissue can be made use of in difficult infections. Yasunori et al. utilized fibular grafts in contaminated nonunion triggered by Methicillin-Resistant *Staphylococcus Aureus* (MRSA), obtaining union in 18/20 90% ^[17], ^[20]. Infection was regulated using the two-phase technique. The two-stage approach gives an organic setting which is essential for healing of bone and soft tissue.

Debridement, bone-grafting, and soft tissue coverage (in situ reconstruction)

Not all infected nonunions require challenging procedures. In situ reconstruction does provide an option. Small problems (2-4 cm) can be properly treated with easier techniques, utilizing the exact same two-stage strategy. Cancellous bone-grafting (with or without antibiotics) is done in the 2nd stage ^[21]. Soft tissue coverage can be obtained by either neighborhood or vascularized muscle flap. Prescription antibiotics mixed with cancellous bone during the second phase provides high regional concentration of the anti-biotics for as much as 3 weeks without systemic indications of antibiotic poisoning. The effect(s) of blending antibiotics with cancellous bone grafting (regarding bone union or incorporation) is not known at this stage. The method is very efficient in the eradication of infection: up to 94.4% success rate ^[21]. In situ fibular transfer has been efficiently utilized in youngsters with tibial infected nonunion. Haluk et al. used this method in four kids ^[22]. He obtained union in all and infection was efficiently removed. The angular defect that takes place so generally after this treatment will certainly deal with spontaneously in most youngsters. Vascularised fibular transfer can also be executed in children, without impacting growth of the donor leg ^[23].

Local antibiotic delivery systems

Eliminating fibrous tissue, necrotic bone, and opening the marrow canal improve blood supply and enable nutrients and antibiotics to get to the site. An

antibiotic impregnated cement block obliterates dead area. It allows elution of the antibiotic in very high focus at the local site, in numerous multiples of the minimum inhibitory concentration (MIC) [24]. Acrylic bone cement is made into intramedullary (IM) rods (with a core of a K cord or Rush nail/V nail). The rod is inserted from proximal portal after reaming. In flawed canals, one cement rod is inserted in the proximal canal and an additional in the distal through the nonunion site. Cement beads are strung on an SS wire in the extramedullary part. Adding the antibiotic powder or fluid towards the end of polymerization makes certain higher elution of antibiotics [25].

The cement can be made right into a block to inhabit the entire bony gap. Conversely, the concrete may be made as a cylindrical tube and Rush or Ender nails travelled through it to protect the cement block to the bone.

Just recently, a huge diameter nail with a double core of antibiotic cement around a steel rod has been used for substance fractures with great impact [26]. This could be made use of for therapy of afflicted nonunion without significant bony gaps too.

In smaller spaces, an absorbable service provider might make the 2nd surgical procedure unnecessary. The use of calcium sulfate cement paste or powder and absorbable chitosan polymer service providers are great alternatives [27]. In moderate infection, debridement and definitive surgical treatments may be executed together. With ISS rating less than 25-30, after detailed debridement and regional antibiotic delivery systems, one may take a chance with repeat interior fixation. Steady fixation with ABC rods itself can cause union in regarding 10-15% of situations.

Utilizing interior fixation boosts threat of recurring infection in patients with greater ISS scores. Combined surgery of debridement and exterior addition might be safe when the ISS score is less than or equal to 40. Greater ISS scores call for organized surgical procedure.

CONCLUSION:

Infected nonunion of tibia and femur prevail in clinical method. Some coexisting issues generally make complex the nonunion consisting of consistent infection, bone and soft tissue loss, limb-length inequalities, defect, and joint stiffness. Heretofore, there has actually still been a difficulty for orthopedic surgeons about the therapy of contaminated nonunion of tibia and femur. Several various surgical therapy options have been recommended, consisting of bone grafting, free tissue transfer, antibiotic cement, and Ilizarov techniques. There are some constraints in bone

grafting, such as the size of bone defects, donor site morbidity, and prolonged graft consolidation time. Although free tissue transfer appropriates for the therapy of large bone and soft tissue loss, it is a technically requiring surgical procedure, and it is typically associated with stress fractures and nonunion. Antibiotic cement is utilized to manage the infection effectively, but it is just appropriate for the treatment of contaminated nonunion with small issues or none, and bone grafting is usually required to attain bone union. Ilizarov approaches can conquer all these difficulties and address coexisting problems all at once. Ilizarov apparatus is a very good choice for treating infected nonunion with a huge bone gap. Modern bone histogenesis complying with corticotomy and bone transportation help in loading bone spaces eliminating infection and advertising fracture union. Therefore, bone transportation has actually progressively been a major treatment for infected nonunion.

REFERENCES:

1. Vignes GS, Arumugam S, Ramabadran P. Functional outcome of infected non-union tibia fracture treated by Ilizarov fixation. *Int J Sci Study* 2014;2:87-92. Back to cited text no.
2. Bansal A, Bansal S, Singh R, Walia JP, Brar BS. Role of Ilizarov ring fixator in infected non union tibia. *Int J Med Dent Sci* 2014;3:451-9. Back to cited text no. 2
3. Yu P, Zhang Q, Mao Z, Li T, Zhang L, Tang P. The treatment of infected tibial nonunion by bone transport using the Ilizarov external fixator and a systematic review of infected tibial nonunion treated by Ilizarov methods. *Acta Orthop Belg* 2014;80:426-35.
4. Wijesekera MP, Graham SM, Lalloo DG, Simpson H, Harrison WJ. Fracture management in HIV positive individuals: A systematic review. *Int Orthop*. 2016;40:2429–45.
5. Javidan P, Walker RH. Take care with type C: Serious considerations in the selection of patients with hepatitis C for total joint arthroplasty. *J Bone Joint Surg Am*. 2015;97:e77.
6. Calori GM, Phillips M, Jeetle S, Tagliabue L, Giannoudis PV. Classification of nonunion: Need for a new scoring system? *Injury*. 2008;39(Suppl 2):S59–63.
7. Chaudhary Milind M. Infected gap nonunions of femur. In: Kulkarni GS, Babhulkar S, editors. *Guidelines in Fracture Management, Nonunion in Long Bone II*. Ch. 25. Noida: Thieme Publisher; 2016. pp. 309–24.
8. Arnez ZM, Smrke D. Treatment of extensive bone and soft tissue defects of the lower limb by traction and free-flap transfer. *Injury Int J Care Injured* 2000;31:153–62.

9. Chadha M, Maini L, Vishwanath J. The Ilizarov method in infected nonunion of fractures. *Injury Int J Care Injured* 2000;31:509—17.
10. Eshima I, Feibel RJ, Louie KW, Lowenberg DW. Combined muscle flap and Ilizarov reconstruction for bone and soft tissue defects. *Clin Orthop Relat Res* 1996;(November (332)):37—51.
11. Atesalp AS, Basbozkurt M, Komurcu M, Kurklu M. The treatment of infected tibial nonunion with aggressive Debride'- ment and internal bone transport. *Mil Med* 2002;167(12): 978—81.
12. Kabukcuoglu Y, kucukkaya M, Kuzugun U, Tezer M. Management of childhood chronic osteomyelitis with the Ilizarov method. *J Paediatr Orthopaed* 2002;22:632—7.
13. Kocalkowski A, Marsh DR, Shackley DC. Closure of the skin defect overlying infected nonunion by skin traction. *Br J Plastic Surg* 1998;51:307—10.
14. Chaudhary MM. Infected nonunion of tibia. *Indian J Orthop.* 2017;51(3):256–268.
15. Bu'hren V, Gonschorek O, Hofmann GO. Segmental transport employing intramedullary devices in tibial bone defects following trauma and infection. *J Orthop Trauma* 1999; 13(3):170—7.
16. Eralp L, Kocaoglu M, Rashid H, et al. Reconstuction of segmental bone defects due to chronic osteomyelitis with use of an external fixator and an intramedullary nail. *J Bone Joint Surg* 2006;88-A(October (10)):2137—45.
17. Eshima I, Feibel RJ, Louie KW, Lowenberg DW. Combined muscle flap and Ilizarov reconstruction for bone and soft tissue defects. *Clin Orthop Relat Res* 1996;(November (332)):37—51.
18. Hahn D, Olson S. Surgical treatment of nonunions: a case for internal fixation.. *Injury Int J Care Injured* 2006;37: 681—90.
19. Cheng S-L, Chuang David DC-C, Shih C-H, Ueng SW-N. Management of large infected tibial defects with radical Debride'- ment and staged double-rib composite free transfer. *J Trauma Injury Infect Crit Care* 1996;40(3):345—50.
20. Kobata Y, Shigematsu K, Yajima H. Vascularized fibular grafting in the treatment of methicillin-resistant *Staphylococcus Aureus* osteomyelitis and infected nonunion. *J Reconstr Microsurg* 2004;20:1—12.
21. Chan Y-S, Ueng SW-N, Wang C-J, et al. Management of small infected tibial defects with antibiotic-impregnated autogenic cancellous bone grafting. *J Trauma Injury Infect Crit Care* 1998;45(October (4)):758—64.
22. Agus H, Arslantas M, Kalenderer O, Ozcalabi IT. Treatment of infected pseudoarthrosis of the tibia by in situ fibular transfer in children.. *Injury Int J Care Injured* 2005;36:1476—9.
23. Haopeng L, Liaosha J, Xijing H. Functional development of the donor leg after vascularized fibula graft in childhood. *J Paediatr Surg* 2000;35(August (8)):1226—9.
24. Gogia JS, Meehan JP, Di Cesare PE, Jamali AA. Local antibiotic therapy in osteomyelitis. *Semin Plast Surg.* 2009;23:100–7.
25. Chang YH, Tai CL, Hsu HY, Hsieh PH, Lee MS, Ueng SW. Liquid antibiotics in bone cement: An effective way to improve the efficiency of antibiotic release in antibiotic loaded bone cement. *Bone Joint Res.* 2014;3:246–51.
26. Craveiro-Lopes N. Treatment of open fractures of the tibia with locked intramedullary nail with a core release of antibiotics (Safe Dualcore Universal). Comparative study with a standard locked intramedullary nail. *J Limb Lengthening Reconstr.* 2016;2:17–22.
27. Ślósarczyk A, Czechowska J, Paszkiewicz Z, Zima A. New bone implant material with calcium sulfate and Ti modified hydroxyapatite. *J Achiev Mater Manuf Eng.* 2010;43:170–7.