



INDO AMERICAN JOURNAL OF PHARMACEUTICAL SCIENCES

Available online at: <http://www.iajps.com>

Research Article

MORPHOMETRIC STUDY OF THE CORONOID PROCESS OF THE MANDIBLE FOR ITS VARIOUS SHAPES AND SEXING OF THE MANDIBLE (A DRY HUMAN BONE STUDY)

Dr. Gurbachan Singh Gindha^{*1}, Dr. Tejinderpal Singh², Dr. Sidharth Sankar
Maharana³

1. Professor, Department of Anatomy, Maharishi Markandeshwar Medical College and Hospital, Kumarhatti and District: solan (HP), India.
2. Department of Periodontology and Oral Implantology, Laxmi Bai Institute of Dental Sciences and Hospital, Patiala (Punjab), India.
3. Demonstrator, Department of Anatomy, Maharishi Markandeshwar Medical College and Hospital, Kumarhatti and District: Solan (HP), India.

Abstract:

The mandible is the strongest bone of face. The morphological structure of the mandible is that it is having arched body, two rami, two coronoid processes and two condyloid processes. The coronoid process lies on the superior border of ramus. It is conical in shape and gives the attachment to the temporalis muscle. Various authors have described three types of coronoid process according to their shapes (Triangular, Rounded and Hook shaped), and differences in size of the male and female coronoid processes. In the present 100 (60 male+ 40 female) dry human mandibles are the material for study. Different shapes are to be noted and recorded. The size of the coronoid are to be measured from different points, the differences in the size of male and female coronoid processes are recorded to determine the sex of the mandible. Photographs will be taken of different shapes. The present study compared with the standard literature and studies done by other authors. This is helpful for maxillofacial surgeons, anthropologists, traumatologists, forensic odontology and forensic medicine for the determination of sex from the fragment of the mandible.

Key words: Mandible, condyloid process, maxillofacial surgeons, fracture, grafting, forensic medicine, fragment, traumatologist.

Correspondence Address:

Dr. Gurbachan Singh Gindha,
#46- Kamal Colony, Street no. 2,
Sirhind Road, Patiala (Punjab)
INDIA Contact no. +9198720-35682
e-mail: - drgindhags@yahoo.com

QR code



Please cite this article in press as Dr. Gurbachan Singh Gindha et al, , *Morphometric Study of The Coronoid Process Of The Mandible For Its Various Shapes and Sexing Of The Mandible (A Dry Human Bone Study)*, Indo American J of Pharm Sci, 2015;2(6).

INTRODUCTION

The mandible is the largest and strongest bone of the face. It has arched body, two broad rami, two condyloid processes and two coronoid processes. The coronoid process projects upwards and slightly forwards as a triangular plate of bone. Its posterior border bounds the mandibular incisura and its anterior border continues as the anterior border of the ramus. It is a triangular, thin flat, eminent bony projection of the ramus of the mandible. The coronoid process provides the insertion to the muscle of mastication i.e. temporalis muscle. The coronoid process is rarely significantly displaced because it is splinted by the tendinous insertion of temporalis muscle [1,2].

Various authors have described the various shapes of the coronoid process. According to Issac and Holla [3], Prajapari [4] and Khan and Sharieff [5] the process is triangular, hook shaped and rounded. The shape and size of the coronoid process is influenced by dietary habit, genetic constitution, hormonal and the most important is the activity of temporalis muscle.

Pradhan et al.[6] described that the coronoid process is a membranous type of none which can be removed intra-orally without any functional deficiency and facial disfigurement for reconstruction of orbital floor deformities, alveolar defects, paranasal sinuses augmentation, non-union fracture of mandible, osseous defects reconstruction and other repairing procedure in cranio-maxillo-facial surgeries. Various morphological features of mandible show changes in reference to age and sex. It acts as an anthropological marker for detection of race.

The coronoid process is of clinical significance to the maxillofacial surgeons for reconstructive purposes Shakya [7]. Autogenous bone grafts can be obtained from ilium, rib and calvarias; but each site has its own associated morbidity. A local bone graft from the coronoid process of the mandible can be used as it can be harvested easily, minimal morbidity, shorter surgical and hospitalization time, no cutaneous scarring as bone is harvested intra-orally. A coronoid process graft can be used for alveolar defects repair, orbital floor repair, maxillary augmentation, repair of non-union fracture of mandible. The coronoid process also has been used as a donor site for sinus augmentation [8].

The coronoid process can be used as a graft material. The coronoid process graft has some advantages. It can be removed via intra-oral route and no scar will be on the skin. Another advantage is that it can be harvested very easily and safely and its harvesting time is very short [9]. The coronoid process grafts can be used for

reconstruction of orbital floor deformities, mid-face or alveolar defects and other repairing procedures in the cranio- maxillofacial surgery [10].

Bakirci [11] stated in their study that the human skeletal features are valuable for both clinical applications and determinations of racial characteristics of the different populations. Use of bone and bone fragments is also important for forensic sciences for the race, sex and weight of the body related estimations. Autologous, allograft or synthetic bone grafts can be obtained by different approaches. An autologous bone graft is taken from a part of the patient's body and can be used in another part of same person. In this way, complications such as infection, bleeding, and tissue damage is lower than allografts and so this method is preferred by surgeons.

MATERIAL AND METHOD

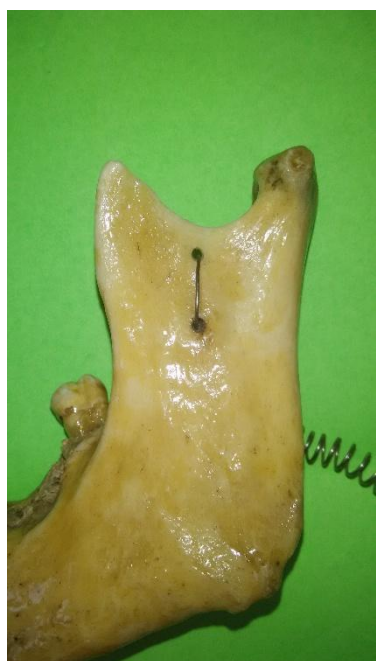The present study will be conducted on 100 known sex adult dry human mandibles (60 male and 40 female). The bones will be collected from the Department of Anatomy of Maharishi Markandeshwar Medical College and Hospital, Kumarhatti, and District: Solan (HP), India. 200 (120 male and 80 female) coronoid processes of the mandibles were selected which were well formed in shape and size. The mandibles having deformed coronoid process were discarded. The shapes of the coronoid process were counted, noted, recorded and photographed. For the measurement of the size of the coronoid process, the points were marked on the lowest point of the mandibular notch. Noted its distance from the base of the mandible. At the same height, a point will be marked on the anterior border of the ramus of the mandible. At the same height from the base of the mandible a point will be marked on the posterior border of the ramus. A line will be drawn to meet these points. A point will be marked on the top of coronoid process. Then a perpendicular will be drawn on the line drawn by meeting the three points. As this a triangle was made and all the three sides of the triangle and height of the perpendicular were measured and compared the distances of the coronoid processes of male and female mandibles for the estimation of sex of the mandible, from the differences in size of the coronoid process will tell the sex of the mandible. Compared the present study with the standard literature and studies done by other authors.

Observations:

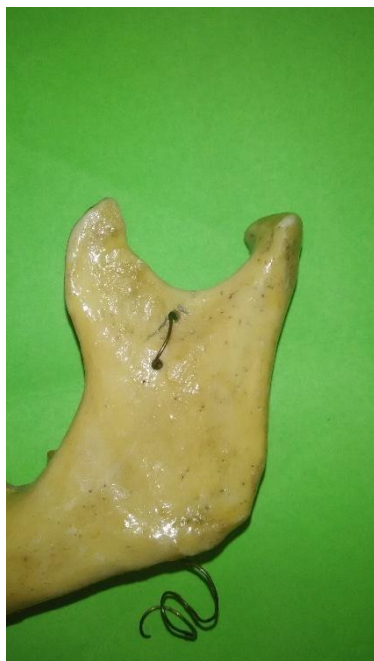The present study is concluded in the Department of Anatomy of Maharishi Markandeshwar Medical College, Kumarhatti and District: Solan (HP), India. In this study 200 (120 male and 80 female) coronoid processes are studied and variations in the shapes of the coronoid process are

seen and recorded in the **Table – I**. The mean of the measurements done of all the 200 (120 male

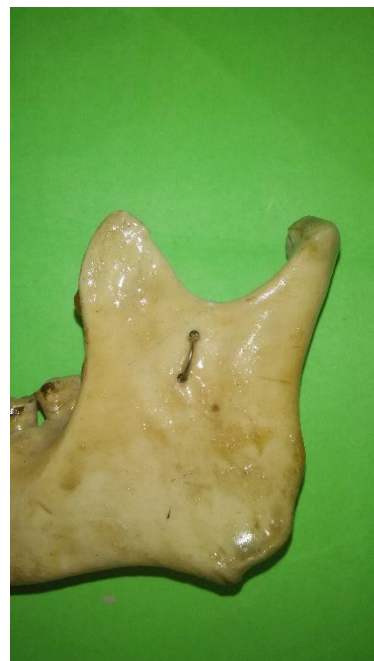and 80 female) coronoid process triangle are recorded in **Table – II**.



1. Triangular Shaped



2. Hook Shaped



3. Rounded Shaped

Total Number of Coronoid Processes Studied = 200

Table – I

Showing Types of Coronoid Processes Found and Their Percentage (% age)

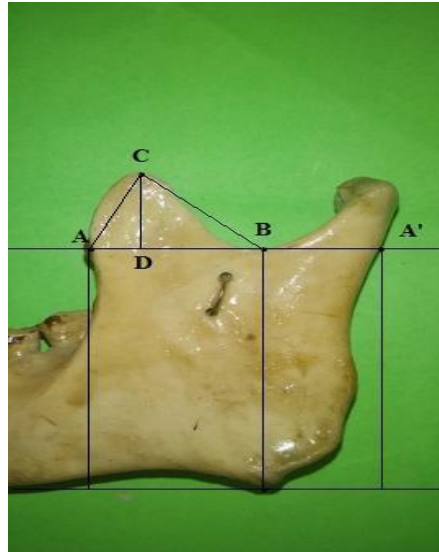
Triangular		Hook shaped		Rounded	
Right sided	Left sided	Right sided	Left sided	Right sided	Left sided
62	60	26	25	12	15
31%	30%	13%	12.5%	6.0%	7.5%

Total number of each type found and their % age:-

Triangular type = 61.0%

Hook shaped = 25.5%

Rounded type = 13.5%



Measuring of Coronoid Process

Table - II

Average Lengths Of In Each Arm in mm of Right and Left Coronoid Processes
Measurements of Triangles in Male and Female Mandibles

Sex	Right coronoid process				Left coronoid process			
	AB	AC	BC	CD	AB	AC	BC	CD
Male	20.20	21.00	20.00	18.00	19.40	20.40	18.60	17.00
Female	19.00	20.20	19.00	17.00	18.60	19.40	18.40	16.20

Table -III

Mean of lengths in male and female sides of coronoid process:

In male				In female			
Right	Left	Mean	SD	Right	Left	Mean	SD
AB: - 20.20 + 19.40 = 19.80 mm ± 1.261				AB: - 19.00 + 18.60 = 18.80 mm ± 1.030			
AC: - 21.50 + 20.70 = 21.20 mm ± 1.691				AC: - 20.20 + 19.40 = 19.80 mm ± 1.781			
BC: - 20.00 + 18.60 = 19.30 mm ± 1.923				BC: - 19.00 + 18.40 = 18.70 mm ± 1.706			
CD: - 19.40 + 18.70 = 19.05 mm ± 1.794				CD: - 17.00 + 16.20 = 16.60 mm ± 1.499			

In the present study it was found that most common type of the coronoid process is the triangular type. It is present in 61.00% of cases. Second common type is hook shaped, and present in 25.5% of cases and third type of coronoid process is rounded type which is found to be present in 13.5% of cases (Table - I).

It was found in the present study that right coronoid process is longer than the left coronoid process because it depends upon eating and chewing habits.

Most of the person eat and chew on right side. Because of the pull by the right temporalis muscle the coronoid process develops more on right side than the left side. In males it is well developed and muscle attachment is more prominent in male than female coronoid process.

The measurements of the coronoid process for the determination of sex from the coronoid process, the male coronoid process is longer than the female coronoid process. CD represents the height of the

coronoid process; it is 19.05 ± 1.794 mm in male and 16.60 ± 1.499 mm in female. It is significantly longer in male than the female (**Table – II, Table – III**). Other sides of the coronoid process are also longer as side AC in male is 21.20 ± 1.691 mm whereas in female it is 19.80 ± 1.781 mm and side BC in male it is 19.30 ± 1.923 mm and in female it is 18.70 ± 1.706 mm, AB is the base of the triangle which is drawn on the sides of the coronoid process, it is 19.05 ± 1.794 mm in male and in female it is 16.60 ± 1.499 mm. All the sides of the coronoid process are longer in male than in female. It shows that the coronoid process in male is longer than the coronoid process of female. From the measurements of the coronoid process we can assess the sex the mandible even from its fragments by comparing the lengths of the coronoid processes of male and female. On the other hand right coronoid process is longer than left coronoid process in male as well female. This is due to eating and chewing habit. Mostly the persons eat and chew on the right side of the mouth.

DISCUSSION

The mandible is the strong and largest bone of the face. It is having arched body, two rami, two coronoid processes and two condyloid processes. Standring [1], described the coronoid process as a flat triangular process. The triangular process have also been illustrated by Hamilton [12], Romanes [13], Snell [14] and Basmajian [15]. Shakya et al.[7] showed in their study that triangular shape was more common, followed by rounded, beak type are rare. Mahajan et al [16] studied 164 mandibles (328 sides) in their study. They reported that hook shaped coronoid processes were found in 90 (27.43%), triangular in 160 (48.78%), and rounded in 78 (23.78%). Hook

shaped coronoid processes were found bilateral in 36, triangular in 65 and rounded in 28 mandibles. Prajapati et al.[17] reported that the triangular and hook shaped types were the most and the least prevalent in males (56% and 21.34%) as compared to Isaac and Holla (2001)² where triangular and rounded were most and least prevalent (46.5% and 30.03%) respectively. The coronoid process is of clinical significance to the maxillofacial surgeons for reconstructive purposes. Tapas [18] reported that triangular shaped coronoid process was found in 60 (60%) sides, hook shaped in 22 (22%) and rounded shaped in 18 (18%). She showed that triangular shaped of the coronoid processes were most prevalent followed by hook shaped and rounded.

Khan and Sharieff [5] reported that triangular shaped of coronoid process (67%) are more prevalent than hook shaped (30%) and rounded (3.0%). The triangular shaped is more prevalent in male (72.2%) than females (51.1%), whereas hook shaped are more prevalent in females (44.9%) than males (25.2%) and rounded are more prevalent in females (4.1%) than males (2.6%). They shown in their study that triangular shaped was more commonly present in males while female presented with rounded and hook shaped.

Desai et al [19] showed that the shapes of coronoid process was triangular in 136 (68%), hook shaped in 48 (24%) and rounded in 16 (8%) of cases. Hossain et al. (2011)²⁰ revealed that hook shaped coronoid processes were found in 126 (45%), triangular in 83 (29.65%) and rounded in 71 (25.35%). Pradhan et al. (2014)⁶ showed in their study that three variants of the coronoid process were evident with triangular being the highest (46.73%), rounded (35.3%) and hook shaped (17.93%).

Comparison of Previous Studies of Coronoid Process with Present Study in % age.

Serial No	Authors	Year of study	Triangular type	Hook Shaped	Rounded
1.	Issac & Holla	2001 ³	49.00	27.40	23.60
2.	Khan et al.	2011 ⁵	67.00	30.00	03.00
3.	Prajapat et al.	2011 ⁴	54.17	21.25	24.58
4.	Hossain et al.	2011 ¹⁹	29.65	45.00	25.35
5.	Mahajan et al.	2012 ¹⁶	48.70	27.40	23.78
6.	Bakirci et al.	2013 ⁹	20.00	60.00	20.00
7.	Tapas	2014 ¹⁷	60.00	22.00	18.00
8.	Desai et al.	2014 ¹⁸	68.00	24.00	08.00
9.	Present study	2015	61.00	25.50	13.50

CONCLUSION

In the present study the types of the coronoid process found were, triangular type (61.0%), hook shaped (25.5%) and rounded type in (13.5%). The coronoid process is of clinical significance to the maxillofacial surgeons and plastic surgeons for reconstructive purposes as it is used as graft in reconstruction of osseous defects in oral and facio-maxillary augmentation, correlation of non-union fracture of the mandible. The coronoid process makes an excellent donor graft site for reconstruction of orbital floor deformities. Through measurements of the coronoid process we can determine the sex of the mandible, which is more helpful for the (forensic medicine which are confined to know the sex of the mandibles in medico-legal and forensic odontology cases.

REFERENCES

1. Standring, S. Gray's Anatomy. The Anatomical basis of Clinical Practice. Reprinted International 40th Edition. Chapter – Mandible. Churchill Livingstone Elsevier. London (UK). (2011); page: 480 and 532.
2. Harrison, RJ. Cunningham's Text Book of Anatomy. Reprinted 12th edition. Chapter bones, the mandible. Oxford University Press. Oxford, New York, Toronto; page: 127.
3. Issac, B; Holla, SJ. Variations in the shape of the coronoid process in the adult human mandible. J Anat. Soc. India. (2001); 50 (2): 137 – 139.
4. Prajapati, VP; Malukar, O; Nagar, SK. Variations in the morphological appearance of the coronoid process of human mandible. Nat J of Med Res. (2011); 1 (2): 64 – 66.
5. Khan, T.A. H.S; Sharieff, J.H. Observation on Morphological Features of Human Mandible. In 200 South Indian Subjects. Anatomica Karnataka. (2011); 5: 44 – 49.
6. Pradhan, S; Bara, DP; Patra, S; Nayak, S; Mohapatra, C. Anatomical Study of Various Shapes of Mandibular Coronoid Process in Relation to Gender And Age. J of Dent and Med Sci. (2014); 13: 09 – 14.
7. Shakya, S; Ongole, R; Nagral, SK. Morphology of Coronoid Process and Sigmoid Notch in Orthopantomogram of South Indian Population. World J of Dentistry. (2013); 4 (1): 1- 3.
8. Kim, YK; Hwang, JW; Lee, HJ; Yun, PY. Use of Coronoid Process as a Donor site for Sinus Augmentation: A Case Report. The Int J Oral Maxillofac Implants. (2009); 24: 1149 – 1152.
9. Bakirci, S; Ari, Ilknur; Kafa, IM. Morphometric Characteristics and Typology of the Coronoid process of the Mandible. Acta Medica Mediterranea. (2013); 29: 683 – 686.
10. Choung, PH; Kim, SG. The coronoid process for paranasal augmentation in the correction of mid-facial concavity. Oral Surg Oral Med Pathol Oral Radiol Endod. (2001); 91: 28 – 33.
11. Minz, SM; Ettinger, A; Schmakel, T; Gleason, MJ. Contralateral coronoid process bone grafts for orbital floor reconstruction: An anatomic and clinical study. J Oral Maxillofac Surg. (1998); 56: 1140 – 1144.
12. Hamilton, WJ. Textbook of Human Anatomy. In: Locomotor System. 2nd edition; Macmillan. London. (1976); page: 80.
13. Romanes, GJ. Cunningham's Manual of Practical Anatomy. 15th edition, volume – 3, Head, Neck and Brain. Oxford University Press, Oxford. Reprinted 2010, (1986); page: 119.
14. Snell, RS. Head and Neck. In: Clinical Anatomy for Medical Students. 3rd edition. Little Brown and Company. Boston. (1986); page: 773.
15. Basmajian, JV; Slonecker, CE. Grant's Method of Anatomy. In: 11th edition. Willams and Wilkins. Baltimore, London. (1989); page: 516.
16. Mahajan, A; Seema; Batra, APS; Khurana, BS; Gandhi, D. Variations in the shapes of Coronoid Process in Adult Human Mandible. J of Life Sci. (2012); 9: 29 – 33.
17. Tapas, S. Morphological Variations of coronoid Process. In Dry Adult Human Mandibles. Ind J of Basic and Appl Med Res. (2014); 3: 401 – 405.
18. Desai, VC; Desai, SD; Hussain, SS. Morphological Study of Mandible. J Pharm Sci and Res. (2014); 6 (4): 175 – 177.
19. Hossain, SMA; Hossain, SMM; Banna, FAMH. Variations in the Shape of the Coronoid process in the Adult Human Mandible. Bang J of Anat. (2011); 9 (2): 75 -78.