CODEN [USA]: IAJPBB ISSN: 2349-7750

INDO AMERICAN JOURNAL OF
PHARMACEUTICAL SCIENCES

http://doi.org/10.5281/zenodo.4013163

Available online at: http://www.iajps.com *Research Article*

PERCUTANEOUS PINNING WITH CROSSED K-WIRE AND CLOSED REDUCTION FOR THE TREATMENT OF TYPE III SUPRACONDYLAR FRACTURES OF THE HUMERUS IN CHILDREN

[1]Dr Talha Hassan Shah, [2]Dr Muhammad Usman, [3]Dr Bilal Khan

[1]Allama Iqbal Medical College, Lahore

[2]Wah Medical College, Wah Cantt

[3]Allama Iqbal Medical College, Lahore

Article Received: April 2020 **Accepted:** May 2020 **Published:** June 2020

Abstract:

Aim: *To evaluate the result of closed reduction and percutaneous pinning in the treatment of type III Supracondylar fracture of the humerus in children.*

Materials and methods: *Sixty-one patients were treated for type III supracondylar fractures of the humerus in the orthopedic ward of Jinnah Hospital Lahore.*

Study design: *This is a prospective study.*

Place and Duration: *In the Orthopedic Unit II of Jinnah Hospital Lahore for one year duration from January 2019 to January 2020.*

Results: *Union was achieved in all patients; superficial pinhole infections were observed in 6 patients, iatrogenic elbow injury occurred in 3 patients, Cubitus varus and Myositis ossficans in one patient respectively. No deep infection or compartment syndrome was encountered; the results were excellent in 40 patients, good in 16 patients, good in 3 and poor in 2 patients.*

Conclusion: *Close reduction and percutaneous pinning with two K-cross wires is an effective and safe procedure with a minimum incidence of complications in the treatment of type III supracondylar fracture of the humerus.*

Keywords: *Close reduction, supracondylar fracture humerus, percutaneous pinning.*

Corresponding author:

Dr. Talha Hassan Shah,

Allama Iqbal Medical College, Lahore

QR code

Please cite this article in press Talha Hassan Shah et al., ***Percutaneous Pinning With Crossed K-Wire And Closed Reduction For The Treatment Of Type Iii Supracondylar Fractures Of The Humerus In Children .,*** *Indo Am. J. P. Sci, 2020; 07(06).*

INTRODUCTION:

The fracture of the humerus of the carpal bone is the most common fracture around the elbow in children and accounts for about 3% of all fractures in children. The supracondylar humerus fracture is caused by the extension of the outstretched arm and is divided into two types: extension type and flexion type. About 96% of supravertebral fractures have the type of extension and are further classified, as described by Gartland, according to the degree of displacement of the distal fragment. Type I is an uninhabited fracture, type II is displaced with intact posterior cortex, type III is completely displaced without contact between fragments.

The supravertebral fracture in children should be treated appropriately to prevent complications such as elbow stiffness, twist and valgus deformities, compartment syndrome, neurovascular damage, and bone cans. Various treatments are available for treating a humerus fracture in children, such as lateral shoulder adhesion, overhead skeletal fraction, closed reduction and throwing, closed reduction and percutaneous pinching, and open reduction and internal latch.

Type III supracondylar Fractures of the humerus in children are usually treated by closed reduction and transcutaneous fixation of K wires, but open reduction and fixation is performed if adequate reduction cannot be achieved by closed manipulation.

Closed reduction and two crossed K-wires, one medial and one lateral percutaneous fixation under the image enhancer are the treatment of choice. The purpose of this study was to evaluate the short-term results of closed reduction and percutaneous pinning in Gartland Type III Supracondylar Humerus fracture in our circumstances.

MATERIALS AND METHODS:

A prospective descriptive study was conducted in the Orthopedic Unit II of Jinnah Hospital Lahore for one-year duration from January 2019 to January 2020. 61 patients were included in the study all were closed Gartland type III supracondylar Humerus fractures. Patients aged 2 to 12 years were included. Patients with vascular damage were excluded from the study. There were 39 boys and 22 girls, the left side was involved in 35 patients and 26 patients in the right side. All patients were admitted to the emergency department. Detailed interview and clinical examination were carried out on admission after obtaining informed consent. Patients underwent side arm traction or were placed in the side rail for temporary stabilization. Further neurovascular condition was closely monitored. Patients were prepared for surgery the next day for surgery.

Surgical technique: under general anesthesia, the patient was scrubbed and placed on his back on the operating table with a fracture elbow placed on the main tube of the C-arm. The assistant held his hand and the surgeon applied longitudinal traction to release the fracture site, and then correct the medial and lateral displacement. The elbow was then bent at an angle of more than 90 °, holding the longitudinal fraction, the surgeon's thumb pushed the tip of the olecranon forward simultaneously at the same time, the reduction is checked by the C-arm image intensifier, after confirming the reduction, K wire diameter 1 was used to repair the fracture, 6 mm. Usually, we first place the K wire from the medial mediastinum, touching the ulnar nerve and medial mediastinum.

The ulnar nerve was pushed backwards with a straight front side, making a small incision slightly forward to the medial wrist.

Both plugs were seized, avoiding the bottom of the olecranon, after inserting the medial pin and confirming by fluoroscopy, we placed a side pin from the lateral wheel arch so that the side pin would cut the middle pin above the fracture line. Then the knee is extended, position and reduction are confirmed by the image intensifier, distal pulses are checked, the wire is bent to 90 ° and cut outside the skin and left on the skin.

The posterior splint is administered in the 80 ° to 90 ° elbow section and in the neutral part of the forearm. Every two weeks they were followed for two months and then every month for a year.

RESULTS:

All 61 patients completed follow-up. There were 39 (63.9%) men and 22 (36.1%) women. The ratio of men to women was 1.8: 1. The left side concerned 45 (73.8%) patients, and the right side concerned 16 (26.2%) patients. The average age was 6.7 years and the age range was 2 to 12 years. The results were evaluated according to Flynn 11 criteria and are given in Figure 1.

The poor result in our study was caused by ossificians myositis in one (1.64%) patient and elbow deformity in another. Iatrogenic ulnar nerve palsy occurred in 3 (4.9%) patients who completely recovered after three months. Genital tract infection in 6 (9.8%) patients who resolved after topical treatment and oral antibiotic. Deep infection and compartment syndrome were not present in our series.

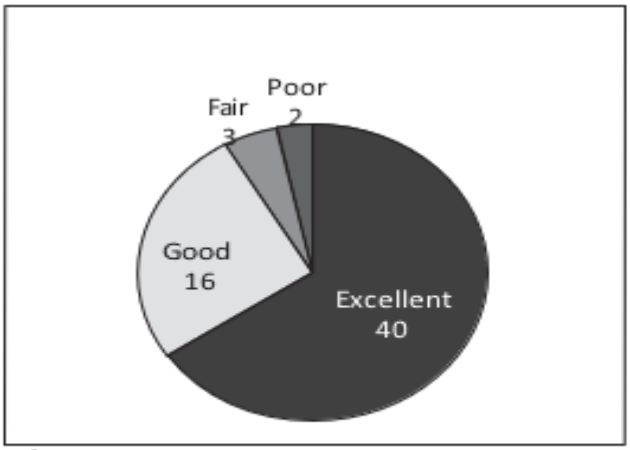

Figure 1: *Outcome of Procedure according to Flynn criteria*

DISCUSSION:

In children, supra-condylar fracture of the humerus is a common injury, and the elbow requires appropriate treatment to prevent complications such as elbow stiffness, neurovascular involvement, and compartment syndrome. Narrow reduction and cast are an older method of treatment, but the disadvantage is the loss of reduction, elbow deformation, neurovascular reconciliation caused by large flexion and a set of compartments. It has its drawbacks, such as open reduction and internal fixation, softer tissue trauma, extension of surgery time, extension of hospital stay, and increased elbow postoperative stiffness. Closed reduction and transdermal attachment is the solution to the problem of closed reduction and casting, open reduction and internal fixation. Provides skeleton stability without loss of reduction and minimal soft tissue damage. Demerit is a secondary irradiation procedure (this cannot be done without an image intensifier), pin tract infection, ulnar nerve damage, and sometimes the K wire removal.

The results of our study were comparable to local and international studies. Excellent and good results in our study, with 91.2% Zionts, Swenson, Boggione et al., Jong Sup et al. Compared to the Boogione and Shim studies in two of our patients (3.2%), our series achieved poor results with the development of properly ossified myositis and ulceration of varicose veins. Iatrogenic ulnar nerve injury was observed in 3 patients who healed within three months without intervention. In our series, no full nerve cut was observed and can be compared to Gosen. Overall patient satisfaction in terms of functional and cosmetic results was excellent.

CONCLUSION:

Closed reduction and cross percutaneous pinning for the treatment of type III supracondylar fracture of humerus in children is efficient, safe and cost effective method. It gives excellent stabilization of the fracture site.

REFERENCES:

1. Rupp, Markus, Christoph Schäfer, Christian Heiss, and Volker Alt. "Pinning of supracondylar fractures in children–Strategies to avoid complications." *Injury* 50 (2019): S2-S9.
2. Gopinathan, Nirmal Raj, Mohammad Sajid, Pebam Sudesh, and Prateek Behera. "Outcome analysis of lateral pinning for displaced supracondylar fractures in children using three kirschner wires in parallel and divergent configuration." *Indian journal of orthopaedics* 52, no. 5 (2018): 554.
3. Na, Yuyan, Rui Bai, Zhenqun Zhao, Changxu Han, Lingyue Kong, Yizhong Ren, and Wanlin Liu. "Comparison of lateral entry with crossed entry pinning for pediatric supracondylar humeral fractures: a meta-analysis." *Journal of orthopaedic surgery and research* 13, no. 1 (2018): 68.
4. Li, Mingjing, Jian Xu, Tao Hu, Ming Zhang, and Fan Li. "Surgical management of Gartland type III supracondylar humerus fractures in older children: a retrospective study." *Journal of pediatric orthopedics. Part B* 28, no. 6 (2019): 530.
5. al-Algawy, Alaa A. Hussein, Adil Hasan Aliakbar, and Ibrahim HN Witwit. "Open versus closed reduction and K-wire fixation for displaced supracondylar fracture of the humerus in children." *European Journal of Orthopaedic Surgery & Traumatology* 29, no. 2 (2019): 397-403.
6. Aher, Deepak K., Rajesh Jamoria, Harendra Singh, and Rajesh Kumar Mishra. "To compare the functional outcome of cross k-wires v/s lateral k-wires in Gartland type-III supracondylar humerus fracture in paediatric age groups." *International Journal of Orthopaedics* 4, no. 3 (2018): 601-605.

7. Sapkota, Krishna, Krishna Wahegaonkar, Niraj Ranjeet, Pabin Thapa, Upendra Jung Thapa, and Pratyenta Raj Onta. "Comparison of cross pinning versus lateral three pins in type three supracondylar fracture of distal humerus in children." *Asian Journal of Medical Sciences* 10, no. 2 (2019): 58-61.
8. Palange, Nikhil D., G. S. Prasannakumar, Akash Mane, and Eknath Pawar. "A comparison between percutaneous cross k wire and lateral k wires fixation in management of Type III Gartland paediatric supracondylar fractures." *International Journal of Orthopaedics* 5, no. 2 (2019): 119-122.
9. Himanshu, Harindra, Bijoy Kumar, and Lal Bahadur Manjhi. "A Comparative Study of Outcome of Percutaneous Lateral And Crossed Pinning In The Treatment of Type Iii Supracondylar Fractures of Humerus In Children."
10. Ali, Abid. "Supracondylar displaced fractures of elbow in children treated with closed reduction and percutaneous K-wire fixation." *Pak J Surg* 34, no. 1 (2018): 58-61.
11. Sadek, Abdelrahman A., Mostafa I. Ibrahim, Hussam Eldin M. Elazab, and Hassan Hamdy Abdel Rahman. "Comparison of Fixation of supracondylar humeral fractures in children by lateral cross-wiring technique versus traditional lateral pinning." *Sohag Medical Journal* 22, no. 1 (2018): 265-271.
12. Yeotiwad, Ganesh R., Harshad G. Argekar, Sagar G. Daliya, and Chintan S. Vaidya. "FUNCTIONAL AND RADIOLOGICAL OUTCOME OF SUPRACONDYLAR HUMERUS FRACTURES IN CHILDREN WITH LATERAL PINNING: A RETROSPECTIVE ANALYSIS." *Global Journal For Research Analysis (GJRA)* 8, no. 9 (2019).
13. Vikram, Ashutosh. "Functional outcome of displaced supracondylar fracture humerus in children treated by closed reduction and percutaneous pinning with Kirchner wires: An observational study." *International Journal of Orthopaedics* 5, no. 4 (2019): 757-761.
14. Single, Open Reduction Internal Fixation-A. "Outcome of Type III Supracondylar Fracture Humerus in Children Treated By Percutaneous Pinning Technique versus Open Reduction Internal Fixation-A Single Center Experience."
15. Saeed, Usama Bin, Muhammad Waseem, Allah Rakha Hassan, Zeeshan Ali Khan, Dilshad Gill, and Shahbaz Ahmad. "Supracondylar fracture, buried vs non buried K wires." *The Professional Medical Journal* 27, no. 03 (2020): 467-471.
16. Roshan, D., and D. Shereen. "A clinical study of closed reduction and crossed percutaneous pinning of supracondylar fracture of elbow in children." *International Journal of Orthopaedics* 4, no. 4 (2018): 478-480.
17. Mallik, Sumon, Lata Majumder, Muhammad Abdul Wadud, and Cyrus Shakiba. "Outcome of Percutaneous Pin Fixation of Supracondylar Fracture Type 2 And 3: A Hospital Based Retrospective Study in Jalalabad Ragib Rabeya Medical College Hospital, Bangladesh."
18. Saeed, Usama Bin, Muhammad Waseem, Allah Rakha Hassan, Zeeshan Ali Khan, Dilshad Gill, and Shahbaz Ahmad. "COMPARISON OF BURIED VS NON BURIED K WIRES FOR TREATMENT OF SUPRACONDYLAR FRACTURE." *Professional Medical Journal* 27, no. 3 (2020).
19. Shalaby, M. S. M., M. E. Attia, and R. H. Elkady. "Evaluation of Percutaneous Pinning Techniques in Management of Pediatric Supracondylar Humeral Fractures." *Prensa Med Argent* 106 (2020): 2.
20. Kumar, Eesari Kalyan, and Abdul Bari. "A comparative study of clinical outcome of surgical management of supracondylar fracture of humerus in children with crossed (Medial and Lateral) k-wire fixation and two lateral k-wire fixation." *International Journal of Orthopaedics* 6, no. 1 (2020): 53-57.