



CODEN [USA]: IAJ PBB

ISSN: 2349-7750

INDO AMERICAN JOURNAL OF PHARMACEUTICAL SCIENCES

<http://doi.org/10.5281/zenodo.2603240>
Available online at: <http://www.iajps.com>

Research Article

VOLVULUS IS FACED IN THE SITE OF THE CAECUM AND SIGMOID COLON: 28 YEARS OLD PATIENTS DIAGNOSED WITH DESCENDING COLON VOLVULUS

¹Dr Moin Ata, ²Qurat ul Ain, ³Dr Muhammad Uzair Asghar¹THQ Hospital Shahkot²Jinnah Hospital Lahore³Medical Officer Basic Health Unit 322/JB Tehsil and District Toba Tek Singh

Article Received: January 2019

Accepted: February 2019

Published: March 2019

Abstract:

Usually, volvulus is faced in the site of the caecum and sigmoid colon. Intestinal blockage is significantly caused by volvulus. The existence of descending colon volvulus is seriously infrequent. This case study is related to a male patient of 28 years of age who was studied at Services, Hospital, Lahore in December 2017. There was an indication of large bowel blockage according to signs and symptoms. On investigation, descending colon volvulus was faced.

Thereupon after resection of the redundant colon, a colostomy was formed.

Keywords: Volvulus, Caecum, Sigmoid, Colon, Bowel, Blockage and Intestinal.

Corresponding author:

Moin Ata,

THQ Hospital Shahkot

QR code



Please cite this article in press Moin Ata et al., *Volvulus Is Faced In The Site Of The Caecum And Sigmoid Colon: 28 Years Old Patients Diagnosed With Descending Colon Volvulus.*, Indo Am. J. P. Sci, 2019; 06(03).

INTRODUCTION:

The existence of descending colon volvulus is very infrequent. In history, only one such report has been presented. The identification is made on the basis of an index of doubt upon record and assessment along with CT scan indicating the features of “whirl sign”. Complexities can be avoided through resection of the redundant colon and prompt surgical exploration.

CASE REPORT:

This case report is about a male. The age of the male was 28 years. He was suffering from a single episode of vomiting, constipation, serious colicky abdominal discomfort, more in the left hemi-abdomen. The patient was examined. His blood pressure was 110/65 mmHg and his pulse was 108 beats/minute. Rectum was observed digitally. It was found empty. The assessment of the abdomen indicated gross distention with visible gut loops and mild tenderness in the left upper abdomen. Remaining common physical assessment was not productive. X-Ray was done for the abdomen. Grossly dilated small and large gut loops up to splenic flexure were observed on X-Ray (Figure – I). The large gut mechanical blockage was identified and the operation was arranged. All baseline inspections were normal. The arrangement was made for midline laparotomy. We faced volvulus of descending colon through 180 degrees in its middle part. Its peritoneum was immoderately lengthy and moving upon unfolding. The expansion was observed in the proximal gut and it was disintegrated distally. In order to avoid regularity, it was decided to resect the extra colon, although gut was manageable. Both the ends were brought outside as colostomy stomas after resection. For histopathology, the resected was sent and the abdomen was dissolved. After five days, patients recovered and discharged. It was considered that histopathology was a common colonic portion with normal ganglia.

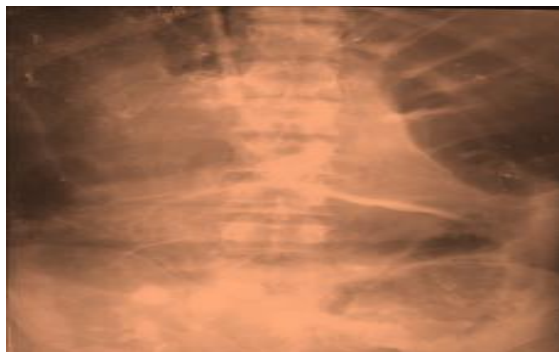


Figure – I: X-ray abdomen supine, showing distended Colon up to the splenic flexure

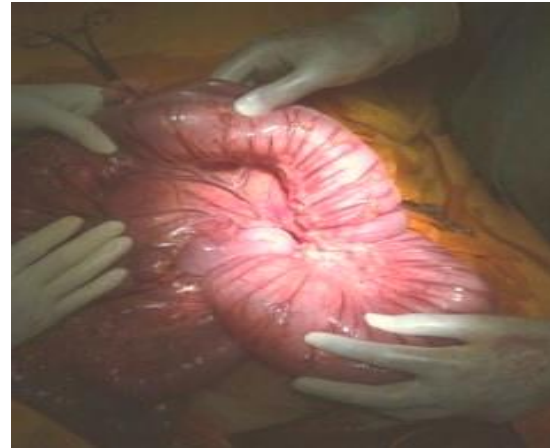

Figure – II: Descending colon with persistent long mesocolon

DISCUSSION:

Usually, volvulus is faced in the caecum and sigmoid colon [1]. Folding or axial movement of a segment of bowel about its mesentery is termed as a volvulus. About 8% of the intestinal blockage is related to volvulus [2]. In the process of disorder, there observed an uncommon association of splenic flexure. It was due to the surgical categorization of fixation organs that is gastro-colic, phrenic-colic and splenic-colic ligaments or due to congenital absence [3]. The existence of descending colon volvulus is very infrequent. In history, only one such report has been presented [4]. Colonic wall necrosis, gangrene and finally excavation if the situation is not directed punctually [5]. Similar to sigmoid volvulus, the presentation and treatment of volvulus are identical. Typical whirl sign in the left upper abdomen, a high index of doubt, comprehensive record and assessment are some basics of identification [6]. To avoid gut from strangulation, it is necessary to carry out punctual surgical exploration [6, 7]. As the chance of continuation is linked with conservative methods so, resection of the associated colonic segment is managed [8, 9]. In our case study, resection of the redundant colon was carried out to the surface as double barrel colostomy stoma. Because our patient had serious volvulus. His colon was also extensively loaded with faecal matter.

CONCLUSION:

It is concluded that disorder can be indicated by the detailed record, a high index of doubt, complete assessment and typical “whirl sign” on CT Scan. Regular long mesocolon is associated with descending colon volvulus. The most secure method of management of disorder is punctual surgical

exploration with resection of the redundant colonic segment.

REFERENCES:

1. Mallick IH, Winslet MC. Ileosigmoid knotting. *Colorectal Dis.* 2004; 6: 2205.
2. Mellor SG, Phillips RKS. The aetiology and management of sigmoid volvulus in the United Kingdom: How much colon need be excised? *Ann Roy Coll Surg Engl* 1990; 72: 193-5
3. Hiltunen K, Syrj H, Matikainen M. Colonic volvulus. Diagnosis and results of treatment in 82 patients. *Eur J Surg* 1992; 158: 607-11.
4. Winslet MC. Intestinal Obstruction. In: Williams NS, Bulstrode CJK, O'Connell PR, editors. *Bailey & Love's Short Practice of Surgery*. London, UK: Edward Arnold Ltd, 2008.p.1188-1203.
5. Chen A, Yang FS, Shih SL. CT Diagnosis of volvulus of the Descending Colon with persistent Mesocolon. *AJR* 2003; 180: 1003-6.
6. Ataman Alp SS, Oren D, Basoglu M, Yildirgan MI, Balik AA, Polat KY, et al. Ileosigmoidal knotting: Outcome in 63 patients. *Dis Colon Rectum* 2004;47: 90610.
7. Vyas KC, Joshi CP, Misra S. Volvulus of descending colon with anomalous mesocolon. *Indian J Gastroenterol* 1997; 16: 34 5.
8. Kedir M, Kotisso B, Messele G. Ileosigmoid knotting in Gondar teaching hospital north-west Ethiopia. *Ethiop Med J* 1998; 36:255-60.
9. Mindelzun RE, Stone JM. Volvulus of the splenic flexure: radiographic features. *Radiology* 1991; 181: 221 3.