



CODEN [USA]: IAJ PBB

ISSN: 2349-7750

**INDO AMERICAN JOURNAL OF
PHARMACEUTICAL SCIENCES**<http://doi.org/10.5281/zenodo.2589219>Available online at: <http://www.iajps.com>

Research Article

**A RESEARCH STUDY TO ASSESS THE PRE AND POST
ECHOCARDIOGRAPHIC OUTCOMES OF SURGICAL
INTERVENTION OF FALLOT TECHNOLOGY**¹Dr. Khizra Younas, ²Dr. Sadia Siddique, ³Dr. Hafsa Mahmood¹Faisalabad Medical University.

Article Received: December 2018

Accepted: February 2019

Published: March 2019

Abstract:

Objective: The main objective of the study was to put side by side the echocardiographic conclusion prior to and subsequent to the surgical revamp of Tetralogy of Fallot.

Methods: The study was intermediary which was conducted at Jinnah Hospital, Lahore (September 2017 to October 2018). It includes the patients who had undergone the therapy of Tetralogy of Fallot. Physical analysis, trunk radiography, and electrocardiography were done before applying echocardiography. SPSS was used to investigate the data established.

Results: Total patients were 30 which were considered in the study. Out of which 10 were females and 20 were males. The average age of patients before surgery was (47.40 – 21.34) months. And the average age after surgery was (74.46 – 20.63) months. According to the conclusion of the right heart, Z scores for climax E speed, climax A speed, phase prior to expulsion, isovolumic recreation time, myocardial performance catalogue and isovolumic reduction time were clearly dissimilar. In the left heart following characteristics were diverse from each other: aortic, left atrium, left ventricular end-systolic aspect, left ventricular end-diastolic aspect, alternation time, climax E speed, A speed, climax E velocity, climax A speed, pre-expulsion time, pre-expulsion phase, a restriction portion and expulsion portion.

Conclusion: We can easily judge the heart performance by right ventricle performance index.

Keywords: Echocardiography, Tetralogy of Fallot, Myocardial performance index, Children.

Corresponding author:**Dr. Khizra Younas,**

Faisalabad Medical University.

QR code



Please cite this article in press Khizra Younas et al., A Research Study To Assess The Pre And Post Echocardiographic Outcomes Of Surgical Intervention Of Fallot Technology., Indo Am. J. P. Sci., 2019; 06(03).

INTRODUCTION:

The most common cardiac disorder is Tetralogy of Fallot. It is a cyanotic inherited disease. It has been observed that this disease is present in 0.26 – 0.8 in 1000 births of the children. Tetralogy of Fallot is 10% inherited disorder. The one common warning sign, amount of cyanosis, and quantity of right ventricular hypertrophy is the complexity in right ventricle loss hindrance. The time period for complete healing of surgery is 4 – 12 months. In some patients, no indication of the disease appears and they enjoy a normal and healthful life. However, sometimes potentially fatal complications of sickness appear. These complications include abnormal heartbeat rhythm and abrupt death. It is compulsory to trail patients who undergo therapy of TOF. It will give us knowledge about enduring anatomical issues, level of pulmonary stenosis or vomiting and systolic and diastolic utility of both ventricles.

Heart recital can be easily detected by using an appropriate means called Echocardiography. We can easily measure the myocardial performance index (MPI) by dividing the summation of isovolumic retrenchment time and isovolumic recreation time to expulsion time. By complete therapy of heart may change or improve the functioning of the heart.

Imaging techniques are inadequate by the specific arithmetical form of RV^3 , even though it is essential to judge the RV role to handle the children anguish from CHD. MPI and Tei Index were used in earlier time periods to determine the systolic and diastolic purposes in the heart. One study was organized among patients with the transformation of huge vessels. This study stated that in a systemic RV, MPI can evaluate the comprehensive role of the ventricles and it can estimate its ejection fraction with adequate precision. In another study, multivariate deterioration examination was done. According to this study, pulmonary scarcity, the existence of a tricuspid deficiency, or interval of QRS in electrocardiogram cannot bring change or affect the MPI. This study reaches a conclusion that after complete therapy treatment of TOF, MPI is trouble-free and trustworthy manifestation for estimation of RV functions. Another study reported that Doppler echocardiography can measure effort able MPI and predicts sufferer at high danger of ventricular irregularity. According to the results of another study, if MPI increased it will reduce the RV EF and additional competence in victims after treatment. It was mentioned by a study reports that rise in RV volume after surgical treatment can damage the working of the left ventricle. It can change the ventricular function by creating universal motorized desynchrony. Another study also mentioned that if MPI measurement was done by tissue technique, it can

quickly detect variations in the tightening quality of LV. But preload and afterload changes greatly affects its working abilities.

We can formulate a proposition of the recent study that TOF correction prior to and following in the right and left ventricle does not change the result of echocardiography. There were only a few such types of studies in various countries. In Iran, it was the first study of this type. The objective of this study was to evaluate the echocardiographic result prior to and following surgical rectification of TOF. Moreover, the use of Doppler echocardiography as a straightforward, economical and reproducible process for judgment of cardiac function was also investigated during the study.

PATIENTS AND METHODS:

The study was intermediary which was conducted at Jinnah Hospital, Lahore (September 2017 to October 2018). It consists of patients who had undergone surgery of TOF. They are also conversant that prior to enrolment in study permission of the parents was obtained. Substantial assessment, chest radiography, and brain tests of patients were performed before echo radiography. A patient whose surgery was done 6 months ago was included in the study. One Pediatric heart specialist used the same device for Echocardiography.

Conditions used for echocardiography include supine position and without respiring for two days. M-Mode and Doppler were two main processes used for Echocardiography. Mean value obtained during each factor was measured in three cardiac series. M-Mode descriptions were gained at the level of the tips of mitral valve cusps at the parasternal stripe. Systolic and diastolic subsequent wall breadth left ventricular end-systolic diameter, left ventricular end-diastolic diameter, EF and shortening portion were calculated by using M-Mode and Doppler methods. While we can calculate the speed of blood flow through valves and E-speed, A- speed, ET and pre-ejection time, E/A, PEP/ET percentages and IRT by using Pulsed-Doppler. The results obtained by M-Mode and Doppler methods were gathered on the article at a rate of 50mm/sec. For calculations of MPI, the taster volume present at the endpoints of the tricuspid regulator and mitral regulator leaflet in the uppermost compartment outlook enabled calculation of A. Where A is the portion of time between the initiate and end flow of trans-mitral and trans-tricuspid flow. For the calculation of the B, the position of the sample volume was changed. It was changed from the left ventricular outflow tract just below the aortic valve. Outflow speed of the R was also observed. It was preserved from the parasternal short axis perspective. Doppler

sample volume was kept just posterior to the pulmonary valve for the dimension of B. We can calculate the MPI or Tie index by using the following relation: $a-b/b = (IRT+ICT)/ET$.

SPSS was used to examine the data obtained. Allocation of data based on basic capricious was recognized by the normality test. If the normality was pragmatic, the examination was accomplished by paired t-test; if normality was not observed, a non-parametric test was used. Non-parametric tests include the Wilcoxon signed-rank test.

RESULTS:

10 were females and 20 were males out of total of 30 patients. The average age of the patients was 47.4021.34 prior to therapy and the age was enhanced to 74.40-20.34 after the therapy. The duration of the time period for surgery was 37.86-18.27 mostly.

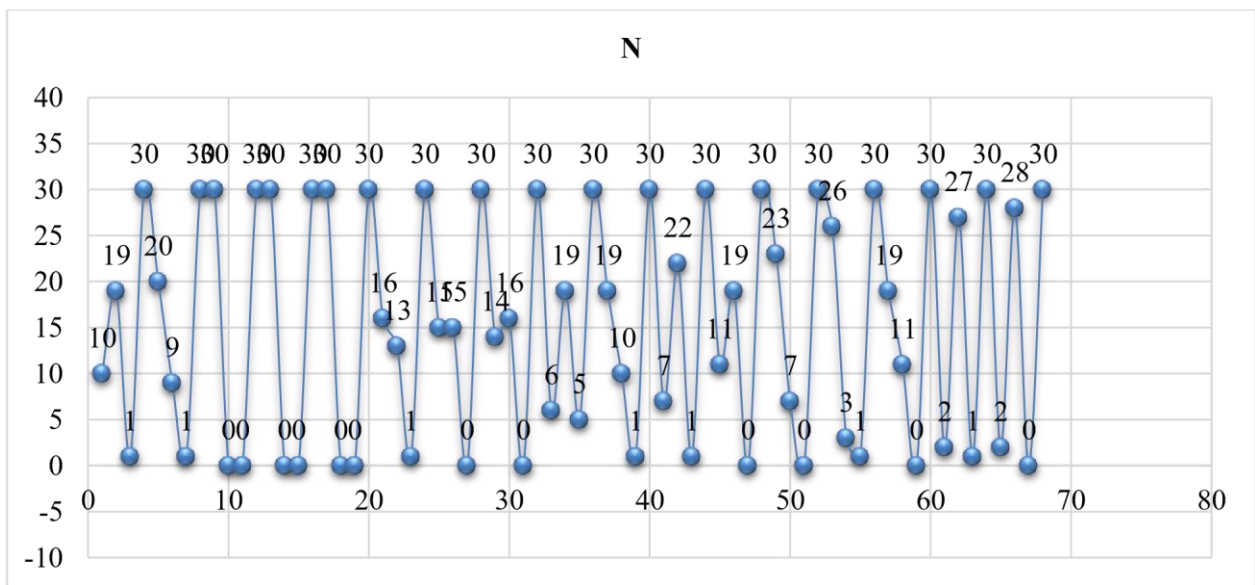
It is notable from the data that patients have higher score after the surgery with left atrium about 63.3%. Factors of AO, LA, LVESD, LVEDD, deceleration time, E/A, A, PEP/ET, PEP, SF and EF had a noteworthy variation after surgical treatment in case of the left heart.

Table – I: Parameters calculated in left ventricle prior and subsequent to surgery

Pairs		N	Mean Rank	Sum of Rank	Z	Two-tailed P-Value
LA/AO _a -LA/AO _b	NR*	10	20.2	202	-0.3	0.737
	PR**	19	12.26	233		
	Ties	1				
	Total	30				
Aoa-Aob	NR	20	15.98	319.5	-2.2	0.027
	PR	9	12.83	115.5		
	Ties	1				
	Total	30				
LA _a -LA _b	NR	30	15.5	465	-4.8	0
	PR	0	0	0		
	Ties	0				
	Total	30				
LVDES _a -LVDES _b	NR	30	15.5	465	-4.8	0
	PR	0	0	0		
	Ties	0				
	Total	30				
LVDEDD _a -LVDEDD _b	NR	30	15.5	465	-4.8	0
	PR	0	0	0		
	Ties	0				
	Total	30				
MPI _a -MPI _b	NR	16	18.63	298	-1.7	0.082
	PR	13	10.54	137		
	Ties	1				

	Total	30				
ICT _a -ICT _b	NR	15	14.07	211	-0.4	0.658
	PR	15	16.93	254		
	Ties	0				
	Total	30				
IRT _a -IRT _b	NR	14	15.46	216.5	-0.3	0.742
	PR	16	15.53	248.5		
	Ties	0				
	Total	30				
DT _a -DT _b	NR	6	9.08	54.5	-2.9	0.004
	PR	19	14.24	270.5		
	Ties	5				
	Total	30				
E/A _a -E/A _b	NR	19	18.05	343	-2.7	0.007
	PR	10	9.2	92		
	Ties	1				
	Total	30				
A _a -B _b	NR	7	12.79	89.5	-2.8	0.006
	PR	22	15.7	345.5		
	Ties	1				
	Total	30				
E _a -E _b	NR	11	12.59	138.5	-1.9	0.053
	PR	19	17.18	326.5		
	Ties	0				
	Total	30				
PEP/ET _a -PEP/ET _b	NR	23	18.35	422	-3.9	0
	PR	7	6.14	43		
	Ties	0				
	Total	30				
PEP _a -PEP _b	NR	26	15.79	410.5	-4.2	0
	PR	3	8.17	24.5		
	Ties	1				
	Total	30				
ET _a -ET _b	NR	19	16.11	306	-1.5	0.13
	PR	11	14.45	159		
	Ties	0				

	Total	30				
FS _a -FS _b	NR	2	14.5	29	-4.1	0
	PR	27	15.04	406		
	Ties	1				
	Total	30				
EF _a -EF _b	NR	2	10.75	21.5	-4.3	0
	PR	28	15.84	443.5		
	Ties	0				
	Total	30				



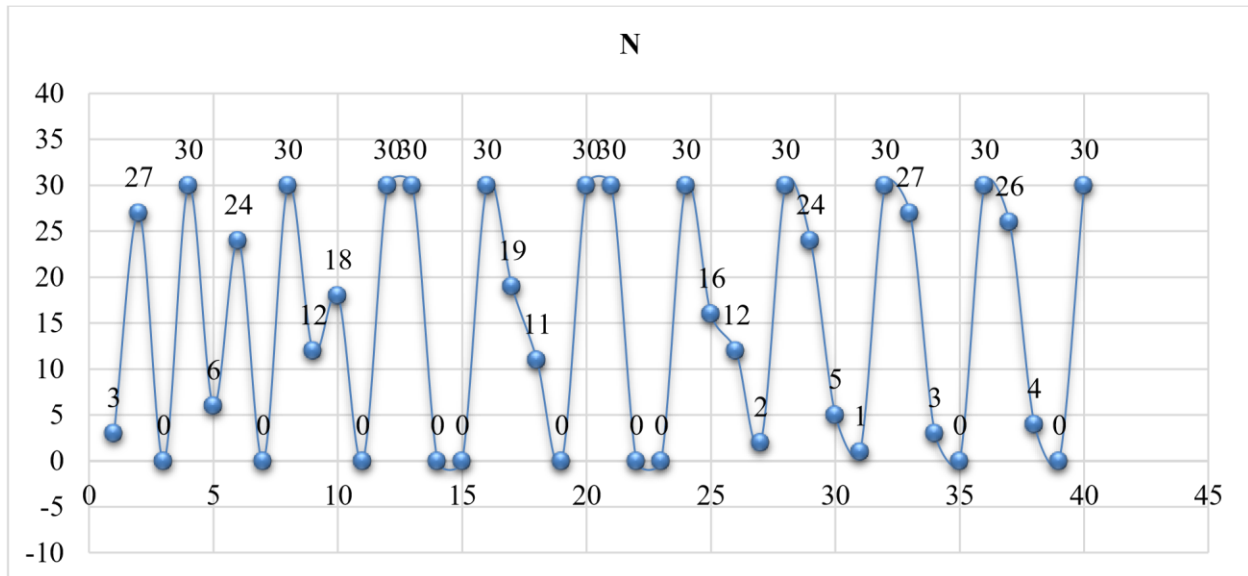
NR*, Negative ranks, PR*, Positive ranks.

AO, Aortic; LA, Left atrium; MPI, Myocardial performance index; IRT, Isovolumic relaxation time; ICT, Isovolumic contraction time; DT, Deceleration time; E, Peak E velocity; PEP, Pre-ejection period; ET, Ejection time EF, Ejection fraction; SF, shortening fraction; LVESD, left ventricular end-systolic dimension; LVEDD, Left ventricular end-diastolic dimension.

Table – II: Parameters calculated in right ventricle prior to and subsequent to surgery

Pairs		N	Mean Rank	Sum of Rank	Z	Two-tailed P value
Ea-Eb	NR*	3	7.5	22.5	-4.32	0
	PR**	27	16.39	442.5		
	Ties	0				
	Total	30				
Aa-Ab	NR	6	12.08	72.5	-3.29	0.001

	PR	24	16.35	392.5		
	Ties	0				
	Total	30				
E/Aa-E/Ab	NR	12	15.67	188	-0.92	0.36
	PR	18	15.39	277		
	Ties	0				
	Total	30				
PEPa-PEPb	NR	30	15.5	465	-4.78	0
	PR	0	0	0		
	Ties	0				
	Total	30				
ETa-ETb	NR	19	14.74	280	-0.98	0.33
	PR	11	16.82	185		
	Ties	0				
	Total	30				
PEP/Eta- PEP/ETb	NR	30	15.5	465	-4.78	0
	PR	0	0	0		
	Ties	0				
	Total	30				
DTa-DTb	NR	16	12.72	203.5	-0.01	0.991
	PR	12	16.88	202.5		
	Ties	2				
	Total	30				
IRTa-IRTb	NR	24	15.83	380	-3.52	0
	PR	5	11	55		
	Ties	1				
	Total	30				
MPIa-MPIb	NR	27	16.93	457	-4.62	0
	PR	3	2.67	8		
	Ties	0				
	Total	30				
ICTa-ICTb	NR	26	16.46	428	-4.02	0
	PR	4	9.25	37		
	Ties	0				
	Total	30				



Factors E, A, PEP, IRT, MPI, and CTI shows a notable variation in case of the right heart.

DISCUSSION:

For surgical improvement of TOF, mostly the methods which are used to detect variations in the function of the heart are omnipresent and expensive. That's why in our study, we use the simple, accurate and cheap method for the detection of cardiac functions which is echocardiography. MPI is a term which can be defined as the summation of isovolumetric cardiac action divided by ET. It could be calculated independently for the right and left the heart. MPI can be used greatly for the detection of systolic and diastolic workings. During the experimentation on patients who had been undergone the treatment with doxorubicin, it was observed that MPI was greater in cases than in control. This was due to greater IRT and reduced ET. A study was organized on the importance of MPI in the estimation of actions of the heart. The study was organized on the patients who had undergone therapy of TOF. The study explained that the RV MPI was below the normal range unpredictably, which means that workings of right and left ventricles vary. The results of this study disagree with the results of the current studies. According to our study LV ICT increased after the surgical treatment, but in that study, LV MPI was also considered to reduce due to a diminution in ICT. Another study was organized to identify the association between LV asynchrony and right bundle branch block subsequent patients undergoing surgery for TOF. Patients having right bundle branch block assessed by ECG showed considerably privileged MPI alliance with local and international LV dysfunction. According to our study most patients had an indication of bundle branch

block; this can clarify the increased MPI in our study. TOF patients, whose pulmonary recapitulation was completely corrected by surgery, are followed by a study. The relationship between RV function and QRS duration of these patients was analyzed following these patients in that study. Patients with rigorous pulmonary recapitulation were observed to have more MPI than patients with less pulmonary recapitulation. The reason was the reduced RV EF. The association between the size of the RV and QRS period were also pragmatic. The only a single case of the extremely harsh condition of pulmonary recapitulation was observed in our study. Subsequent surgical revamp of TOF brain natriuretic peptide may increase relative to the magnitude of right heart compartment and sternness of pulmonary shortage. In the same study, the echocardiographic parameters of the patients raised as observed in our study. Studies were also arranged on patients treated from TOF using Cardiovascular Magnetic Resonance. These studies give clues with considering to ventricular system and medical possessions in these patients. The close affiliation between the level of PR and RV diastolic importance and fondle volume were demonstrated by only a few authors. Once the compensatory system of the RV fails, mass to volume proportion, end-systolic volume raises, and EF reduces, analogous to LV function in meticulous constant AO recapitulation. Another study explained that the rise in RV wall pressure, a diminution in RV EF, and symptoms in patients with cured TOF could be interconnected. Some other factors also affect the RV mechanism critically. These factors include the spatial scope and

magnitude of dusky of the outflow patch, RV fibrosis, impaired RV diastolic function and LV dysfunction.

It is possible that long conduction time and desynchrony of RV reduction play an important supplementary part to RV function. In the natural history of meticulous AO recapitulation, irretrievable myocardial diseases appear after reversible ventricular abnormality. It has been observed that the same thing happens after the therapy of TOF.

The results of one study indicate that RV and LV show a sluggish reaction to dobutamine pressure. It implies that the LV task is negatively exaggerated by the impaired system. Research was published that experimented on patients with mended TOF patients. This research practised CMR on these patients. They observed the almost straight relationship between RV EF and LV EF.

One study was arranged to know the causes of delayed repairing of TOF among patients. The study concluded that the one common cause of delayed rectification is the myocardial dysfunction regardless of regular Doppler echocardiography results. In these patients, tissue Doppler echocardiography can be greatly significant because it plays an important role in estimating severe responses and long-term estimation of cardiac preserve function.

It was shown by another study that the major objections regarding echocardiography were observed in children who were about 0.2 to 2%. It was also recognized that echocardiography is easy to use and easily available for the patients. It's easily transportable, don't give any harmful rays, sedation is low and necessities in young patients. Additionally, the internal structure of the cell, local functional evaluation, diastolic function, judgment of pressure ramp, strain imaging and foetal imaging can also be evaluated using this apparatus.

In the identification of functions of ventricles, flow quantification, quantification of valve recapitulation, description of tissues, myocardial feasibility and first-pass perfusion CMR is better than other imaging modalities and is a most accurate one. In consideration of internal heart morphology, additional vasculature of heart, imaging of coronary artery, trachea and major stem bronchi Cardiac computed tomography (CCT) is used which is more accurate than other imaging modalities. Nuclear Scintigraphy is used in the evaluation of the feasibility of myocardium and first pass spreading and pressure imaging and is better than other imaging modalities.

Another study explained that despite awkward reverberation of subsequent heart therapy, echocardiography remained the most appropriate imaging modality in patients with CHD.

Echocardiography is considered more appropriate than CMR because it can analyze the obvious foramen oval, structural abnormalities of valve leaflets and their suspensors machinery and infective endocardial vegetations bitterly than CMR. The superb spatial declaration can be obtained by using CCT and it also has unhindered admittance in much shorter attainment times than CMR. CCT can be more widely used for imaging of epicardial coronary arteries and their association to adjoining structures. CT offers an interchange to CMR for the patients having trendsetter.

CMR is very significant and it plays an imperative role in judgment and takes notes of patients with treated TOF. CMR in association with angiography plays an imperative task in a choice of the patients for such type of processes, but also has CT, which permits the hallucination of calcium and the obvious description of coronary arteries relative to formerly positioned conduits. At the end, the evaluation of left and right heart extending to the branch pulmonary arteries and rising aorta of the treated patients of the TOF was observed and analyzed. Another study also demonstrated that CMR to echocardiography is more reliable imaging modality for the evaluation of pulmonary artery and RV function after competing treatment of TOF.

Another study illustrated that RV function decreases after heart therapy in CHD. This is because of three processes: severe ischemia or air emboli; pour of cytokines, and peri-operative warmth changing. There were also some detrimental sound effects of pericardial commotion on RV filling and functions were sensible. Additionally, it was also shown by the study that there was no connection between the declined right ventricular function and frequency of RVF. It was also observed in the study that CDH patients have refuse in RVF after the heart therapy, while the side of surgery was not well thought-out.

One study explained that prior to cardiac surgery, TOF patients don't have LV dysfunction and there is no further deterioration after the surgical treatment. On the other side, it was also analyzed that after the TOF therapy, RO volume increases and EF decreases. These changes observed after the surgery have been reported to the pulmonary shortage, pre-operative hypoxia and ventricular function. For the assessment of functions of ventricles, two processes were chosen which were CMR and radionuclide. These processes are however costly and their effects are for a longer duration.

Other studies illustrated that Doppler tissue imaging is useful for assessment of right and left ventricular function subsequent to surgery. For instance, TOF, as it is cheap and its effects are for short time.

CONCLUSION:

According to the echocardiographic results it has been observed that the impaired functions of both RV and LV might be the same in patients undergoing surgical treatment of TOF. This was due to dyskinesia of outpouring scrap, RV fibrosis, declined RV diastolic function and LV dysfunction.

REFERENCES:

1. Bernstein D. Congenital Heart Disease. Nelson Textbook of Pediatrics. 18th ed. Philadelphia: Elsevier Saunders; 2011, pp 1551-602.
2. Abd El Rahman MY, Abdul - Khaliq H, Vogel M. Value of the new Doppler - Derived myocardial performance Index for the Evaluation of Right and left ventricular function following Repair of tetralogy of Fallot. *Pediatr Cardiol.*2002;23:502-7.
3. Levant E, Gök? The end, Ozyürek AR, Darcan S, Coker M. Usefulness of the myocardial performance index (MPI) for assessing Ventricular function in obese pediatric patients. *Turk J Pediatr.*2005;47:34-8.
4. Abd El Rahman MY, Abul Khalig H, Vogel M, Alexi-Meskishvilib V, Gutberletc M, Lange PE. The relation between right ventricular enlargements. QRS duration and right ventricular Function in patients with tetralogy of Fallot and pulmonary regurgitation after surgical repair. *Heart.* 2000; 84:416-42.
5. Schuurin MJ, Bolmers PP, Mulder BJ, Rianne AC, de Bruin-Bon, Koolbergen DR, et al. Right ventricular function declines after cardiac surgery in adult patients with congenital heart disease. *J Cardiovascular Image* 2012; 28:755-62.
6. Kaylan B, Evik A, Tavli? V. The relationship between ventricular function assessed by tissue Doppler imaging and exercise capacity in patients after repair of tetralogy of Fallot: an observational study. *AnadoluKardiyolDerg.*2012; 12:490-7.
7. Kjaergaard J, Iversen KK, Vejlstrup NG, Smith J, Bonhoeffer P, Søndergaard L, et al. Effects of Chronic Severe Pulmonary Regurgitation and Percutaneous Valve Repair on Right Ventricular Geometry and Contractility Assessed by Tissue Doppler Echocardiography. *Echocardiography.* 2010; 27:854-63.
8. Kjaergaard J, Iversen KK, Vejlstrup NG, Smith J, Bonhoeffer P, Søndergaard L, et al. Impacts of acute severe pulmonary regurgitation on right ventricular geometry and contractility assessed by tissue-Doppler echocardiography, *Eur J Echocardiography.*2010;11:19-26.
9. Scherptong RW, Mollema SA, Blom NA, Kroft LJ, de Roos A, Vliegen HW, et al. Right ventricular peak systolic longitudinal strain is a sensitive marker for right ventricular deterioration in adult patients with tetralogy of Fallot. *Int J Cardiovascular Image* 2009; 25:669-76.
11. Salehian O, Schwartzman M, Merchant N, Webb GD, Siu SC, Therrien J. Assessment of Systemic Right Ventricular Function in Patients with Transposition of the Great Arteries Using the Myocardial Performance Index Comparison with Cardiac Magnetic Resonance Imaging. *Circulation.* 2004; 110:3229-33.
12. Schwartzman M, Samman AM, Salehian O, Holm J, Provost Y, Webb GD, et al. Comparison of Echocardiographic and Cardiac Magnetic Resonance Imaging for Assessing Right Ventricular Function in Adults with Repaired Tetralogy of Fallot. *Am J Cardiol.* 2007; 99:1593-7.
13. Andrea AD, Caso P, Sarubbi B, Russo MG, Ascione L, Scherillo M, et al. Right ventricular myocardial dysfunction in adult patients late after repair of tetralogy of Fallot. *Int J Cardiol.*2004; 94:213-20.
14. Cheung EWY, Lam WWM, Cheung SCW, Cheung YF. Functional implications of the right ventricular myocardial performance index in patients after surgical repair of tetralogy of Fallot. *Heart Ves.*2008; 23:112-7.
15. Liang XC, Cheung EWY, Wong SJ, Cheung YF. Impact of Right Ventricular Volume Overload on Three-Dimensional Global Left Ventricular Mechanical Desynchrony after Surgical Repair of tetralogy of Fallot.*AmJCardiol.*2008; 102:1731-6.
16. Cannesson M, Jacques D, Pinsky MR, Gorcsan J. Effects of modulation of left ventricular contractile state and loading conditions on tissue Doppler myocardial performance index. *Am JPhysiolHeartCircPhysiol.*2006; 290:1952-9.
17. Noori NM, Mohammadi M, Keshavarz K, Alavi SM, Mahjoubifarad M Mirmesdagh Y. Comparison of Right and Left Side Heart Functions in Patients with Thalassaemia Major, Patients with Thalassaemia Intermedia, and Control Group.*JTehUnivHeartCtr.*2013;8:35-41.
18. Noori NM, Mehralizadeh S. Echocardiographic evaluation of systolic and diastolic heart functions in patients suffering from beta-thalassaemia major aged 5-10 years Research Center for Children and Adolescent Health. *Anadolu Kardiyol Derg.*2010; 10:150-53.
19. Vasko K, Harada K, Toyono M. Tei index Determined by tissue Doppler Imaging in a patient with pulmonary Regurgitation after Repair

- of Tetralogy of Fallot. *Pediatr Car J diol*.2004; 25:131-6.
20. Ocala B, Oguz D, Karademir S, Bergen D, Yüksek N, Ertem U, et al. Myocardial performance index Combining Systolic and diastolic Myocardial Performance in Doxorubicin Treated Patients and its Correlation to Conventional echo/Doppler indices. *Pediatr Cardiol*.2002; 23:522-7.
 21. Abd El Rahman MY, Hui W, Yigitbasi M, Dsebissowa F, Schubert S, Hetzer R, et al.
 22. Detection of Left Ventricular Asynchrony in Patients with Right Bundle Branch Block after Repair of Tetralogy of Fallot Using Tissue-Doppler Imaging-Derived Strain. *J Am Coll Cardiol*. 2005; 45:915-21.
 23. Tatani SB, Carvalho ACC, Andriolo A, Rabelo R, Campos O, Moises A. Echocardiographic Parameters and Brain Natriuretic Peptide in Patients after Surgical Repair of Tetralogy of Fallot. *Echocardiography*.2010; 27:442-7.
 24. Geva T, Sandweiss BM, Gauvreau K, Lock JE, Powell AJ. Factors associated with impaired clinical status in long-term survivors of tetralogy of Fallot repair evaluated by magnetic resonance imaging. *J Am Coll Cardiol*.2004; 43:1068-74.
 25. Geva T. Repaired tetralogy of Fallot: the roles of cardiovascular magnetic resonance in evaluating path physiology and for pulmonary valve replacement decision support. *J Cardiovascular MagnetResonance*.2011; 13:1-24.
 26. Kurotobi S, Taniguchi K, Sano T, Naito H, Matsushita, Kogaki S, et al. Determination of timing for reoperation inpatients after right ventricular outflow reconstruction. *Am J Cardiol*. 2005; 95:1344-50.
 27. Babu-Narayan SV, Kilner PJ, Li W, Moon JC, Goatskin O, Devours PA, et al. Ventricular fibrosis suggested by cardiovascular magnetic resonance in adults with repaired tetralogy of fallout and its relationship to adverse markers of clinical outcome. *Circulation*. 2006; 113:405-13.
 28. Van der Hulst AE, Westenberg JJ, Kroft LJ, Bax JJ, Blom NA, de Roos A, et al. Tetralogy of Fallot: 3D velocity-encoded MR imaging for evaluation of right ventricular valve flow and diastolic function in patients after correction. *Radiology*.2010; 256:724-34.
 29. Prakash A, Powell AJ, Geva T. Multimodality Noninvasive Imaging for Assessment of Congenital Heart Disease. *Cardiovascular Imaging*. 2010; 3:112-25.
 30. Kilner PJ, Geva T, Kemmerer H, Trindade PT, Schwitter J, Gary D. Webb. Recommendations for cardiovascular magnetic resonance in adults with congenital heart disease from the respective working groups of the European Society of Cardiology. *Eur Heart J*2010; 31:794-805.
 31. Norton KI, Tong C, Glass RB, Nielsen JC. Cardiac MR Imaging Assessment Following Tetralogy of Fallot Repair. *Radio Graphics*. 2006; 26:197-211.
 32. Noori NM, Keshavarz K, Shahriar M. Cardiac and pulmonary dysfunction in asymptomatic beta-thalassemia major. *Asian CardiovascThoracAnn*.2012;20:555-9.
 33. Siwik ES, Erenberg F, Zahka KG, Goldmuntz E. In: Allen HD, Clark EB, Gutgesell HP, editors. Moss and Adam's Heart Disease in Infants, Children and Adolescents. Philadelphia, USA: Lippincott Williams and Wilkins; 2008, pp880-902.