CODEN [USA]: IAJPBB ISSN: 2349-7750

INDO AMERICAN JOURNAL OF
PHARMACEUTICAL SCIENCES

http://doi.org/10.5281/zenodo.2590607

Available online at: http://www.iajps.com ***Research Article***

POST CHOLECYSTECTOMY HISTOPATHOLOGICAL PATTERN OF GALL BLADDER

[1]Dr Usman Ali, [2]Dr Muhammad Zubair

[1]Allied Hospital, Faisalabad.

Article Received: December 2018 **Accepted:** February 2019 **Published:** March 2019

Abstract:

Objective: *The main objective of this research work was to find out the pattern of histopathology of the specimens of gall bladder in the patients after surgical removal of gall bladder.*

Methodology: *This was a retrograde research work conducted in a hospital of private university & two others private hospitals which were non-teaching in the city of Hyderabad. This research work covered a period of complete three years from the start of June 2005 to the end of May 2008. The analysis of the reports of histopathology of all patients who were undergoing open cholecystectomy or laparoscopic cholecystectomy carried out. The inspection of the documents of these patients carried out with specific prominence on appearance, findings of ultrasound before operation, findings during surgery & results of histopathology.*

Results: *Two hundred and eighty-two samples of gall bladder were put under histopathology in the period of this study duration. Seventy-five were the males & two hundred and seven were the female participants. Chronic inflammation of the gall bladder was very dominant outcome of histopathology observed in more than sixty four percent patients. Cholecystitis was followed by the empyema in more than thirty three percent patients whereas gall bladder carcinoma was present in only 1.4% patients.*

Conclusion: *Chronic cholecystitis was the most common feature as discovered by histopathology.*

Key Words: *Empyema, carcinoma, inflammation, chronic, gall bladder, cholelithiasis, histopathology.*

Corresponding author:

Dr. Usman Ali,

Allied Hospital, Faisalabad.

QR code

Please cite this article in press Usman Ali et al., ***Post Cholecystectomy Histopathological Pattern Of Gall Bladder.,*** *Indo Am. J. P. Sci, 2019; 06(03).*

INTRODUCTION:

Histopathological examination gives the proper detection of the samples. The stone in the gall bladder is very common health issue which demands surgical interference [1]. Cholelithiasis creates alterations in the mucosa of gall bladder in the form of inflammation, cholesterics & hyperplasia. Simple surgical removal of the gall bladder is the treatment for all before malignant & benign gall bladder diseases. The cancer of gall bladder is not very common malignancy with generally poor diagnosis. Simple cholecystectomy is best if the cancer is inside the mucosa [2]. The carcinoma of the gall bladder is detected histopathological from 0.3 to 1.5% cholecystectomy samples [3]. In fifteen to thirty percent patients, there is no proof of malignancy before or at the time of operation & disease is detected after operation with the help of microscope. These patients are in the group of better diagnosis [4].

Examination of the samples that give no benefit to patient, doctor or histopatholgist would appear useless. There is no requirement of evaluation with microscope for some tissues and could be selectively examined if a macroscopic irregularity was available to save the time and resources of pathology department, cholecystectomy samples are among one of such tissues. In a large amount of the hospitals, the samples of cholecystectomy sent to the laboratories for histology despite the available macroscopic irregularity [5]. The main purpose of this research work was to find out the histopathological design of the samples of gall bladder in the patient who were undergoing the procedure of cholecystectomy.

METHODOLOGY:

This research work was a retrograde study conducted in three private hospitals located in the city of Hyderabad city. This research work covered a complete 3 years from the start of June 2005 to the end of May 2008. The analysis of the reports of histopathology of all patients who were undergoing open cholecystectomy or laparoscopic cholecystectomy carried out. The department of histopathology had an ideal method for the assessment of cholecystectomy samples & process of all the gall bladder performed in the same manner.

The inclusion standards included all the patients with open cholecystectomy or laparoscopic cholecystectomy in those three private hospitals during the period of this research, with complete medical history, evaluation with histopathology at the laboratory of Isra University. The exclusion standard included the no availability of examination of histopathology after cholecystectomy, examination of histopathology in other laboratory other than the laboratory of Isra University. Patients with no previous record were not the part of this research work. Method of retrograde research, insufficiency of clinical record was the some limitation of this research work. The scrutiny of the notes of these patients carried out with special stress on appearance, results of ultrasound before surgery, findings during surgery & results of histopathology carried out. SPSS software version sixteen was in use for the analysis of the collected information.

RESULTS:

Histopathological assessment of two hundred and eighty two samples of gall bladder carried out in the duration of this study period. Seventy five were the male and two hundred and seven were the female participants. The average age of the patients was forty five years with a range of seventeen to seventy five years. Out of total samples of gall bladder, chronic cholecystitis was present in one hundred and eighty three patients. Eighty nine samples found with the acute cholecystitis or empyema. Only 4 samples (1.4%) found with the benign polyps while only 2 samples had acute acalculous cholecystitis. Gall bladder adeno carcinoma was present in only 4 samples. Age of the patient and distribution of the gender of the patients with cholecystectomy is available in Table-1.

Table-I: Cholecystectomy Specimens (n=282) Age and Gender Distribution

Age (in yrs)	Male	Female	Total		No of cancers
			n	(%)	
15 to 30	10.0	29.0	39.0	13.80	-
31 to 40	30.0	60.0	90.0	31.90	-
41 to 50	25.0	65.0	90.0	31.90	1
51 to 60	9.0	49.0	58.0	20.70	3
61-onwards	1.0	4.0	5.0	1.70	-
Total	75.0	207.0	282.0	100.00	4

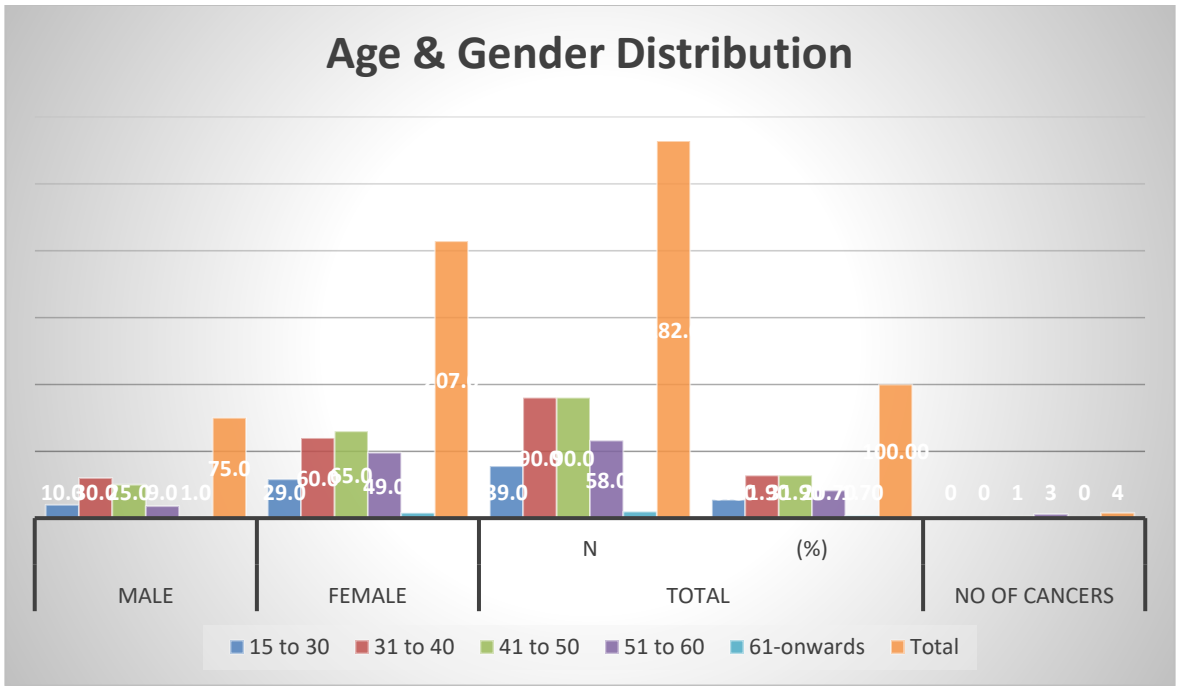

The elaborated analyses of results of histopathology of the samples of gall bladder are available in Table-2.

Table-II: Cholecystectomy specimen (n=282) Histopathology.

S. No	Findings	No of Specimen	
		n	%
1	Chronic cholecystitis	183.0	64.80
2	Acute calculous cholecystitis / Empyema	89.0	31.50
3	Adenocarcinoma	4.0	1.40
4	Gall bladder polyp	4.0	1.40
5	Acute acalculous cholecystitis	2.0	0.70

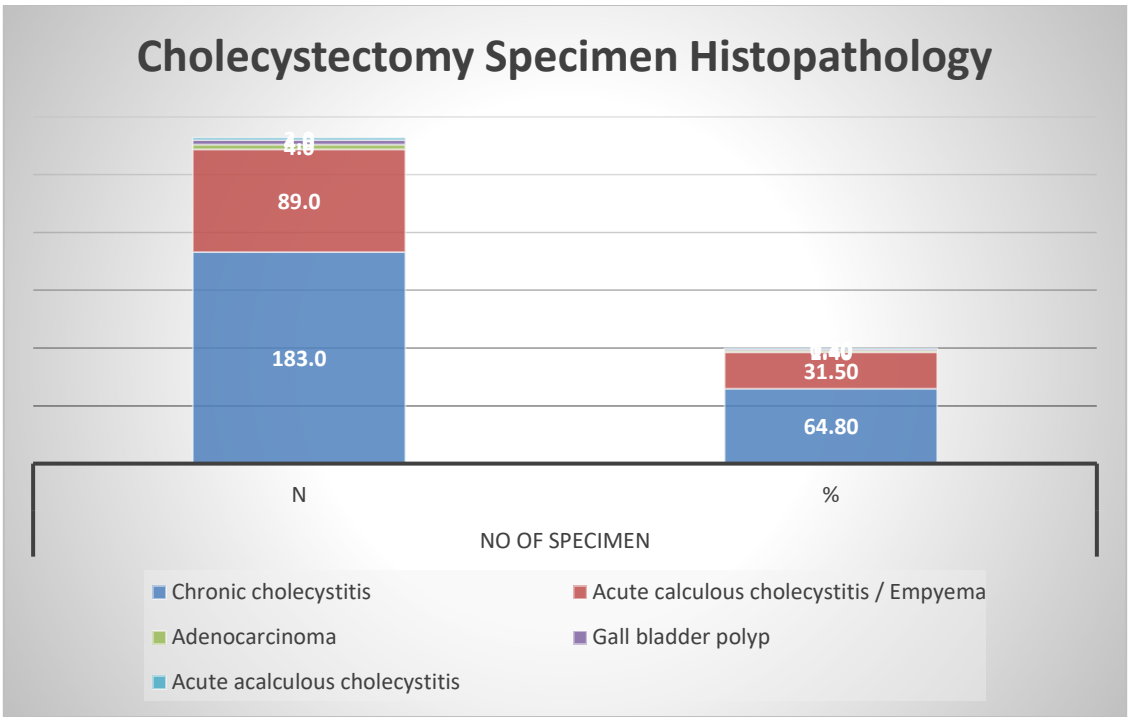

DISCUSSION:

Histopathology of samples is very important cornerstone in the care of patient. It is also very important in the detection of the tissues as well as medical decisions administrations. The rejections of the samples without proper assessment of the disease and proof would be profanity. It is universally acknowledged that the general histopathology of the samples of gall bladder is improbable to participate in the administration of the majority of patients [6] among cholelithiasis & cancer of gall bladder, but variable occurrence between various ethnic groups provides different features conscientious which includes the stone size, style of life, food, pollution in the environment, infections due to bacteria and parasites and different various hepatobiliary complications [7].

In spite of the modernism in the detection and operational methods, it is still among the late discoveries and poor prediction except when occasionally detected at initial stage after the cholecystectomy. Initial detection of the cancer of gall bladder at early stage is not very common because the carcinoma of the gall bladder has no symptoms in the initial stage. Sartaj [8] in a research work on seven hundred and fifty patients suffering with calculous cholecystitis as a main result of histopathology of about sixty eight percent followed by empyema in thirty percent patients & cancer of gall bladder in only 0.4% patients. This finding is very similar to the results of this case study [9]. The principle of examination through selective histology is neither new nor restricted to only gall bladder.

Various research works have evaluated the duration & price implication of regularly transfer all samples for histopathology [5, 10-12]. A complication at the time of surgery of gall bladder should increase the cancer suspicion. The availability of the uncommon results at operation like the mass of the gall bladder, momentum dense adhesions & gall bladder adjacent organs, gall bladder adherence to the ducts of bile & complicated gall bladder dissection from the bed of the liver would increase the carcinoma suspicion [13]. The rules of checking the mucosa at surgery time & presenting the gall bladder specimens for histopathology in respect to any suspicious outcome as polyps and ulcers, nodules & liver bed invasions should be accepted. The guideline of RCP (Royal College of Pathologists) have detected the samples of cholecystectomy as restricted or no medical worth in an effort to handle the high load of work of histopathologists, unsuitable utilization of their time & indecent utilization of the short [14].

CAP (College of American Pathologists) made the same suggestion the examination of the samples through selective histopathological rather than the routine examination [6]. Darmas in his research work stated that standard histopathological assessment of gall bladder is neither justifiable nor cheap & does not participate in the administration of the patients [10]. It was also concluded that choosing of a unique policy & checking problematic gall bladders only macroscopically confirmed to be equally responsive as there was not any missing of invasive carcinoma.

Untimely cancer of gall bladder not detected on macroscopic examination requires no operation again separately from cholecystectomy [15]. Omenn in his retrograde research work on histopathological outcomes found only one gall bladder cancer out of nine hundred and seventy six samples [16]. In opposition to this, a research work [17] concluded that greater than thirty percent patients could not be detected as malignancy of gall bladder in the before or during surgery phase & histopathological assessment of each sample was advocated. This issue requires exploration in the further research works.

CONCLUSION:

The pattern of histopathology of gall bladder after surgical removal of gall bladder was assessed as very different. The very leading discovery was chronic cholecystitis and empyema was following the cholecytitis but the gall bladder carcinoma was very uncommon.

REFERENCES:

1. Nathanson LK, Shaw IM. Gall Stones. In: Garden J, editor. Hepatobiliary and Pancreatic Surgery. 3rd ed. Netherlands. Elsevier Saunders; 2006: 167-192.
2. Lai CH, Lau WY. Gall bladder cancer - a comprehensive review. Surgeon 2008;6(2):101-110.
3. Weinstein D, Herbert M, Bendet N, Sanbank J. Incidental finding of gall bladder carcinoma. IMAJ 2002;4:334-336.
4. Contini S, DallaValle R, Zinicola R. Unexpectant gall bladder cancer after laparoscopic cholecystectomy. Surg Endosc 1999;13:264-267.
5. Dix FP, Bruce IA, Krypcyzk A, Ravi S. A selective approach to histopathology of the gall bladder is justifiable. Surgeon 2003;1(4):233-235.
6. Lohsiriwat V, Vongjirad A, Lohsiriwat D. Value of Histopathologic Examination of three common surgical specimens: Appendix, gall bladder and Hemorrhoid. World J Surg 2009;33:2189-2193.
7. Kumar JR, Tewari M, Rai A, Sinha R, Mohapatra SC, Shukla HS. An objective assessment of demography of gall bladder cancer. J Surg Oncol. 2006;93:610-614.
8. Sartaj F, Zarin M, Zia U, Muqeem R, Aurangzeb M, Waheed D, et al. Is routine histopathological examination of the gall bladder a futile exercise? Pak J Surg 2004;20:71-74.
9. Siddiqui GF, Soraya NS. An audit of cholecystectomy specimens. J Surg Pak 2002;7(2):18-21.
10. Darmas B, Mahmud S, Abbas A, Baker A. Is there any justification for the routine histopathological examination of straightforward cholecystectomy specimens? Ann R Coll Surg Engl 2007;89:238-241.
11. Bazoua G, Hamza N, Lazim T. Do we need histology for a normal-looking gall bladder? J Hepatobiliary Pancreat Surg 2007;14(6):564-568.
12. Khoo JJ, Nural AM. A clinicopathological study of nine cases of gall bladder carcinoma in 1122 cholecystectomies in Johar, Malaysia. Malays J Pathol 2008;30:21-26.
13. Shiwani MH. Surgical management of gall bladder carcinoma. J Pak Med Assoc 2007;57:87-90.
14. Matthyssens LE, Ziol M, Barrat C, Champault GG. Routine surgical pathology in general surgery. Br J Surg 2006;93:362-368.
15. Yildrim E, Celen O, Gulben K, Berberoglu U. The surgical management of incidental gall bladder carcinoma. Eur J Surg Oncol 2003;31:45-52.
16. Oommen CM, Prakash A, Cooper JC. Routine Histology of cholecystectomy specimens is unnecessary. Ann R Coll Surg Engl 2007;89:738. [Letter]
17. Samad A. Gall bladder carcinoma in patients undergoing cholecystectomy for cholelithiasis. J Pak Med Assoc 2005;55:497-499.