CODEN [USA]: IAJPBB ISSN: 2349-7750

INDO AMERICAN JOURNAL OF
PHARMACEUTICAL SCIENCES
http://doi.org/10.5281/zenodo.3733466

Available online at: http://www.iajps.com *Research Article*

ANALYSIS OF PATTERN AND MANAGEMENT OF CYSTS AND TUMORS AROUND IMPACTED TEETH

Dr Rabia Rafiq[1], Dr Atiqa Marium[1], Dr Nida Farooq[2]

[1]Resident Oral and Maxillofacial Surgery Armed Forces Institute of Dentistry, CMH Rawalpindi

[2]Demontmorency College of Dentistry, Lahore

Article Received: January 2020 **Accepted:** February 2020 **Published:** March 2020

Abstract:

Introduction: *The jawbones have a high prevalence of cysts in the human body due to the abundant amount of epithelial remnants.* ***Aims and objectives:*** *The basic aim of the study is to analyse the pattern and management of cysts and tumors around impacted teeth.* ***Material and methods:*** *This descriptive study was conducted in CMH Rawalpindi during March 2019 to December 2019. This study was done with the permission of ethical committee of hospital. Patients presenting with the complaint of pain, swelling, limited mouth opening, sensitivity, soft tissue swelling around the impacted/ unerupted teeth were examined and investigated. All the patients underwent clinical and radiographic assessment.* ***Results:*** *143 patients were symptomatic with complaints of pain and swelling due to cystic or neoplastic conditions. 2135 patients had symptoms such as swelling, pain, trismus or fever due to pericoronitis. The remaining 1998 patients were asymptomatic. The impacted molars and/or associated pathology in these patients were diagnosed during routine clinical and radiographic examination.* ***Conclusion:*** *It is concluded that impactions of molar, premolar and canines are commonly discovered dental anomaly that usually remains unnoticed by the patients unless some symptoms appear.*

Corresponding author:

Dr. Rabia Rafiq,

Resident Oral and Maxillofacial Surgery

Armed Forces Institute of Dentistry, CMH Rawalpindi

QR code

Please cite this article in press Rabia Rafiq et al., ***Analysis Of Pattern And Management Of Cysts And Tumors Around Impacted Teeth,*** *Indo Am. J. P. Sci, 2020; 07(03).*

INTRODUCTION:

The jawbones have a high prevalence of cysts in the human body due to the abundant number of epithelial remnants. Dental specialists, in this way, every now and again experience cystic injuries inside jawbones. Most jaw pimples are fixed with epithelium got from the odontogenic epithelium. These are alluded to as odontogenic blisters. They are subclassified into two gatherings, formative or provocative [1]. Dentigerous sores are the second most regular odontogenic sore and the most widely recognized formative odontogenic blister. A past efficient audit with respect to odntogenic pimples demonstrated that of 18,297 odontogenic growths, 9982 (54.6%) were instances of radicular sores, and 3772 (20.6%) were instances of dentigerous sores [2].

Dentigerous sores are normally asymptomatic and found accidentally as radiolucencies on all encompassing radiographs taken for general dental treatment or from investigations of the explanation behind postponed tooth ejection. The all-encompassing radiograph, in this manner, is the first sign of dentigerous growths in quite a while. It is significant for the dental specialist to comprehend the attributes of the dentigerous sore got from an all-encompassing radiograph [3]. This pimple is related with the crown of an affected, installed, or unerupted perpetual tooth. The most every now and again included tooth is a mandibular third molar.

Numerous foundational factors contribute in the impaction of teeth which incorporate cleidocranial dysplasia, endocrine lack, febrile malady, down disorder, gardner's disorder while neighborhood factors incorporate delayed deciduous teeth maintenance or early misfortune, malposed tooth germs, curve length insufficiency, supernumerary teeth, injury, odontogenic tumors and congenital fissure and sense of taste may impact impaction of lasting teeth [4].

Affected teeth may prompt basic difficulties like carious sores of the affected or contiguous tooth, periapical contamination, periodontal sickness and pathology like growth and tumor. Regular odontogenic sores and tumors incorporate dentigerous pimple, calcifying odontogenic growth, ameloblastoma, adenomatoid odontogenic tumor, odontogenic keratocyst, calcifying epithelial odontogenic tumor, and odontoma [5].

Aims and objectives

The basic aim of the study is to analyse the pattern and management of cysts and tumors around impacted teeth.

MATERIAL AND METHODS:

This descriptive study was conducted in CMH Rawalpindi during March 2019 to December 2019. This study was done with the permission of ethical committee of hospital. Patients giving the objection of torment, growing, restricted mouth opening, affectability, delicate tissue expanding around the affected/unerupted teeth were inspected and examined. All the patients experienced clinical and radiographic evaluation. Every all-encompassing radiograph were taken with the Dentsply Gendex Orthoralix 9200 (Dentsply Asia, Milford, US), and the amplification factor was 1.23. Every single revealed estimation were balanced by this factor. One gathering of scientists inspected the radiographs simultaneously on standard light boxes to decide the number and kinds of affected teeth, and the nearness of related pathologies. A tooth was characterized as affected when the tooth was blocked on its way of ejection by a nearby tooth, bone, or delicate tissue. A solid finding without pericoronal radiolucency was characterized by a uniform line without a break or a diffuse lucent region beneath the crown.

All data was collected and entered in SPS version 19 to analyze the data by using Chi Square test. The data was presented as proportions.

RESULTS:

143 patients were symptomatic with complaints of pain and swelling due to cystic or neoplastic conditions. 2135 patients had symptoms such as swelling, pain, trismus or fever due to pericoronitis. The remaining 1998 patients were asymptomatic. The impacted molars and/or associated pathology in these patients were diagnosed during routine clinical and radiographic examination. There were 134 cysts (2.24%) and 64 tumors (1.16%) found that were associated with 5486 impacted third molars, of which 3 were malignant (0.05%). 143 patients had symptoms such as swelling or pain due to cystic or neoplastic lesions. The remainder 54 patients had no symptoms suggestive of pathology, which included mainly the dentigerous cysts, keratocystic odontogenic tumor, hyperplastic dental follicles and odontoma. Of the 134 patients who had associated cysts with an impacted third molar, 45 (33%) were women and 89 (67%) men. Their ages ranged from 20 to 64 years with a mean of 31.8 years.

Table 01: Distribution of cysts according to gender and site.

Gender	Maxilla No. of patients	Mandible No. of patients	Total (%)
Male	8	37	45 (33%)
Female	20	69	89 (67%)
	28	106	134 (2.24%)

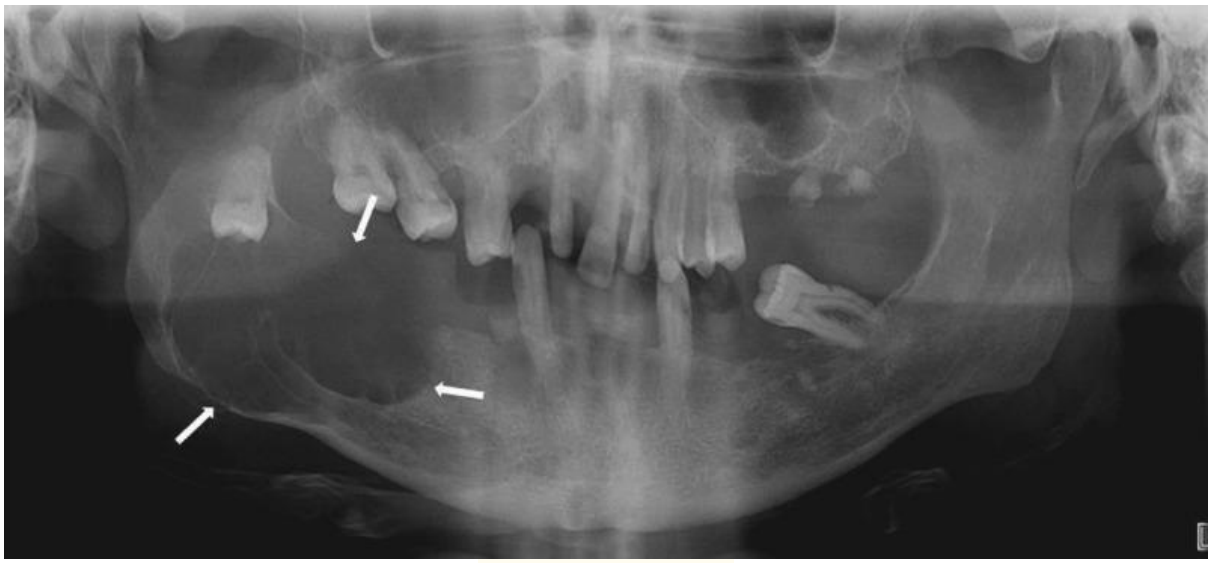

Impacted molar tooth.

Table 02: Distribution of tumors according to type.

Type	No. of patients	%
Ameloblastoma	31	48%
Keratocystic odontogenic tumor	16	25%
Hyperplastic dental follicle	5	8%
Odontogenic Fibroma	3	5%
Odontoma	6	10%
Squamous Cell Carcinoma	2	3%
Mucoepidermoid carcinoma	1	1%
Total	64	1.16%

DISCUSSION:

New evaluation approaches for the size of dentigerous cysts were introduced to reduce the individual differences in this study. In this new approach, the image distortion in panoramic radiograph was not considered. There, therefore, were some differences caused by the image distortion among each measurement although all digital panoramic radiographs were taken using the same apparatus under the same photographing condition [6]. A dentigerous cyst originates from the reduced enamel epithelium between the follicle and the tooth crown and develops after the crown of the tooth has been completely formed. We, therefore, thought that the size of a dentigerous cyst became larger with age at the outset. Actually, however, there was no significant correlation between the size and age [7]. In this relationship, the same result as ours was reported in two previous papers, even though their measurement methods differed with the one we used in this study. To the best of our knowledge, no report showed the significant correlation between the size of a dentigerous cyst and the age of the patient. Dentigerous cysts do not appear to develop gradually after the crown formation has finished, but arise at various periods randomly [8]. The size measured in this study is two-dimensional of the radiolucent area on a panoramic radiograph, and there is no information about buccolingual size. The relationship between three-dimensional or buccolingual size and age is uncertain. A dentigerous cyst is capable of achieving a significant size, occasionally with a painless expansion of cortical bone in the involved area, but a large size that causes pathologic fracture is rare [9]. This behavior of dentigerous cyst is different from ameloblastoma or odontogenic keratocysts.

Impacted teeth may remain asymptomatic for long period of time, and there is possibility that they become symptomatic due to various pathologies such as caries, pericoronitis, cysts, tumors, and root resorption [10]. There are various studies in literature supporting the evidence that number of complications including cysts and tumors are seen with impacted teeth22. In current study the most common pathology found with impacted teeth was dentigerous cyst 17 (44.7%). The cysts and tumors were more common in female than males (2:1) and in patients between 15 to 25 years of age and these findings are in agreement with findings of Patil et al.23 Enucleation of the these dentigerous cysts were carried out with preservation of lower border. Autogenous bone grafts and hydroxyapatite crystals

were used to fill up the dead space created after enucleation [11].

CONCLUSION:

It is concluded that impactions of molar, premolar and canines are commonly discovered dental anomaly that usually remains unnoticed by the patients unless some symptoms appear. The early recognition of pathological conditions associated with impaction/uneruption during or after growing age is very important for making early management.

REFERENCES:

1. Mercier P., Precious D. Risks and benefits of removal of impacted third molars. A critical review of the literature. Int J Oral Maxillofac Surg. 1992;21:17–27.
2. Polat H.B., Ozan F., Kara I., Ozdemir H., Ay S. Prevalence of commonly found pathoses associated with mandibular impacted third molars based on panoramic radiographs in Turkish population. Oral Surg Oral Med Oral Pathol Oral Radiol Endod. 2008;105:e41–47.
3. Mettes T.D., Ghaeminia H., Nienhuijs M.E., Perry J., van der Sanden W.J., Plasschaert A. Surgical removal versus retention for the management of asymptomatic impacted wisdom teeth. Cochrane Database Syst Rev. 2012;6:CD003879.
4. Lytle J.J. Etiology and indications for the management of impacted teeth. Northwest Dent. 1995;74:23–32.
5. Worrall S.F. An audit of general dental practitioners' referral practice following the distribution of third molar guidelines. Ann R Coll Surg Engl. 2001;83:61–64.
6. Van der Linden W., Cleaton-Jones P., Lownie M. Diseases and lesions associated with third molars. Review of 1001 cases. Oral Surg Oral Med Oral Pathol Oral Radiol Endod. 1995;79:142–145.
7. Adeyemo W.L. Do pathologies associated with impacted lower third molars justify prophylactic removal? A critical review of the literature. Oral Surg Oral Med Oral Pathol Oral Radiol Endod. 2006;102:448–452.
8. Hashemipour M.A., Tahmasbi-Arashlow M., Fahimi-Hanzaei F. Incidence of impacted mandibular and maxillary third molars: a radiographic study in a Southeast Iran population. Med Oral Patol Oral Cir Bucal. 2013;18:e140–e145.
9. Capelli J., Jr. Mandibular growth and third molar impaction in extraction cases. Angle Orthod. 1991;61:223–229.
10. Dachi S.F., Howell F.V. A survey of 3,874 routine full mouth radiographs. II: a study of impacted teeth. Oral Surg Oral Med Oral Pathol. 1961;14:1165–1169.
11. Shah R.M., Boyd M.A., Vakil J.F. Studies of permanent tooth anomalies in 7886 Canadian individuals, I. Impacted teeth. J Can Dent Assoc. 1978;44:262–265.