



CODEN [USA]: IAJPBB

ISSN: 2349-7750

**INDO AMERICAN JOURNAL OF
PHARMACEUTICAL SCIENCES**<http://doi.org/10.5281/zenodo.3055884>Available online at: <http://www.iajps.com>**Research Article****STUDY TO REVEAL THE EFFECTIVE WAY TO MANAGE
THE ABDOMINAL WALL DEHISCENCE**¹ Dr Unzillah Khan, ² Dr Bushra Zubair Butt, ³ Dr Humna Siraj¹ Rawalpindi Medical College, Rawalpindi² Frontier Medical and Dental College, Abbottabad³ MO at Bahria International Hospital, Rawalpindi**Article Received:** March 2019**Accepted:** April 2019**Published:** May 2019**Abstract:**

Objective: To investigate an effective way to separate the abdominal wound dehiscence following emergency and elective laparotomies.

Study Design: A comparative cross-sectional study.

Place and Duration: In the Surgical Unit II of Holy Family Hospital, Rawalpindi for one year duration from July 2017 to July 2018.

Materials and Methods: In the emergency or elective surgeries, 100 consecutive patients undergoing midline incision and laparotomy were included in the study. In order to see normal recovery, a wound examination was performed from the second postoperative day and the findings were recorded. Group A wound injuries were managed with full abdominal lavage and deep tension sutures and B group applied with Bogota bag application and abdominal wash.

Results: Fifteen (11.5%) of the 130 patients developed full wound dehiscence (trapped abdomen). The incidence of abdominal rupture was significantly higher after emergency laparotomies (14/94, 14.89%), whereas one patient underwent elective laparotomy (1/36, 2.7%). Group A (n = 8) was managed with deep tension sutures and group B (n = 7) was treated with Bogota Bag. The results of deep tension sutures were associated with less morbidity, less surgery and lower mortality.

Conclusion: Complete abdominal lavage with normal saline and closure with deep tension sutures is still an effective treatment in patients with complete wound dehiscence. Cases of abdominal closure due to a generalized intestinal edema or the need for further reoperation.

Key words: Midline laparotomy, Abdominal wound dehiscence, Bogota bag, deep tension suture, burst abdomen.

Corresponding author:**Unzillah Khan,**

Rawalpindi Medical College, Rawalpindi

QR code



Please cite this article in press Unzillah Khan *et al.*, **Study To Reveal The Effective Way To Manage The Abdominal Wall Dehiscence.**, *Indo Am. J. P. Sci*, 2019; 06(05).

INTRODUCTION:

Abdominal wound rupture (ruptured abdomen) is a serious postoperative complication experienced by surgeons who perform a significant amount of surgery. The incidence defined in the international literature ranged from 0.4% to 3.5%, and was associated with a mortality rate of up to 45%, while our local data showed a higher incidence of wounds with a general rate of 4.8% and 6.6%. Dehiscence of the abdominal wound may result in immediate excretion. Despite further information on wound healing, perioperative care and advances in suture materials, wound separation remains an important problem associated with prolonged hospital stay and patient morbidity associated with reoperation. This may be useful to increase rates of emergency laparotomy in high-risk patients with multiple comorbidities outweighing the benefits of technical success. The treatment of the wound disadvantage varies from a simple dressing to an additional surgery for abdominal lavage and then to the intensive care period after closure of the exploded abdomen. We compared two management strategies for abdominal rupture: a long-term deep-tensioned suture (DTS) used by many surgeons, and a Bogota bag often used for transient abdominal closure. In the post-injury or laparotomy stages due to the release of trauma or abdominal compartment syndrome.

MATERIALS AND METHODS:

This comparative cross-sectional study was held in the Surgical Unit II of Holy Family Hospital, Rawalpindi for one year duration from July 2017 to July 2018. A total of 130 consecutive cases exposed to laparotomy regardless of age and gender were included in the study with a midline incision. Patients under 12 years of age or who were operated for other incisions were excluded from the study. A detailed history and clinical examination were performed. The data were also recorded in a form (including diabetes mellitus, hypertension, chronic obstruction), including all major risk factors for wound opening such as age, sex, nature of the disease, emergency surgery, the patient's nutritional status, anemia, jaundice and accompanying presence. pulmonary disease, steroid use, immunodeficiency conditions, etc.). Initial and total protein examinations, albumin /

globulin ratio, abdominal radiographs and ultrasound were observed in all cases. Computed tomography of the abdomen was performed when necessary. After patient optimization and anesthesia clearance, all patients underwent laparotomy with midline incision. After surgery, abdominal wounds have been studied after the third day of the day for signs of decomposition of wound infection, including redness (erythema), seroma development, fluid secretion serohemorrhagic or pus, from one or more sites, and then partially or completely separation of the wound. It was conservative for partial dressing, washing and cultivation, and for daily dressing with antibiotics. The separation of the full wound (ruptured abdomen) was randomly divided into two groups; that is, group A and group B, which were administered by abdominal lavage suture and deep stretch sutures, were managed by meticulous abdominal lavage and application of the Bogota stock exchange. In Group A patients, the tension sutures of the skin were applied with a 2 cm suture and a 4 cm long plastic tube and 1.0 prolene from the edges of the wound to avoid cutting the skin. Intermittent matte cut stitches are also applied between the deep seams. In Group B, a Bogota bag made by a transparent bladder of a bladder and planted on all sides of the open wounds at least 3 cm away from the edges of the wound was applied. Patients in both groups received a broad-spectrum antibiotic and bandages sterilized by a doctor per day.

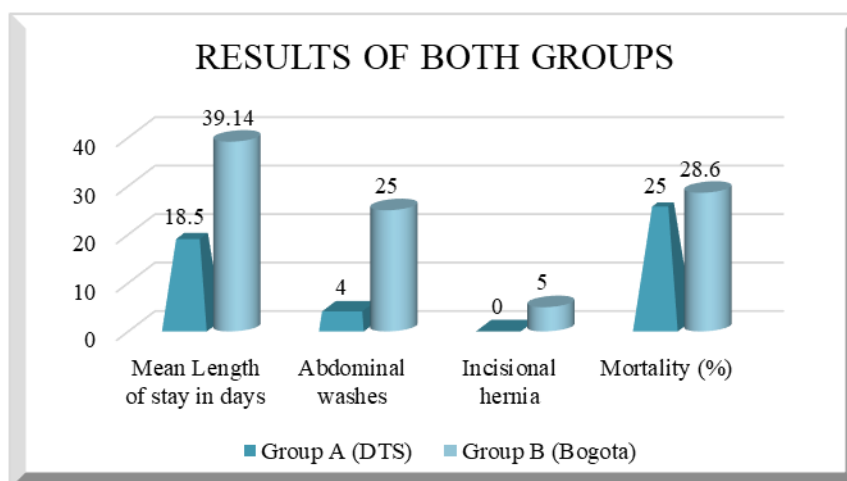
RESULTS:

A total of 130 patients underwent laparotomy with midline incision. The mean age of the patients was 34.22 (standard deviation: 14.9), 86 males (66.2%) and 44 females (33.8%). The male to female ratio was 2: 1. Emergency laparotomies were performed in 94 patients (72.3%) and elective laparotomy in 36 patients (27.7%). Although 15% of 130 patients underwent mid-laparotomy, overall laparotomies were seen with a much higher frequency (14%), and total wound healing (ruptured abdomen) developed. that is, 14.89%), 1 patient had gastric ingestion following elective laparotomy (1/36, 2.7%). Most cases were dirty, intestinal perforation and fecal peritonitis (11/15 or 73.3%). [Table 1].

Table No 01: Frequency of Burst Abdomen in Different Pathologies

<i>Diagnosis</i>	<i>Frequency</i>	<i>No of Burst Abdomen</i>
<i>TB Abdomen</i>	21	04
<i>Gunshot Abdomen</i>	19	0
<i>Obst due to post-op bands/adhesions</i>	17	0
<i>Typhoid Ileal Perforation</i>	16	03
<i>PerfDU</i>	10	02
<i>Colorectal Tumor</i>	06	02
<i>Perforated Appendix</i>	05	0
<i>Sigmoid Volvulus</i>	05	01
<i>Biliary Peritonitis</i>	05	01
<i>Gangrenous Bowel</i>	04	0
<i>Iatrogenic injuries during Obs procedures</i>	04	01
<i>Blunt Abdominal Trauma</i>	04	0
<i>Stab Wound</i>	04	01
<i>Pancreatitis</i>	03	0
<i>Others</i>	07	0
<i>Total</i>	130	15

Patients in Group A (n = 8) were treated with thin abdominal lavage and deep tension sutures, while group B patients (n = 7) were treated with abdominal lavage and Bogota bag.



The mean duration of B group (39.14 ± 12.95) was longer in patients with an average of 2 or more abdominal washes and later with incisional hernia development. The mean duration of stay in group A was $18.5 (\pm 5.3)$. Four patients died in a total mortality rate of 26.6%. One patient in group A (2/8, 25%) and 2 in the group B (2/7, ie 28.6%). [Table 2].

Table No 02: Comparison of Management Groups

<i>Groups</i>	Mean Length of stay in days	Abdominal washes	Incisional hernia	Mortality (%)
<i>Group A (DTS)</i>	18.5	04	0	25
<i>Group B (Bogota)</i>	39.14	25	5	28.6

DISCUSSION:

The presence of a ruptured abdomen can be considered when the intestines, omentum or other organs are seen through the abdominal wound. The eighth day after the operation occurs on the eighth day. Factors related to abdominal explosion include suture, closure technique, cough and postoperative vomiting, bloating, obesity, malignancy, hypoproteinemia, anemia, immunosuppressed states and contaminated surgeries. In our study, the frequency of abdominal bursts was 11.5%, this rate was higher than other local data, which showed a frequency ranging from 5.3% to 8.3%. The higher frequency of burst abdomen contradicts the many western studies shown. Our study (briefly DTS) has shown that deep tension stitching is a simple and effective one, to cope with the problems of abdominal form which is associated with less morbidity and mortality. The average length of stay was observed in the group Bogota in the DTS group and the subsequent development of the cut hernia was a problem, the bag was significantly higher in Bogotá (3914) Patients increased the frequency of reexplorations and new surgeries. Mortality in group B was similar to group A (25%) and also in another study Krishtein was similar to others in 28.6%. It showed a 24% mortality rate associated with the Bogota stock exchange. Our study (briefly DTS) has shown that deep tension stitching is a simple and effective one, to cope with the problems of abdominal form which is associated with less morbidity and mortality. The average length of stay was observed in the group Bogota in the DTS group and the subsequent development of the cut hernia was a problem, the bag was significantly higher in Bogotá (3914) Patients increased the frequency of reexplorations and new surgeries. Mortality in group B was similar to group A (25%) and also in another study Krishtein was similar to others in 28.6%. It showed a 24% mortality rate associated with the Bogota bag exchange.

CONCLUSION:

Deep tension suture is an effective way of managing ruptured abdominal and is associated with lower morbidity. Treatment for both deaths is comparable

to the patient's condition and more.

REFERENCES:

- Jensen, Kristian Kiim, Jannie Dressler, Niklas Nygaard Baastrup, Henrik Kehlet, and Lars Nannestad Jørgensen. "Enhanced recovery after abdominal wall reconstruction reduces length of postoperative stay: An observational cohort study." *Surgery* (2018).
- Zucker, B. E., C. Simillis, P. Tekkis, and C. Kontovounisios. "Suture choice to reduce occurrence of surgical site infection, hernia, wound dehiscence and sinus/fistula: a network meta-analysis." *The Annals of The Royal College of Surgeons of England* 0 (2018): 1-12.
- Arai, Masatoku, Shiei Kim, and Hiroyuki Yokota. "Staged Strategy for Early Abdominal Wall Closure in a Case Involving Ruptured Abdominal Aortic Aneurysm Requiring Open Abdomen in Which Primary Fascial Closure was Difficult to Achieve: A Case Report." *Chirurgia (Bucharest, Romania: 1990)* 113, no. 4 (2018): 558-563.
- Fraga, Maria V., Pablo Laje, William H. Peranteau, Holly L. Hedrick, Nahla Khalek, Juliana S. Gebb, Julie S. Moldenhauer, Mark P. Johnson, Alan W. Flake, and N. Scott Adzick. "The influence of gestational age, mode of delivery and abdominal wall closure method on the surgical outcome of neonates with uncomplicated gastroschisis." *Pediatric surgery international* 34, no. 4 (2018): 415-419.
- Giordano SA, Garvey PB, Baumann DP, Liu J, Butler CE. Hospital readmission following open, single-stage, elective abdominal wall reconstructions using acellular dermal matrix affects long-term hernia recurrence rate. *The American Journal of Surgery*. 2018 Feb 5.
- Baciarello, Marco, Greta Migliavacca, Maurizio Marchesini, Adriana Valente, Massimo Allegri, and Guido Fanelli. "Transversus abdominis plane block for the diagnosis and treatment of chronic abdominal wall pain following surgery: a case series." *Pain Practice* 18, no. 1 (2018): 109-117.
- López-Cano, M., García-Alamino, J.M., Antoniou, S.A., Bennet, D., Dietz, U.A., Ferreira, F., Fortelny, R.H., Hernandez-

- Granados, P., Miserez, M., Montgomery, A. and Morales-Conde, S., 2018. EHS clinical guidelines on the management of the abdominal wall in the context of the open or burst abdomen. *Hernia*, pp.1-19.
8. Guillaume, O., Perez-Tanoira, R., Fortelny, R., Redl, H., Moriarty, T.F., Richards, R.G., Eglin, D. and Puchner, A.P., 2018. Infections associated with mesh repairs of abdominal wall hernias: Are antimicrobial biomaterials the longed-for solution?. *Biomaterials*, 167, pp.15-31.
 9. Reina Rodriguez, Fernando S., Conor T. Buckley, Joshua Milgram, and Barbara M. Kirby. "Biomechanical properties of feline ventral abdominal wall and celiotomy closure techniques." *Veterinary Surgery* 47, no. 2 (2018): 193-203.
 10. Khansa, Ibrahim, and Jeffrey E. Janis. "Complex Open Abdominal Wall Reconstruction: Management of the Skin and Subcutaneous Tissue." *Plastic and reconstructive surgery* 142, no. 3S (2018): 125S-132S.
 11. Giron, Amilcar, Marcos Mello, Ricardo Haidar, Marcos Machado, Gabriel Anjos, Bruno Cezarino, Lorena Oliveira, Roberto Lopes, and Francisco Dénes. "V09-02 ABDOMINOPLASTY WITHOUT OSTEOTOMIES USING GROIN FLAPS TO CLOSE THE ABDOMINAL WALL DEFECT IN THE MANAGEMENT OF EXSTROPHY-EPISPADIAS COMPLEX." *The Journal of Urology* 199, no. 4 (2018): e903.
 12. García-Ureña, Miguel Ángel, Javier López-Monclús, Diego Cuccurullo, Luis Alberto Blázquez Hernando, Providencia García-Pastor, Stefano Reggio, Elena Jiménez Cubedo, Carlos San Miguel Méndez, Arturo Cruz Cidoncha, and Alvaro Robin Valle de Lersundi. "Abdominal wall reconstruction utilizing the combination of absorbable and permanent mesh in a retromuscular position: a multicenter prospective study." *World journal of surgery* (2018): 1-10.
 13. García-Ureña, Miguel Ángel, Javier López-Monclús, Diego Cuccurullo, Luis Alberto Blázquez Hernando, Providencia García-Pastor, Stefano Reggio, Elena Jiménez Cubedo, Carlos San Miguel Méndez, Arturo Cruz Cidoncha, and Alvaro Robin Valle de Lersundi. "Abdominal wall reconstruction utilizing the combination of absorbable and permanent mesh in a retromuscular position: a multicenter prospective study." *World journal of surgery* (2018): 1-10.
 14. Wang, Chun-meng, Ruming Zhang, Peng Luo, Zhiqiang Wu, Biqiang Zheng, Yong Chen, and Yingqiang Shi. "Reconstruction of extensive thoracic wall defect using the external oblique myocutaneous flap: An analysis on 20 Chinese patients with locally advanced soft tissue sarcoma." *Journal of surgical oncology* 117, no. 2 (2018): 130-136.
 15. Köckerling, F., Alam, N.N., Antoniou, S.A., Daniels, I.R., Famiglietti, F., Fortelny, R.H., Heiss, M.M., Kallinowski, F., Kyle-Leinhase, I., Mayer, F. and Miserez, M., 2018. What is the evidence for the use of biologic or biosynthetic meshes in abdominal wall reconstruction?. *Hernia*, pp.1-21.