



CODEN [USA]: IAJPB

ISSN: 2349-7750

INDO AMERICAN JOURNAL OF
PHARMACEUTICAL SCIENCES

<http://doi.org/10.5281/zenodo.3069483>

Available online at: <http://www.iajps.com>

Research Article

**OUTCOME OF EXCISIONAL CERVICAL LYMPH NODE
BIOPSY**

¹Muhammad Rauf Muzzammal, ²Javairya Ambreen, ³Usama Khan

Article Received: March 2019

Accepted: April 2019

Published: May 2019

Abstract:

Objective: To determine the frequencies of various outcomes on excisional lymph node biopsy in cases presenting with cervical lymph adenopathy.

Material and Methods; It was a descriptive, cross sectional multi centre study, conducted at Children Hospital Multan, Nishtar Hospital Multan and Rahim Yar Khan during the period of July to December 2018 in which 60 cases of cervical lymph node enlargement were enrolled. The cases of both genders falling in the age group of 12 to 70 years were included. The detailed socio demographic data and clinical history i.e. duration of lymph node enlargement was taken. Then these nodes were examined for their number, size, consistency and the data was recorded. These cases then underwent surgical excision at the surgical department of the same institute. The outcomes were assessed at the Pathology department of the same institute as well and the various outcomes were noted.

Results: In this study there were total 60 cases out of which 33 (55%) were males and 27 (45%) females with mean age of 34.22 ± 11.21 years. Out of 60 cases, 18 (30%) had firm to hard consistency and 42 (70%) had soft or rubbery consistency. On LN biopsy, TB was seen in 38 (63.33%) cases, metastatic malignancy in 14 (23.33%) cases, non-specific inflammation in 6 (10%) cases, and lymphoma in 2 (3.33%) cases. There was no significant difference in terms of age and gender in biopsy outcomes. However, the TB was seen significantly high in cases with soft consistency and malignancy in those with firm to hard one affecting 36 out of 42 and 12 out of 18 cases respectively with $p = 0.01$.

Conclusion; Tuberculosis is the commonest presentation of cervical lymphadenopathy in our territory and soft and rubbery consistency is significantly associated with this.

Key words: Cervical lymphadenopathy, TB, Malignancy.

Corresponding author:

Muhammad Rauf Muzzammal

QR code



Please cite this article in press Muhammad Rauf Muzzammal et al., *Outcome Of Excisional Cervical Lymph Node Biopsy.*, Indo Am. J. P. Sci, 2019; 06(05).

INTRODUCTION:

Lymph nodes are the reservoir of lymphocytes and their enlargement always reveal an underlying abnormality. Their presence not only adds to the anxiety in the patients, but also can be symptomatic by compressing the nearby organs and structures. Lymph node enlargement especially cervical lymph nodes enlargement is commonly seen and cases are being presented in the medical, surgical and pulmonology out as well as in patient department. [1]

There is a long list of benign and malignant conditions leading to its enlargement. It can be simple post viral or bacterial infection and hence needing a short term management or it can be tuberculous which is even acceptable as it need chemotherapy for only 6 months. On the other hand it is also a sign of various primary or metastatic malignancies like lymphoma, leukemia, carcinoma (CA) lung, breast and various other organs. [2-3]

There is always a need to reach a definitive diagnosis to accurately treat and eradicate the disease for which a detailed history and then due relevant investigations are often required. The final diagnosis is made by the direct examination of the tissues, which is obtained by surgical excision. There are certain parameters like consistency, number and size number of the lymph nodes that have some predilection towards certain diseases. [4-5]

Tuberculosis is one of the most common causes of cervical lymphadenopathy, especially in developing countries like Pakistan and often has matted lymph nodes. Recurrent infections can also lead to reactive lymph adenopathy that are usually discrete and soft. On the other had malignancies in the form of lymphoma has multiple lymph nodes or metastatic diseases show hard nature of these nodes. But nothing is specific to any disease and to reach a definite diagnosis, tissue biopsy is almost always required.³⁻⁴ Fine needle aspiration cytology (FNAC) and excisional biopsy are good invasive tools but sometimes smaller pieces of FNAC can't reveal a good diagnosis and excision biopsy is preferred.[6-7]

Objective:

To determine the frequencies of various outcomes on excisional lymph node biopsy in cases presenting with cervical lymph adenopathy.

MATERIALS AND METHODS:

It was a descriptive, cross sectional multi centre study, conducted at Children Hospital Multan, Nishtar Hospital Multan and Rahim Yar Khan during the period of July to December 2018, in which 60

cases of cervical lymph node enlargement were enrolled. The cases of both genders falling in the age group of 12 to 70 years were included. The detailed socio demographic data and clinical history i.e. duration of lymph node enlargement was taken. Then these nodes were examined for their number, size, consistency and the data was recorded. These cases then underwent surgical excision at the surgical department of the same institute. The outcomes were assessed at the Pathology department of the same institute as well and the various outcomes were noted. Data was analyzed with the help of SPSS version 22.0. Post stratification Chi-Square test was applied taking P-value ≤ 0.05 as significant.

RESULTS:

In this study there were total 60 cases out of which 33 (55%) were males and 27 (45%) females with mean age of 34.22 ± 11.21 years. Out of 60 cases, 18 (30%) had firm to hard consistency and 42 (70%) had soft or rubbery consistency. On LN biopsy, TB was seen in 38 (63.33%) cases, metastatic malignancy in 14 (23.33%) cases, non-specific inflammation in 6 (10%) cases, and lymphoma in 2 (3.33%) cases (figure 1). There was no significant difference in terms of age and gender in biopsy outcomes as in table 1 & 2. However, the TB was seen significantly high in cases with soft or rubbery consistency and malignancy in those with firm to hard one affecting 36 out of 42 and 12 out of 18 cases respectively with $p = 0.01$ as in table 3.

DISCUSSION:

Lymph nodes are predictor of underlying disease and almost always are never normal. These present with different clues in terms of clinical presentation and particular characteristics, towards specific diseases. Excisional biopsy is sometimes necessary to get better and detailed information to reach definitive diagnosis and to plan further for targeted management to decrease the morbidity in such patients.

In the present study, on lymph node biopsy, TB was seen in 38 (63.33%) cases, metastatic malignancy in 14 (23.33%) cases, non-specific inflammation in 6 (10%) cases, and lymphoma in 2 (3.33%) cases. This was similar to a study done by Ismail M et al revealed that out of their cases with excisional cervical lymph node biopsies TB was in 74.5%, reactive lymphadenopathy in 11.1%, metastatic malignancy in 6.7% and lymphoma in 4.4% of cases. [8]

While in another study from Iran by Zahir ST et al revealed reactive lymphadenopathy in most cases

affecting 62.5%, while malignancy in 21.6% cases.⁹ In another study by Alam J et al, Tuberculous lymphadenopathy was seen in 68.8% cases, reactive adenopathy in 11.7%, metastatic malignancy in 9.8% and lymphoma in 8.4% cases.¹⁰ Moreover in a study by Saifullah MK et al revealed TB lymph nodes in 39.3% cases and malignancy in 26.4% cases. [11]

TB was seen significantly high in cases with soft or

rubbery consistency and malignancy in those with firm to hard one affecting 36 out of 42 and 12 out of 18 cases respectively with $p= 0.01$. This was also observed by the studies in the past that have revealed that the cases that had soft and rubbery consistency and were also matted in nature were mostly found tuberculous in nature as compared to the firm ones.¹²⁻¹³ However, they did not find this difference as statistically significant.

FIGURE 01: OUTCOME OF EXCISIONAL BIOPSY n= 60

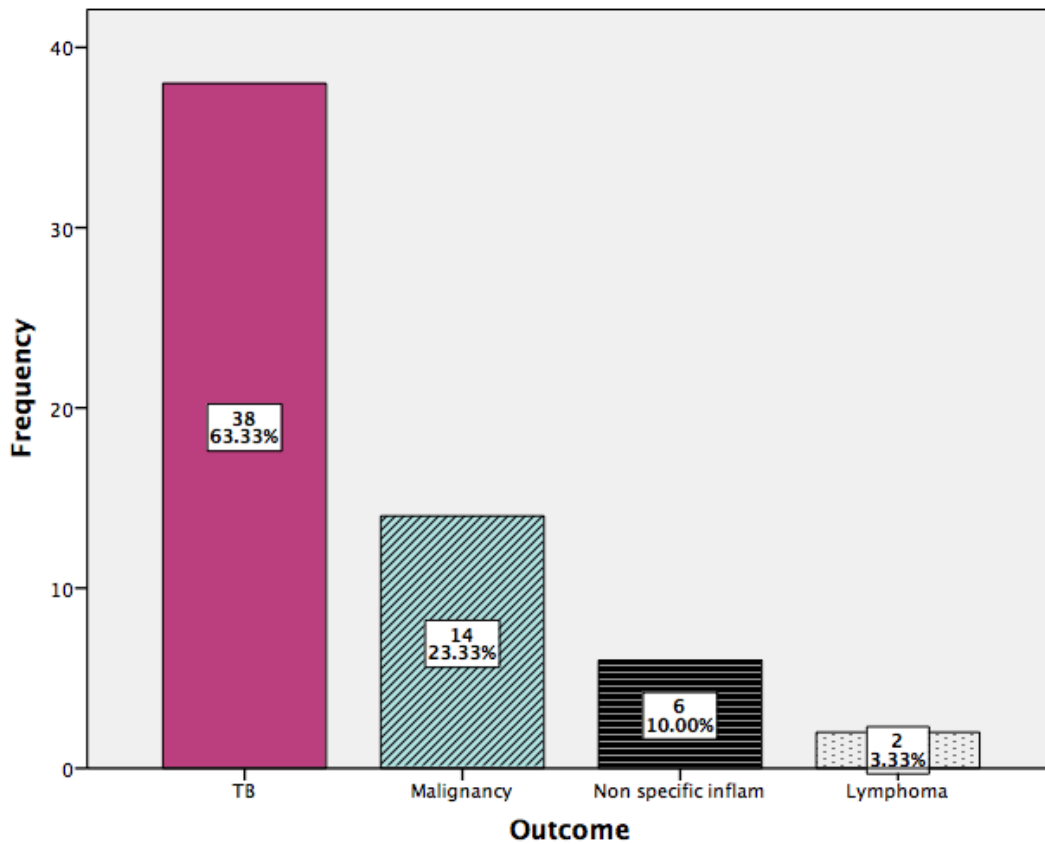


TABLE 01: OUTCOME WITH RESPECT TO GENDER n= 60

| Outcome | GENDER | | Total |
|---------------------------|-----------------|-----------------|------------------|
| | Male | Female | |
| TB | 22 (57.89%) | 16 (42.11%) | 38 |
| Malignancy | 6 (42.86%) | 8 (57.14%) | 14 |
| Non specific inflammation | 4 (66.67%) | 2 (33.33%) | 6 |
| Lymphoma | 1 (50%) | 1 (50%) | 2 |
| TOTAL | 33 (55%) | 27 (45%) | 60 (100%) |

$p= 0.68$

TABLE 02: OUTCOME WITH RESPECT TO AGE GROUPS n= 60

| Outcome | AGE GROUPS | | Total |
|---------------------------|--------------------|--------------------|------------------|
| | 12-40 | > 40 | |
| TB | 20 (52.63%) | 18 (47.37%) | 38 |
| Malignancy | 5 (35.71%) | 9 (64.29%) | 14 |
| Non specific inflammation | 3 (50%) | 3 (50%) | 6 |
| Lymphoma | 1 (50%) | 1 (50%) | 2 |
| TOTAL | 29 (48.33%) | 31 (51.67%) | 60 (100%) |

p= 0.27

TABLE 03: OUTCOME WITH RESPECT TO CONSISTENCY n= 60

| Outcome | CONSISTENCY | | Total |
|---------------------------|-----------------|-----------------|------------------|
| | Firm | Soft | |
| TB | 2 (5.26%) | 36 (94.74%) | 38 |
| Malignancy | 12 (85.71%) | 2 (14.29%) | 14 |
| Non specific inflammation | 2 (33.33%) | 4 (66.67%) | 6 |
| Lymphoma | 2 (100%) | 0 (0%) | 2 |
| TOTAL | 18 (30%) | 42 (70%) | 60 (100%) |

p= 0.01

REFERENCES:

- Habermann TM, Steensma DP. Lymphadenopathy. Mayo Clin Proc. 2000;75:723-32.
- Magsi PB, Jamro B, Sheikh AA, Sangi HA. An audit of 140 cases of cervical lymphadenopathy at tertiary care hospital. Gomal J Med Sci. 2013;11(1):47-49.
- Khan AU, Nawaz G, Khan AR. An audit of 75 cases of cervical lymphadenopathy. J Med Sci. 2011;19:95-97.
- Savage SA, Wotherspoon HA, Fitzsimons EJ, Mackenzie K. Cervical lymphadenopathy resulting in a diagnosis of lymphoma. Scott Med J. 2008;53:13-16.
- Malik GA, Rehan TM, Bhatti SZ, Riaz JM, Ha-meed S. Relative frequency of different diseases in patients with lymphadenopathy. Pak J Surg 2003;19:86-9.
- Maharjan M, Hirachan S, Kafle PK, Bista M, Shrestha S, Toran KC, et al. Incidence of tuberculosis in enlarged neck nodes, our experience. Kathmandu Univ Med J 2009;7:54-8.
- Shaikh SM, Baloch I, Bhatti Y, Shah AA, Shaikh GS, Deenari RA. An audit of 200 cases of cervical lymphadenopathy. Med Channel 2010;16:85-7.
- Ismail M, Muhammad M. Frequency of tuberculosis in cervical lymphadenopathy. J Postgrad Med Inst. 2013;27(3):342-46.
- Zahir ST, Azimi A. Histopathologic findings of lymph node biopsy cases in comparison with clinical features. Pak J Med Sci. 2009;25(5):728-33.
- Alam J, Nasir IUI, Iftikhar M, Khan SA, Aslam R, Alam M. Frequency of tuberculosis in cervical lymphadenopathy, our experience. Khyb J Med Sci. 2015;8(2):188-91.
- Saifullah MK, Sutradhar SR, Khan NA, Haque MF, Hasan I, Sumon SM, et al. Diagnostic evaluation of supraclavicular lymphadenopathy. Mymensingh Med J. 2013;22(1):8-14.
- Agarwal AK, Sethi A, Sethi D, Malhotra V, Singal S. Tubercular cervical adenitis: clinicopathologic analysis of 180 cases. Indian J Otolaryngol 2009;38:521-5.
- Tariq NA. Presentation of cervical lymphadenopathy to the surgeon. Pak J Surg 1993;9:120-3.