CODEN [USA]: IAJPBB ISSN: 2349-7750

INDO AMERICAN JOURNAL OF
PHARMACEUTICAL SCIENCES
http://doi.org/10.5281/zenodo.3091762

Available online at: http://www.iajps.com *Research Article*

ASSESSMENT OF DENTAL PULP CHANGES OBSERVED AFTER LONG TERM USE OF CORTICOSTEROID DRUGS

Dr Abdul Samad Tayyab[1], Dr Muhammad Jameel Khan[2], Dr Umme-i-Hani[3]
[1]THQ Hospital, Haveli Lakhan
[2]CMO at DHQ Hospital, Nowshera
[3]WMO at Indus hospital Manawa

Article Received: March 2019 **Accepted:** April 2019 **Published:** May 2019

Abstract:
Introduction: *It has been found that prolonged treatment with hormone leads to disorders affecting the electrolyte balance in the body, the dental literature contains a number of reports in which effects of cortisone on dental pulp have been studied.* ***Objectives of the study:*** *The main objective of this study is to assess the dental pulp changes observed after long term use of corticosteroid drugs.* ***Material and methods****: The cross sectional study was conducted in THQ Hospital, Haveli Lakhan during March 2018 to October 2018. The data was collected from 100 patients who can use corticosteroid drugs from the long time. The study groups were divided into two groups for the collection of data. One group was considered to be as the normal group and control group and the second one was the group of patients who received corticosteroid drugs during the treatment of dental pulp. The data was collected from both the groups for further analysis. Histopathology of these two groups were also done for further clarification.* ***Results****: The data was collected from 100 patients of both genders. Group I (no dexa-methasone) presented significantly higher values (p=0.01) than Group II (control) and Group III (dexa-methasone after cavity preparation), which means a significantly larger vascular area. Images from microscopic slides of specimens from Group II were closer in quality to those from Group III and presented a higher percentage of the area occupied by loose connective tissue.* ***Conclusion:*** *It is concluded that corticosteroids applied on the dentin proved to reduce the vascular phase of pulp inflammation regarding vessel diameter and number of blood vessels.*

Corresponding author:
Dr.Abdul Samad Tayyab,
THQ Hospital, Haveli Lakhan

QR code

Please cite this article in press Abdul Samad Tayyab et al., ***Assessment Of Dental Pulp Changes Observed After Long Term Use Of Corticosteroid Drugs .,*** *Indo Am. J. P. Sci, 2019; 06(05).*

INTRODUCTION

It has been found that prolonged treatment with hormone leads to disorders affecting the electrolyte balance in the body, the dental literature contains a number of reports in which effects of cortisone on dental pulp have been studied. Corticosteroids are the class of drugs which contain steroid hormones which is naturally produced in the adrenal cortex of animals and analogues of these hormones are also prepared in the laboratory [1]. They involved in a different processes like physiologic processes, stress and immune response, metabolism of carbohydrates and proteins and regulation of inflammation reaction. Corticosteroids are the drugs which are used for the treatment of stressful situation like surgery and dentistry [2].

In the pulp tissue, the first stage of potentially reversible inflammation is known as pulpal hyperemia, clinically characterized by provoked, temporary, localized, low-intensity pain. Given that this tissue is closely related to the dentin, forming the dentin-pulp complex, the pulp can be affected by aggressions to the dentin [3]. Moreover, due to the intimate relation between these tissues and the dentinal permeability, molecules of medications, such as corticosteroids, applied on the exposed dentin, diffuse through the dentinal tubules, with the potential to provide a therapeutic effect, alleviating the painful symptom [4].

The therapeutic effect of corticosteroids is based on their action on the synthesis of lipocortin and vasocortin, inhibiting the formation of edema and A_2 phospholipasis enzymes, respectively. By inhibiting this enzyme, membrane phospholipids cannot be converted into aracdonic acid. Therefore, the synthesis of prostaglandins and prostacyclins (the cyclooxygenase route) as well as the synthesis of leukotrienes (the lypooxygenase route) that should follow, are blocked [5].

Objectives of the study

The main objective of this study is to assess the dental pulp changes observed after long term use of corticosteroid drugs.

MATERIAL AND METHODS:

The cross sectional study was conducted in THQ Hospital, Haveli Lakhan during March 2018 to October 2018. The data was collected from 100 patients who can use corticosteroid drugs from the long time. The study groups were divided into two groups for the collection of data. One group was considered to be as the normal group and control group and the second one was the group of patients who received corticosteroid drugs during the treatment of dental pulp. The data was collected from both the groups for further analysis. Histopathology of these two groups were also done for further clarification.

Statistical analysis

Student's t-test was performed to evaluate the differences in roughness between groups. Two-way ANOVA was performed to study the contributions.

RESULTS:

The data was collected from 100 patients of both genders. Group I (no dexa-methasone) presented significantly higher values (p=0.01) than Group II (control) and Group III (dexa-methasone after cavity preparation), which means a significantly larger vascular area. Images from microscopic slides of specimens from Group II were closer in quality to those from Group III and presented a higher percentage of the area occupied by loose connective tissue.

Table 1: Total pulp area recorded in different groups

Group	n	Standard deviation	P
No medication	30	17.21	≤0.01
Control group	30	8.11	
Group containing corticosteroid drugs (dexa-methasone)	30	3.01	

Figure 1 shows histological images of the pulp tissue in Groups I and II. The only region that was positively immune stained was the dental pulp. The positively stained part was almost at the center of the dental pulp. In this region, darkly stained bead- like nerve fibers were observed. No nerve fiber terminals were visible.

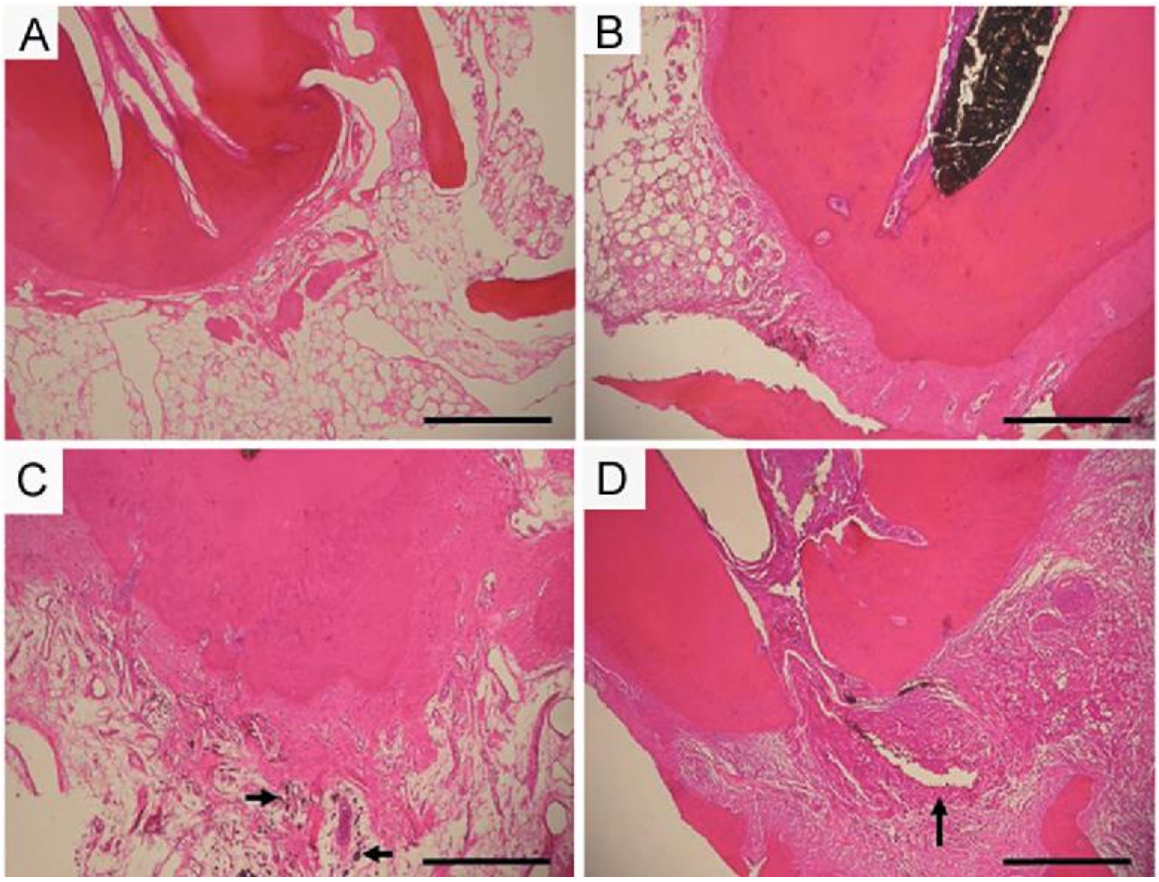

Figure 1: Histological images of the pulp tissue. A slide shows the normal group and control group. B and C shows the histological section of the group which was treated with different corticosteroid drugs (dexa-methasone).

DISCUSSION:

Tooth loss is influenced by many factors; however, mineral density of the mandible may also play a role in the stability of teeth in the alveolar socket. Hence, a decrease in the BMD may contribute to the resorption of tooth-supporting alveolar bone. The decreased BMD of the jaws may be particularly important as they are exposed to constant masticatory forces. Impaired bone density of the jaws may be a risk factor for tooth loss [6]. Klemetti *et al*. has stated that individuals with high skeletal BMD appear to retain their teeth with deep periodontal pockets, as opposed to those with low BMD. Komerik *et al*. has stated that patients with low BMD in various sites of the body skeleton had less teeth compared with the normal population. Corticosteroids are widely used in the treatment of diseases, disorders and conditions affecting the oral and maxillofacial area and the adjacent and associated structures [7]. The diseases of the oral and maxillofacial area might be either neighborhood or the appearance of a fundamental issue. Corticosteroids have their most extensive application in the administration of intense and unending conditions which have an unfavorably susceptible, immunologic, or fiery premise. In this way, a gathering of corticosteroids which have predominantly a glucocorticoid movement and practically no mineralocorticoid activity, for example, betamethasone, dexamethasone, triamcinolone, and prednisolone are utilized [8].

In spite of the fact that corticosteroids have incredible potential in the treatment of different diseases and conditions influencing oral and maxillofacial area, they likewise convey the danger of numerous side effects. Subsequently, benefits from corticosteroids ought to dependably be weighed against their potential risks [9]. Side effects of corticosteroids differ contingent upon the sort and measurement of the drug, defeat of organization, and length of treatment. Noteworthy unfriendly effects are well on the way to happen in patients utilizing oral corticosteroids for a drawn out stretch of time [10].

CONCLUSION:

It is concluded that corticosteroids applied on the dentin proved to reduce the vascular phase of pulp inflammation regarding vessel diameter and number of blood vessels.

REFERENCES

1. Grover VK, Babu R, Bedi SPS. (2007). Steroid Therapy – Current Indications in Practice.Indian Journal of Anaesthesia. 51 (5): 389-393.
2. Alexander RE, Throndson RR (2000). A review Of Perioperative Corticosteroid use In Dentoalveolar Surgery, Oral Surg Oral Med Oral Path. 90:406-15.
3. CAHEN, P.M., and FRANK, R.M.: Microscopie electronique de la pulpe dentaire humaine normale, Bull Group Int Rech Sci Stomatol 13: 421-443, 1970.
4. Accorinte ML, Loguercio AD, Reis A, Costa CA. Response of human pulps capped with different self-etch adhesive systems. Clin Oral Investig. 2008;12(2):119–127.
5. Büyükgüral B, Cehreli ZC. Effect of different adhesive protocols vs calcium hydroxide on primary tooth pulp with different remaining dentin thicknesses: 24-month results. Clin Oral Investig. 2008;12(1):91–96.
6. Ciarlone AE, Pashley DH. Medication of dental pulp: a review and proposals. Endod Dent Traumatol. 1992;8(1):1–5.
7. Cotran RS, Kumar V, Collins T. Robbins' pathologic bases of disease. Philadelphia: WB Saunders; 2004.
8. Fachin EVF, Zaki AE. Histology and lysosomal cytochemistry of the postsurgically inflamed dental pulp after topical application of steroids. I. Histological study. J Endod. 1991;17(9):457–460.
9. Fry AE, Watkins RF, Phatak NM. Topical use of corticosteroids for the relief of pain sensitivity of dentine and pulp. Oral Surg Oral Med Oral Pathol. 1960;13(5):594–597.
10. Hume WL, Massey WL. Keeping the pulp alive: the pharmacology and toxicology of agents applied to dentine. Aust Dent. 1990;35(1):32–37.