



CODEN [USA]: IAJPBB

ISSN: 2349-7750

**INDO AMERICAN JOURNAL OF  
PHARMACEUTICAL SCIENCES**

<http://doi.org/10.5281/zenodo.3843849>

Available online at: <http://www.iajps.com>

Research Article

## A COMPARATIVE STUDY TO DETERMINE THE EFFECTIVENESS OF MINERAL TRIOXIDE AGGREGATE AND BIODENTINE IN DIRECT PULP CAPPING

<sup>1</sup>Dr Shaista Ali Qamar, <sup>2</sup>Dr Noman Noor, <sup>3</sup>Dr Manzoor Ahmad, <sup>4</sup>Dr Nouman Anayat,  
<sup>5</sup>Dr Asif Nadeem, <sup>6</sup>Dr Farah Mushtaq

<sup>1</sup>TMO, Rawal institute of health sciences Islamabad

<sup>2</sup>BDS, FCPS, Associate professor operative dentistry, Rawal institute of health sciences, Islamabad

<sup>3</sup>Principal Rawal College of Dentistry, Islamabad

<sup>4</sup>BDS, FCPS (Operative Dentistry) Assistant Professor, Rawal Institute of Health Sciences, Islamabad

<sup>5</sup>Rawal Institute of health Sciences, Islamabad

<sup>6</sup>BDS, FCPS, Operative Dentistry, Rawal institute of health sciences, Islamabad

**Article Received:** March 2020

**Accepted:** April 2020

**Published:** May 2020

**Abstract:**

**Background:** In invasive dentistry, direct pulp capping (DPC) procedure with a reliable biomaterial may be considered as an alternative provided the pulp status is favorable. Mineral trioxide aggregate (MTA), a bioactive cement has excellent sealing ability and biocompatibility is capable of regenerating relatively damaged pulp and formation of dentin bridge when used as DPC agent. Biodentine is comparatively a new biomaterial, claimed to have properties comparable to MTA and is currently explored for vital pulp therapy procedures.

**Aim:** The aim of the study was to evaluate the effectiveness of MTA and biodentine as a direct pulp capping agent and clinical response of material on the bases of post-operative pain and development of periapical radiolucency after DPC with MTA and biodentine in carious teeth.

**Study Design:** A cross sectional study was conducted in the Department of Operative Dentistry, Rawal Institute of Dental Health Sciences Islamabad for six months from June 2019 to December, 2019.

**Material and Methods:** Twenty-four permanent molars with carious exposure having no signs and symptoms of irreversible pulpitis were selected and assigned to one of the two groups, Group I - MTA and Group II - biodentine. Patients were recalled at 3 weeks, 3 months, and 6 months for clinical evaluation. Fisher's exact test was used along with Chi-square test for statistical analysis.

**Results:** Over a period of 6 months, MTA and biodentine showed 91.7% and 83.3% success rate, respectively, based on the subject's symptoms, pulp sensibility tests, post-operative pain development of any periapical radiolucency.

**Conclusion:** MTA and biodentine may be used as DPC agents when the pulpal diagnosis is not more than reversible pulpitis.

**Keywords:** Biodentine, direct pulp capping, mineral trioxide aggregate.

**Corresponding author:**

**Dr Shaista Ali Qamar,**

TMO, Rawal institute of health sciences Islamabad

[Shaistaali123@gmail.com](mailto:Shaistaali123@gmail.com)

QR code



Please cite this article in press Shaista Ali Qamar et al, A Comparative Study To Determine The Effectiveness Of Mineral Trioxide Aggregate And Biodentine In Direct Pulp Capping., Indo Am. J. P. Sci, 2020; 07(05).

**INTRODUCTION:**

In deep carious lesions, inflammation is confined to superficial pulp, whereas tissue deep inside the pulp remains normal, except for some dilated blood vessels<sup>1</sup>. It has been testified that pulp healing can be achieved even after a carious exposure if the inflammation is no more severe than reversible pulpitis<sup>2</sup>. Endodontic therapy has been the traditional approach in managing pulpal exposure encountered during caries excavation as placement of medicaments against cariously exposed pulp was controversial<sup>3</sup>. The hesitancy to place a capping material on a carious exposure is due to incompetence in identifying a reliable non absorbable bioactive material with a predictable outcome.

Several materials have been experimented for capping vital pulp. MTA is a bioactive, biocompatible, antibacterial material with good stability, and excellent sealing ability<sup>4</sup>. However, its long setting time, poor handling properties, high material cost, and the discoloration potential remain a challenge to the practitioner. Slower setting and discoloration of dental tissues were also seen with white MTA (WMTA) that was introduced to overcome the discoloration potential of gray MTA. Nevertheless, MTA has been shown to be a reliable direct pulp capping (DPC) material on carious exposures in permanent teeth when two-visit treatment protocol was observed<sup>2</sup>.

Biodentine (Septodont, Saint Maur de Fosses, France) is a new calcium-silicate-based restorative cement, which can be used as a dentine substitute and has similar applications as MTA. It encourages the vital pulp cells and stimulates reparative dentin formation when in direct contact with pulp tissue. The consistency of Biodentine is similar to that of phosphate cement. The material can be directly applied in the cavity as bulk dentin substitute without preconditioning and has a shorter setting time<sup>6</sup>.

Both MTA and biodentine have demonstrated favorable results when used as DPC agents in mechanically exposed pulps; to our knowledge, there is limited clinical literature comparing biodentine and MTA as DPC agents in carious teeth<sup>7</sup>. Hence, the aim of the study was to evaluate the clinical response of pulp-dentin complex after DPC with MTA and biodentine in carious teeth.

**MATERIAL AND METHODS:**

A cross sectional study was conducted in the Department of Operative Dentistry, Rawal Institute of Dental Health Sciences Islamabad for six months from June 2019 to December, 2019. In this study, all patients in the age group of (20–40) years who were referred to the department for the management of deep dental caries in molars were selected. Teeth that were asymptomatic, responded positively to thermal and electrical tests with no tenderness on percussions and with no pathologic changes on periapical radiolucency were selected. Clinically, all teeth exhibited either primary or secondary deep caries. Radio graphically, all teeth showed deep dental caries approaching pulp with no evidence of thickened periodontal ligament, furcation radiolucency's, or per radicular pathosis. Patients were treated in accordance with Helsinki declaration. Informed consent was obtained after explaining the experimental rationale, clinical procedures, and possible complications of the procedure.

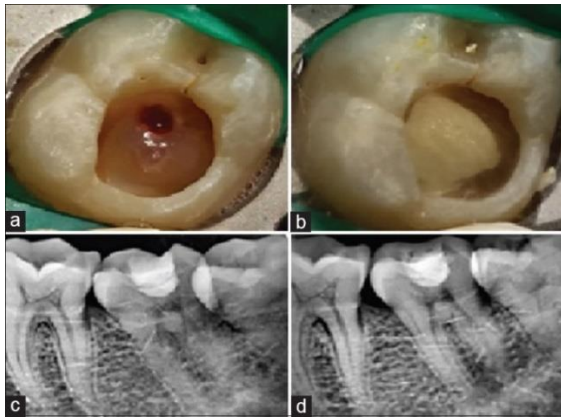
A standardized operative procedure was followed and performed by a single operator. Before cavity preparation, teeth were mechanically cleaned and disinfected with 0.2% chlorhexidine solution. After adequate anesthesia with 1:100,000 lignocaine hydrochloride with adrenaline (xylocaine) and rubber dam application, superficial caries and overhanging enamel were removed with sterile diamond points at high speed under air-distilled water spray coolant. Care was taken to excavate all the soft caries near the pulp with spoon excavators and round carbide burs on a slow speed hand piece. A sterile cotton pellet damped in 3% NaOCl was placed onto the pulp exposure sites to achieve hemostasis. Teeth which had no exposure and pulps which bled profusely were excluded from the study. In total, 24 teeth with pulp exposure which satisfied the inclusion criteria were selected.

Patients received either of the two treatment modalities using allocation concealment method.

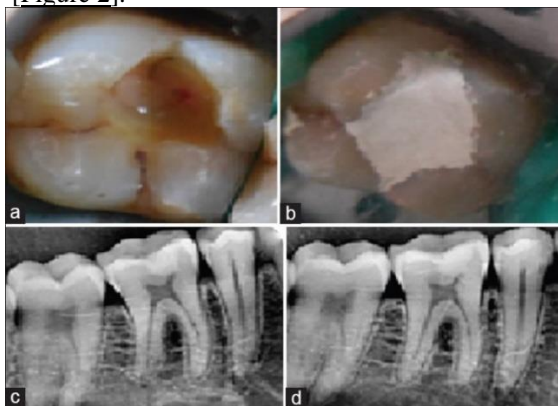
- Group I: MTA ( $n = 12$ )
- Group II: Biodentine ( $n = 12$ ).

In Group I, exposed pulp and surrounding dentin were capped with a 2 mm thick layer of Pro-Root WMTA, manipulated according to manufacturer's recommendations. After placing MTA, a wet cotton pellet was placed directly over the material and the tooth was provisionally restored with zinc poly-carboxylate cement

[Figure 1].



In Group II, pulps of teeth were capped with biodentine, manipulated according to manufacturer's recommendations and it was left as a temporary restoration [Figure 2].



Patients in both the groups were asked to return for clinical evaluation and placement of definitive composite restoration after 3 weeks. In Group I, cotton pellet was removed followed by resin-modified glass ionomer cement base and composite restoration was given. In Group II, biodentine was reduced to base followed by composite restoration. In Class II restorations, contact was established using palodont matrix system. Patients were recalled at 3 months and 6 months, for evaluation. Patients were asked about any postoperative sensitivity and pain throughout the study period.

#### Statistical analysis:

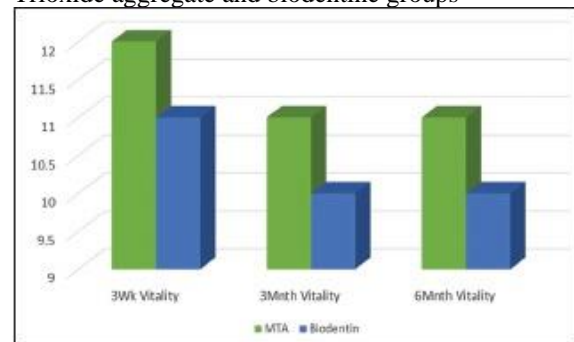
SPSS (version 20, SPSS Inc, Chicago) was used for analysis. Descriptive and analytical statistics were calculated. Pearson correlation coefficient was used. Fisher's exact test was used along with Chi-square test as the values in some of the cells were

$<5. P < 0.05$  was considered statistically significant.

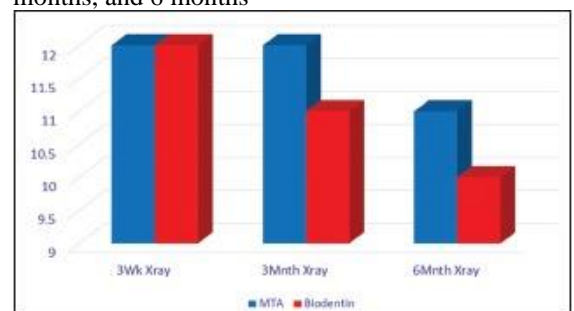
#### RESULTS:

Three patients (two with biodentine and one with MTA) complained of spontaneous pain, within 3 weeks and were root canal treated. Visual Analog Scale (VAS) was used for the measurement of pain intensity. The VAS is widely used to investigate many kinds of subjective experience, including pain.<sup>21, 22</sup> Other patients were asymptomatic during the experimental time period and were sensitive to cold and electric pulp test. At 6-month follow-up, none of the teeth developed periapical radiolucency on 2D periapical radiographs.

Graph 1  
Comparing pulp response to pulp sensibility tests at 3 weeks, 3 months, and 6 months between mineral Trioxide aggregate and biodentine groups



Graph 2  
Comparing radiographic response to mineral trioxide aggregate and biodentine at 3 weeks, 3 months, and 6 months



Out of 24 teeth, 14 teeth had occlusal caries and ten teeth had proximal caries. Among the three teeth that were root canal treated, one had occlusal caries and two with proximal caries. At 6 months follow-up, the overall pulp survival rate for MTA was (11 out of 12) 91.7% and for the biodentine it was (10 out of 12) 83.3%.

**Table 1:**

-	No of patient	No. of Pulp Survival	Root Canal Treated	Pulp Survival %
MTA	12	11	01	91.7%
Biodentine	12	10	02	83.3%
Total	24	21	03	87.5%

**DISCUSSION:**

Incomplete caries removal has shown a lower success rate of 56.2% for DPC with MTA on long-term basis<sup>7</sup>. The success of vital pulp therapy depends on the complete removal of disintegrated tissue, and controlling the infection is crucial for success of the procedure<sup>8</sup>. Hence, in the present study, care was taken to ensure complete excavation of caries.

The treatment was regarded as successful when none of the following signs or symptoms was present: Spontaneous pain, tenderness on percussion, swelling, fistulation, pathological mobility, furcation radiolucency, periodontal ligament space widening, or internal and external root resorption<sup>9</sup>. Moreover, two teeth from Group II and one tooth from Group I underwent root canal treatment as patients returned with persistent symptoms within the 3 months follow-up. Among the failed teeth, two teeth had proximal caries and one tooth had occlusal caries. Marques *et al.* in their study observed a lower success rate of DPC on axial wall<sup>10, 11</sup>. This they attributed to the lower marginal seal and subsequent micro leakage in proximal restorations<sup>12</sup>. The overall pulpal survival was established by subjective symptoms, cold test, and radiographs taken at recall appointment. MTA had a success rate of 91.7% which is comparable to the success rate of MTA at 97.96% seen in other study<sup>13</sup>. The success rate for biodentine in the present study was 83.3%.

MTA also stimulates the production of cytokines in human osteoblasts, allows good adherence of the cells to the material, thereby playing an active role in dentin-bridge formation<sup>14, 15</sup>. Capping of the pulpomized teeth with biodentine also produced a similar pulp response. Compared to MTA, it has a shorter setting time which is also an advantage<sup>16</sup>. Similarity of the tissue response with these materials may be due to their similar chemical composition (tricalcium silicate), the by-product released during setting reaction, and physical properties<sup>17, 18</sup>.

Bleeding from the exposed pulp for longer than 5 and up to 10 minutes is used as a threshold for reversible versus irreversible pulpitis classification. In our study, pulp capping agent was placed only after achieving complete hemostasis with 3% NaOCl. However, one case which took more than 5 min for hemostasis, returned with severe pain

within the next follow-up. MTA showed discoloration in majority of the cases. It has been shown that WMTA induced color change at 1 week time which increased over time, whereas biodentine did not affect the stability of tooth color<sup>19</sup>. The bismuth oxide component in WMTA, NaOCl used for hemostasis or curing light used for composite restoration may be responsible for this discoloration<sup>20</sup>.

The study was performed in carious pulp exposures that relied on the subjective symptoms, pulp sensibility test, and radiographic examination. Long-term clinical studies are required to substantiate the observations of the present study.

**CONCLUSION:**

From this study, it can be concluded that MTA and biodentine are suitable materials in pulp capping procedure. Careful case selection, isolation, complete caries excavation, pulp capping, and proper restoration will contribute to the success of the treatment and help maintain the vitality of the tooth.

**REFERENCES:**

1. Eskandarizadeh A, Shahpasandzadeh MH, Shahpasandzadeh M, Torabi M, Parirokh M. A comparative study on dental pulp response to calcium hydroxide, white and grey mineral trioxide aggregate as pulp capping agents. *J Conserv Dent.* 2011;14:351–5. [[PMC free article](#)] [[PubMed](#)] [[Google Scholar](#)]
2. Bogen G, Kim JS, Bakland LK. Direct pulp capping with mineral trioxide aggregate: An observational study. *J Am Dent Assoc.* 2008;139:305–15. [[PubMed](#)] [[Google Scholar](#)]
3. Al-Hiyasat AS, Barrieshi-Nusair KM, Al-Omari MA. The radiographic outcomes of direct pulp-capping procedures performed by dental students: A retrospective study. *J Am Dent Assoc.* 2006;137:1699–705. [[PubMed](#)] [[Google Scholar](#)]
4. Seltzer S, Bender IB, Ziontz M. The dynamics of pulp inflammation: Correlations between diagnostic data and actual histologic findings in the pulp. *Oral Surg Oral Med Oral Pathol.* 1963;16:969–77. [[PubMed](#)] [[Google Scholar](#)]
5. Mente J, Geletneky B, Ohle M, Koch MJ, Friedrich Ding PG, Wolff D, et al. Mineral trioxide aggregate or calcium hydroxide direct

- pulp capping: An analysis of the clinical treatment outcome. *J Endod.* 2010;36:806–13. [[PubMed](#)] [[Google Scholar](#)]
6. Nowicka A, Lipski M, Parafiniuk M, Sporniak-Tutak K, Lichota D, Kosierkiewicz A, et al. Response of human dental pulp capped with biodentine and mineral trioxide aggregate. *J Endod.* 2013;39:743–7. [[PubMed](#)] [[Google Scholar](#)]
  7. Schwendicke F, Meyer-Lueckel H, Dörfer C, Paris S. Failure of incompletely excavated teeth – A systematic review. *J Dent.* 2013;41:569–80. [[PubMed](#)] [[Google Scholar](#)]
  8. Kawashima N. Characterisation of dental pulp stem cells: A new horizon for tissue regeneration? *Arch Oral Biol.* 2012;57:1439–58. [[PubMed](#)] [[Google Scholar](#)]
  9. Woehrlen AE., Jr Evaluation of techniques and materials used in pulpal therapy based on a review of the literature: Part I. *J Am Dent Assoc.* 1977;95:1154–8. [[PubMed](#)] [[Google Scholar](#)]
  10. Stanley HR. Criteria for standardizing and increasing credibility of direct pulp capping studies. *Am J Dent.* 1998;11:S17–34. [[PubMed](#)] [[Google Scholar](#)]
  11. Schwendicke F, Stolpe M. Direct pulp capping after a carious exposure versus root canal treatment: A cost-effectiveness analysis. *J Endod.* 2014;40:1764–70. [[PubMed](#)] [[Google Scholar](#)]
  12. Marques MS, Wesselink PR, Shemesh H. Outcome of direct pulp capping with mineral trioxide aggregate: A prospective study. *J Endod.* 2015;41:1026–31. [[PubMed](#)] [[Google Scholar](#)]
  13. Torabinejad M, Pairokh M. Mineral trioxide aggregate: A comprehensive literature review – Part II: Leakage and biocompatibility investigations. *J Endod.* 2010;36:190–202. [[PubMed](#)] [[Google Scholar](#)]
  14. Koh ET, McDonald F, Pitt Ford TR, Torabinejad M. Cellular response to mineral trioxide aggregate. *J Endod.* 1998;24:543–7. [[PubMed](#)] [[Google Scholar](#)]
  15. Grech L, Mallia B, Camilleri J. Investigation of the physical properties of tricalcium silicate cement-based root-end filling materials. *Dent Mater.* 2013;29:e20–8. [[PubMed](#)] [[Google Scholar](#)]
  16. Vallés M, Roig M, Duran-Sindreu F, Martínez S, Mercadé M. Color stability of teeth restored with biodentine: A 6-month *in vitro* study. *J Endod.* 2015;41:1157–60. [[PubMed](#)] [[Google Scholar](#)]
  17. Camilleri J, Sorrentino F, Damidot D. Investigation of the hydration and bioactivity of radiopacified tricalcium silicate cement, biodentine and MTA angelus. *Dent Mater.* 2013;29:580–93. [[PubMed](#)] [[Google Scholar](#)]
  18. Zhou HM, Shen Y, Wang ZJ, Li L, Zheng YF, Häkkinen L, et al. *In vitro* cytotoxicity evaluation of a novel root repair material. *J Endod.* 2013;39:478–83. [[PubMed](#)] [[Google Scholar](#)]
  19. Vallés M, Mercadé M, Duran-Sindreu F, Bourdelande JL, Roig M. Color stability of white mineral trioxide aggregate. *Clin Oral Investig.* 2013;17:1155–9. [[PubMed](#)] [[Google Scholar](#)]
  20. Camilleri J. Color stability of white mineral trioxide aggregate in contact with hypochlorite solution. *J Endod.* 2014;40:436–40. [[PubMed](#)] [[Google Scholar](#)]
  21. Price, D.D., McGrath, P.A., Rafii, A., and Buckingham, B, **The validation of visual analogue scales as ratio scale measures for chronic and experimental pain.** *Pain.* 1983; 17: 45–56 [[PubMed](#)] [[Scopus \(2224\)](#)] [[Google Scholar](#)]
  22. McDowell, I. and Newell, C.A. **Guide to rating scales and questionnaires.** Oxford University Press, New York, Oxford; 1987 [[Google Scholar](#)]