



CODEN [USA]: IAJ PBB

ISSN: 2349-7750

**INDO AMERICAN JOURNAL OF  
PHARMACEUTICAL SCIENCES**<http://doi.org/10.5281/zenodo.1479201>Available online at: <http://www.iajps.com>

Research Article

**COMPARATIVE STUDY ON THE ROLE OF MRI IN SPINAL  
TUBERCULOSIS**<sup>1</sup>Dr. Mahpara Aslam, <sup>2</sup>Dr. Adeel Mehmood, <sup>3</sup>Dr. Munir Rehman<sup>1</sup>Lahore General Hospital, Lahore<sup>2</sup>THQ Hospital Nowshera Virkan<sup>3</sup>Khyber Teaching Hospital Peshawar KPK**Abstract:**

**Objective:** The aim of our research was to conduct the evaluation of the role of MRI in judging the magnitude of disease in TB-spine.

**Methodology:** The design of research was descriptive which we carried out at the Lahore General Hospital. The duration of the research was from July-2016 to Dec-2017, which included a total of 60 patients of tuberculosis further divided into two groups of 55% male (33) and 45% female (27). Their ages were ranging from fourteen to thirty-six years, while the mean was thirty-three years. We used a proforma, which was pre-designed in order to note down the patients' detailed data and clinical features. We included the TB-spine patients in this research; whereas, removed those from consideration who were having non-tuberculous spondylitis.

**Results:** Out of the total, 63% (38 cases) had backache symptoms. Sixteen cases (26.6%) had spinal cord compression, 45% had the symptoms of thoracolumbar spine, whereas rare diffuse involvement was there and those who were involved in more than one level were only 5% (three cases). Mode of primary imaging was plain radiography. MRI Scan was most useful while carrying-out the investigation. The reports gathered through MRI Scan showed the paraspinal abscess in 40% (24 cases), narrowed intervertebral disc space in 95% cases, complete destruction of body in 20% (12 cases), wedge collapse of body in 30% (18 cases), card compression in 26.6% (16 cases); whereas, calcification in 30% (18 cases).

**Conclusion:** The most important equipment for investigation of spinal tuberculosis in patients is MRI. It is also a useful surgical treatment guide as it provides the details of the disease including its extent. Monitoring of the feedback to the treatment also becomes very easy using MRI Scans.

**Keywords:** Spinal Tuberculosis, Pulmonary Disease, Spinal Artrythrombosis, Paraplegia, Intervertebral Disc.

**Corresponding author:**

**Dr. Mahpara Aslam,**  
Lahore General Hospital,  
Lahore

QR code



Please cite this article in press Mahpara Aslam et al., *Comparative Study on the Role of MRI in Spinal Tuberculosis*, Indo Am. J. P. Sci, 2018; 05(11).

**INTRODUCTION:**

TB is not only a widespread disease as of today but it also has been plaguing the mankind throughout the history since ancient times. Out of all infections out there, TB is responsible for the greatest number of mortality and morbidity in the areas having dense population, especially in the developing countries. In the third world countries, TB is the infection which is most common. Although it is common as a pulmonary disease but it is more common in children as an extra pulmonary disease. The infection of joints and bones is in about five to ten percent of the patients. About 50% patients suffer from spinal-TB (commonly known as Potts disease) who have joint and bone TB. The intestine or respiratory tract serve as the way for infection to reach the spine by blood stream. The infection spreads to the disc after beginning from vertebral body's frontal part, destroys bones and forms abscess. In eighty percent of the cases sensitivity and culture is positive. The spread of abscess starts from beneath the anterior longitudinal ligament; consequently, disc height loses due to involvement of intervertebral disc. Development of Kyphos (or sharp angulation) occurs as a result of collapse of vertebral bodies. Extension and escape of formation of cold abscess and caseation into the para-vertebral soft tissue or just penetration into the neighboring vertebra may happen.

Ischemia or displaced bone from spinal artery thrombosis, or the pressure from abscess pose great risk for the damage of cord, thus causes paraplegia, Potts. Around twenty to twenty-five percent of the cases might develop paraplegia. Non-traumatic paraplegia, in most of the world's countries, is commonly responsible to cause TB. The findings in a research by the WHO indicate that nearly one-third of the world's total population (around 2 billion) suffer from TB. Similarly, data from a WHO's research in 2006 shows that about six million people become TB's victim every year, whereas it is responsible for nearly 2 million deaths per year globally. The increase in the number of TB patients is correlated with the increase in the joint and bone TB. The most dangerous and common form of musculoskeletal-TB is Spinal-TB which remains a problem of great concern for the health departments of the developing countries. The primary mode of imaging for spinal-TB is plain x-rays, through which, every patient undergoes. The most preferred method to diagnose the disease early and determine the extent of the infection and its activity is MRI. MRI Scan shows soft tissue swelling and edema as well as involvement of bones. One may detect or exclude the abscess, whereas subperiosteal edema is visible

already. In order to access the treatment response, we can use serial MRI exams which are quite useful to manage the infections of multilevel,

The features of MRI Scans of tuberculous infection are paraspinal mass, soft tissue edema, vertebral collapse, destruction consequent of Kyphosis and disc space narrowing. The differentiation of pyogenic spondylitis and TB is difficult. Simple infection destroys discs at early stage whereas TB does the same in the later stages. Also, where there is calcification, there is TB. This research was conducted to appraise what part MRI plays in order to assess the magnitude of disease. The researchers also used serial MRI scans to evaluate the infection healing.

**METHODOLOGY:**

The design of research was descriptive which we carried out at the Lahore General Hospital. The duration of the research was from July-2016 to Dec-2017 which included a total of 60 patients of tuberculosis further divided into two groups of 55% male (33) and 45% female (27). Their ages were ranging from fourteen to thirty-six years, while the mean was thirty-three years. We used a pro forma which was pre-designed in order to note down the patients' detailed data and clinical features. We included the following tests in investigation; CBC, Sputum cytology, ESR and chest X-Ray of all patients in order to diagnose the pulmonary TB. We included the TB-spine patients in this research; whereas, removed those from consideration who were having non-tuberculous spondylitis. We also carried out the research in order to evaluate the various TB's radiological features in spine using MRI scans. We carried out plain film radiography of all the patients which is the primary mode of imagery. In addition to that we did not apply any Myelogramy, Bone scan or CT scan on any patient.

**RESULTS:**

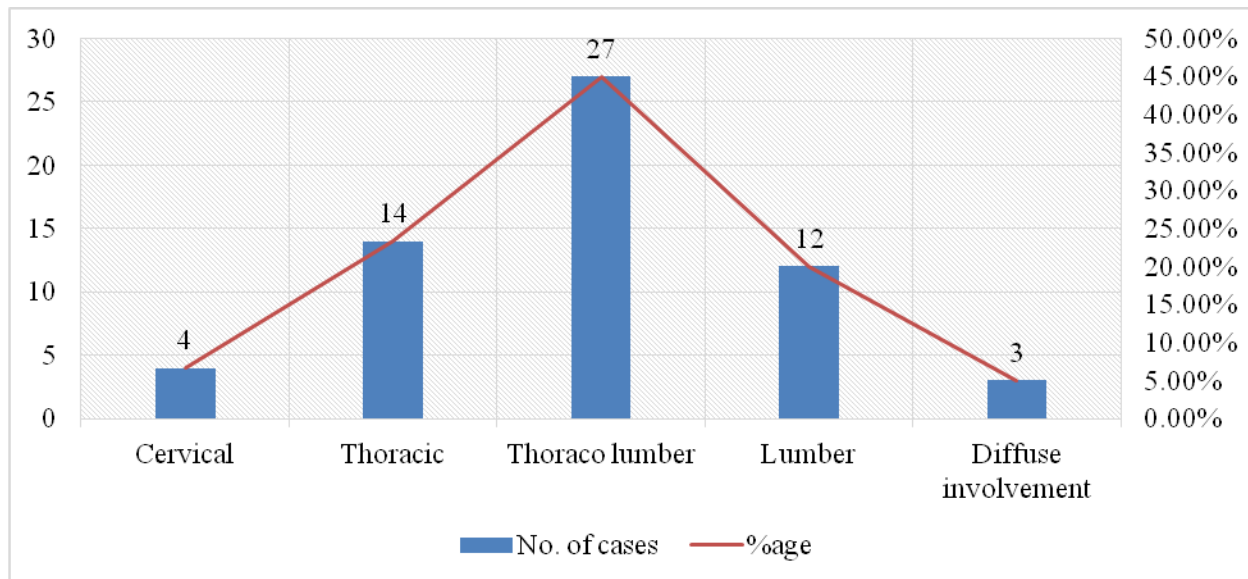
Our sample of research consisted of a total of sixty patients, amongst which 55% (33) were males and 45% (27) were females, whose ages ranged between fourteen and forty-six years respectively. Additionally, we found out the mean of their ages as thirty-three years. 23.3% (14) of the patients were having thoracic spine, 20% (12) were having lumbar spine, 6.6% (04) were having cervical spine TB; whereas, 5% (3) cases were diagnosed of diffuse involvement. The patients who had spinal cord compression were 16 in number. As diagnosed via MRI Scans, 95% of the patients having intervertebral disc space narrowing. We observed Low back pain and local tenderness as the most common symptoms.

The reports gathered through MRI Scan also showed the paraspinal abscess in 40% (24 cases), narrowed intervertebral disc space in 95% cases, complete destruction of body in 20% (12 cases), wedge

collapse of body in 30% (18 cases), cord compression in 26.6% (16 cases); whereas, calcification in 30% (18 cases). Table – I provides the information about the distribution of spinal tuberculosis (region-wise).

**Table:** Distribution of Spinal tuberculosis (region-wise), (60)

S. No.	Region	No. of cases	%age
1.	Cervical	4	6.6 %
2.	Thoracic	14	23.4 %
3.	Thoraco lumber	27	45 %
4.	Lumber	12	20 %
5.	Diffuse involvement	3	5 %



### DISCUSSION:

Spinal TB, till 1950s, was a common neurological and orthopedic problem. In the decades of 1960 & 70, this disease exhibited a persistent drop in developing countries due to progress in chemotherapy and optimization in the programs of public health. In contrary to developed countries, Spinal TB is most common disease in developing countries. This is due to poverty, unbalanced diet, poor conditions of hygiene, illiteracy, low health budget, pulmonary TB as a common disease and overcrowding. The depiction of dominance of male populace and the clinical pattern of onset in our research is just as what Jalleh RD observed in his studies. What Bikha Ram, Tulsi SM concluded in their reports about the vertebra's regional distribution was also evident from our findings. Most cases go through plain X-ray as this scan is vital for the diagnosis of spinal tuberculosis. For the early diagnosis of infection, MRI Scan is the most effective method. It exposes the bony involvement and

swelling of soft tissue. We also found MRI Scan to be very efficient in order to analyze and treat the spinal tuberculosis. A clinician can make out the following understandings from a spinal tuberculosis patient using MRI.

- Involvement site
- Kyphosis angle
- Paravertebral swelling of soft tissue
- Cord compression degree
- Bone disease extent – compression fracture / wedge collapse
- Vertebral canal's size
- How many vertebrata are involved

Even though MRI investigation is expensive as compared to CT scan and plain film radiography, it is much useful as it informs us more about the root compression or spinal cord degree and involvement of soft tissues. As it informs about the severity of disease, it is useful while treating the disease. The serial MRI scans become quite helpful in monitoring the feedback of the treatment. We can get good

results by carrying-out conservative method of treatment i.e. chemotherapy in case of early diagnosis. Anti-TB drugs can reach the cavities in spine and TB cases material. Surgery; however, becomes the only option after the diagnosis of severe involvement of bone along-with the cord or compression of root.

### CONCLUSION:

The most important equipment for investigation of spinal tuberculosis in patients is MRI. It is also a useful surgical treatment guide as it provides the details of the disease including its extent. Monitoring of the feedback to the treatment also becomes very easy using serial MRI Scans

### REFERENCES:

1. Naveed M. Tuberculosis of spine: Pattern of the disease in Pakistan. *Professional Med J* 2001;28(6): E 106-13.
2. Bennet JC, Bennet SJ. *Infection of Bone and Joint. Surgery international*, 2006;73, Elsevier Ltd. ISSN 09554572.
3. TB infection Apley's system of Orthopedic and fracture, 8th edition, Arnold, Oxford University Press Inc, New York 2001.
4. T Duck Worth, *Chronic infection, Lecture notes on Orthopedics and Fractures*, Blackwell scientific publication, Oxford 1984.
5. National Institute of Allergy and Infectious Diseases (NIAID). *Microbes in sickness and in health*. 2005. Retrieved on 3 October 2006. *J Pak Ortho Assoc* 2008;20(1):25.
6. Onyebujoh, Philip and Rook, Graham AW. *World Health Organization Disease Watch: Focus: Tuberculosis*. December 2004, Accessed 07 October 2006.
7. Watts HG, Lifese RM. Tuberculosis of Bones and Joints. *J Bone Joint Surg* 1996;78:288-98.
8. Farar S, Lowell AM, Meador MP. Extrapulmonary tuberculosis in the United States. *Am J Epidemiol* 1979;109:205.
9. Tulsi SM. Tuberculosis of the spine. In *Textbook of Tuberculosis*. New Dehli: Vikas publishing House Pvt Ltd. 1981;420-33.
10. Turgut M. Spinal tuberculosis (Pott's disease): its clinical presentation, surgical management, and outcome. A surgery study on 694 patients. *Neurosurg Rev* 2001;24(1):8-13.
11. Nasreen. Role of plain radiography in diagnosis of Koches spine *J Pak Ortho Assoc* 2008;20(1):25.
12. *Imaging in Orthopedics-Baily and love short practice of surgery* 25th edition. Arnold Press. UK. Year is Missing
13. Boxer DL, Pratt C, Hine AL, Radiological

- features during and following treatment of spinal tuberculo- sis. *Br J Radiol* 1992;65(774):476-9.
14. Jallah RD, Kuppusamy I, Mahayuddin AA. Spinal tu- berculosis: a five years review of cases at the National Tuberculosis Centre. *Med J Malaya* 1991;46(3):269-73.
15. Greenspan A, Montesano P. "Pyogenic and Non Pyo- genic Infections of the spine"; Time Condom, imag- ing if the spine in the practice, wolfe publishing, Mosby 1993;13.5-13.7.
16. Penter Renton, "Periosteal Reactions: Bone and Joint Infection; sarciod", David Sutton. *Textbook of Radi- ology and Imaging, Volume- II, 7th Edition*, Churchill Livingstone, 2003;1167.
17. Muckey T, Schutz T, Kirschner M. Psoas abscess: the spine as a primary source of infection. *Spine* 2003;28(6):E 106-13.
18. RamDevrjni B, Ghori RA, Momon N. Spinal Tubercu- losis at Liaquat University Hospital, Hyderabad/ Jamshoro. *JLUMHS* 2006;(1-4):33-9.
19. Tulsi SM. Treatment of neurological complications in tuberculosis of the spine. *J Bone Joint Surg* 1969;51- A:680-92.
20. TB infection Apley's system of Orthopedic and frac- ture, 8th edition, Arnold, Oxford University Press Inc, New York 2001.
21. Raut AA, Narlawar RS, Nagar A. An unusual case of CV junction tuberculosis presenting with quadriple- gia *Spine* 2003;28(15):E309.
22. Sinha S, Singh A, Gupta V. Surgical management and outcome of tuberculosis at lantoaxial dislocation: A 15 years experience. *Neurosurgery* 2003;52(2):331-8; discussion 338-9.
23. Vidyasager C, Murthy HK. Spinal tuberculosis with neurological deficit. *Natl Med J India* 1996;9(1):25-7.