



CODEN [USA]: IAJPBB

ISSN: 2349-7750

**INDO AMERICAN JOURNAL OF
PHARMACEUTICAL SCIENCES**<http://doi.org/10.5281/zenodo.3554435>Available online at: <http://www.iajps.com>

Research Article

**A CROSS-SECTIONAL STUDY TO DETERMINE THE
ACCURACY OF HIGH FREQUENCY USG AMONG PATIENTS
WITH MENISCAL INJURIES**¹Dr Irfan Qiam, ²Hooria Shafique, ²Muqadas Mushtaq¹DHQ Teaching Hospital Gujranwal²H.H. Sheikh Khalifa Bin Zayed Al Nayhan Hospital/ AK CMH Muzaffarabad (Azad Kashmir)**Abstract:**

Objective: The objective of the research was to determine the correctness of high-frequency ultrasonography in knee joint meniscal injuries in matured patients verified on magnetic resonance imaging.

Material and Method: This cross-sectional research was carried out at Mayo Hospital, Lahore from September 2018 to May 2019. The numbers of patients enrolled for research were one hundred with the supposition of meniscal injuries. The age of the enrolled patients was between fifteen to fifty years and comprising of both the genders. A researcher not included those patients in his research who have open wound over the knee, cases with former meniscal tears follow up and those patients having disease mimicking meniscal wounds. Researcher compares the ultrasonography results with the results of MRI which was carried out and explained by radiologist.

Results: Among one hundred enrolled patients for research, ultrasound displayed meniscal injuries in seventy-five percent cases. Magnetic resonance imaging verified meniscal injuries in seventy-seven percent of patients. However, twenty-three percent displayed no meniscal injuries. In ultrasonography positive cases, the percentage of true positive and false positive cases was 72% & 3% respectively. Moreover, in twenty-five ultrasonography negative cases, five percent (false negative) has meniscal injuries verified through magnetic resonance imaging whereas twenty percent true negative had nil meniscal injury on magnetic resonance imaging. Therefore, negative and positive predictive value, specificity, diagnostic correctness, sensitivity in detecting meniscal injuries via ultrasonography was 80%, 96%, 86.96%, 92% and 93.50% respectively.

Conclusion: This research determines that high-resolution ultrasonography emerges as safe, trustable, precise, available with ease as well as cost-effective procedure utilized for the assessment of meniscal injuries in the zone of low resources, however, MRI is costly and reachable to few ones.

Keywords: Magnetic resonance imaging (MRI), meniscal tears, high resolutions ultrasounds (HRUS).

Corresponding author:**Dr. Irfan Qiam,**

DHQ Teaching Hospital Gujranwal

QR code



Please cite this article in press Irfan Qiam et al., A Cross-Sectional Study To Determine The Accuracy Of High Frequency Usg Among Patients With Meniscal Injuries., Indo Am. J. P. Sci, 2019; 06(11).

INTRODUCTION:

The significant most joint of the human body is the knee. Degenerative, as well as traumatic, are the two main forms of meniscal injuries. CT scan, Magnetic resonance imaging, or arthroscopy ultrasonography are the instruments used for the assessment and verification of meniscal injuries [1]. For the assessment of musculoskeletal injuries, ultrasound is most suitable, low cost and accurate procedure which might be utilized as an initial commendatory diagnostic procedure. While assessing cartilage damages, ultrasonography is much sensitive as compared to radiography [2]. HRUS is appearing as feasible imaging procedure in detection as well as evaluation of the musculoskeletal system. HRUS has multiple benefits such as access with ease and multiplanar potentiality along with financial assistance. Unlike MRI, ultrasonography presents the fibrillar microanatomy of tendons, muscles as well as ligaments amplifying its detection potentiality, the capability of compression, powerful gauging structure and correlate comfortably with the central lateral edge is beneficial [3, 4]. The dominance of high-resolution ultrasounds includes nil exposition to radiations, less price, soft tissues, direct visualization and freely assessable dynamic research [5].

MRI is the most effective, precise as well as noninvasive procedure for detecting meniscal tear. It is the benchmark imaging procedure and much accurate as compare to physical examination. HRUS has affected clinical procedure as well as patient's attention cases by abolition of unimportant detective arthroscopies or by determining another diagnosis which might mimic meniscal tears [6, 7]. Magnetic resonance imaging has excellent accuracy as well as specificity in detection of meniscal tears; however, it is a high cast detection test so still unavailable at many clinics. Therefore, population tendencies towards minimum cast formed HRUS as a captivating alternative to much costly imaging procedure such as MRI [8]. Moreover, in patients having a contrary symptom to magnetic resonance imaging just like cerebral clips, non-titanium, metallic prosthesis, or orbital metallic foreign bodies, cardiac pacemaker, HRUS could be very good imaging procedure. HRUS is also applied with ease on bulky patients who might not be checked via magnetic resonance imaging.

So, sustaining in mind entire above data of this research is performed to determine detection correctness of HRUS in diagnostician of meniscal tears. Therefore, the patient could be treated with less expensive, simple and promptly accessible substitute to magnetic resonance imaging.

METHOD AND MATERIAL:

This cross-sectional research was carried out at Mayo Hospital, Lahore from September 2018 to May 2019. The numbers of patients enrolled for research were one hundred with the supposition of meniscal injuries. The age of the enrolled patients was between fifteen to fifty years and comprising of both the genders. Patients having an indication of the meniscal tear with entire of subsequent symptoms enduring from one to eight weeks knee ache, short knee movement, and softness when pressed on the meniscus. A researcher not included those patients in his research who have open wound over the knee, cases with former meniscal tears follow up and those patients having disease mimicking meniscal wounds. Researcher compares the ultrasonography results with the results of MRI which was carried out and explained by radiologist. Approval was taken from the ethical review board. One hundred cases that were hospitalized in the orthopedic department referred by a specialist to the department of radiology with the objective of magnetic resonance imaging scan meet the required criteria were registered for research. Sonographic utilization of probe of higher frequency under the guidance of radiological expert earlier to experience on a magnetic resonance imaging test. Ultrasound assessment was conducted on general electric logic P-5 ultrasonography machine which utilized a probe of 10 MHz frequency. Then MRI of the damaged knee was conducted in each patient on 1.5 T Phillips complete body magnetic resonance system by utilizing standard imaging coil. Each magnetic resonance imaging was examined by a radiologist consultant. Composed facts were reviewed via SPSS software and SD as well as mean was measured for numerical facts. Regularity and percentage were measured for categorical facts.

RESULTS:

The age limit in the current research was from fifteen to fifty years with 30 ± 2.65 years of average age. Huge numbers of patients (46%) were in between twenty-five to thirty-five years of age. The numbers of male and female patients among one-hundred entire patients were seventy-six and twenty-four respectively with 3.17:1 ratio. Multiple of the patients (62%) were displayed with indirect injuries whereas (38%) with direct knee injuries. The symptoms interval in patients ranged from one to eight weeks with 02 ± 1.65 average days. Entire patients were going through HRUS of the damaged knee. Ultrasonography assisted meniscal injuries detected in seventy-five (75%) cases. Magnetic resonance imaging verified meniscal injuries in seventy-seven (77%) patients; however, twenty-three (23%) patients

displayed nil meniscal damage. In ultrasonography positive cases, the percentage of true positive and false positive cases was 72% & 3% respectively. Moreover, in twenty-five ultrasonography negative cases, five percent (false negative) has meniscal injuries verified through magnetic resonance imaging

whereas twenty percent true negative had nil meniscal injury on magnetic resonance imaging. Therefore, negative and positive predictive value, specificity, diagnostic correctness, sensitivity in detecting meniscal injuries via ultrasonography was 80%, 96%, 86.96%, 92% and 93.50% respectively.

Table – I: Stratification of Age among males and females

Age	Male (76)	Female (24)
15 - 25 Years	21	8
26 - 35 Years	37	9
36 - 45 Years	11	4
45 - 50 Years	7	3

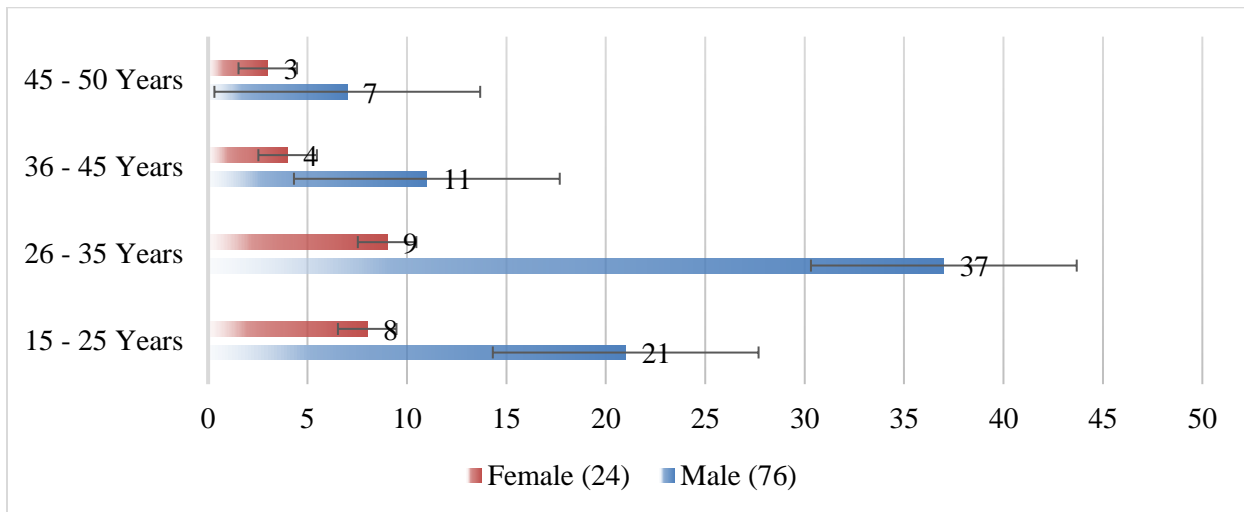


Table – II: Type of Trauma

Trauma Type	Male	Female
Direct	47	15
Indirect	29	9

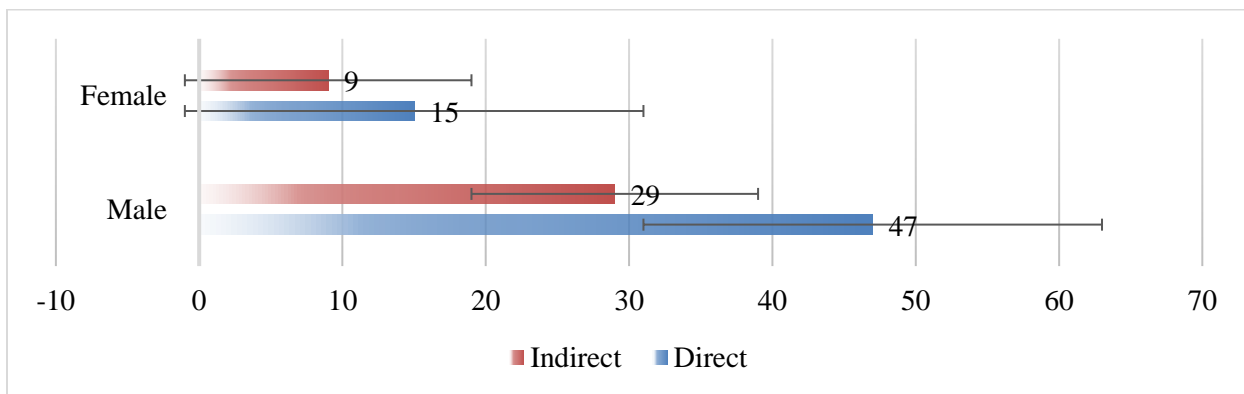


Table – III: MRI Outcomes

Outcomes	Positive Outcome on Ultrasonography	Negative Outcome on Ultrasonography
Positive MRI findings	72 (TP)	05 (FN)
Negative MRI findings	03 (FP)	20 (TN)

Table – IV: Stratification of gender with respect to age

Age	Male (60)		Female (15)	
	Number	Percentage	Number	Percentage
15 - 25 Years	15	20	4	5.33
26 - 35 Years	25	33.33	8	10.67
36 - 45 Years	11	14.67	2	2.67
45 - 50 Years	9	12	1	1.33

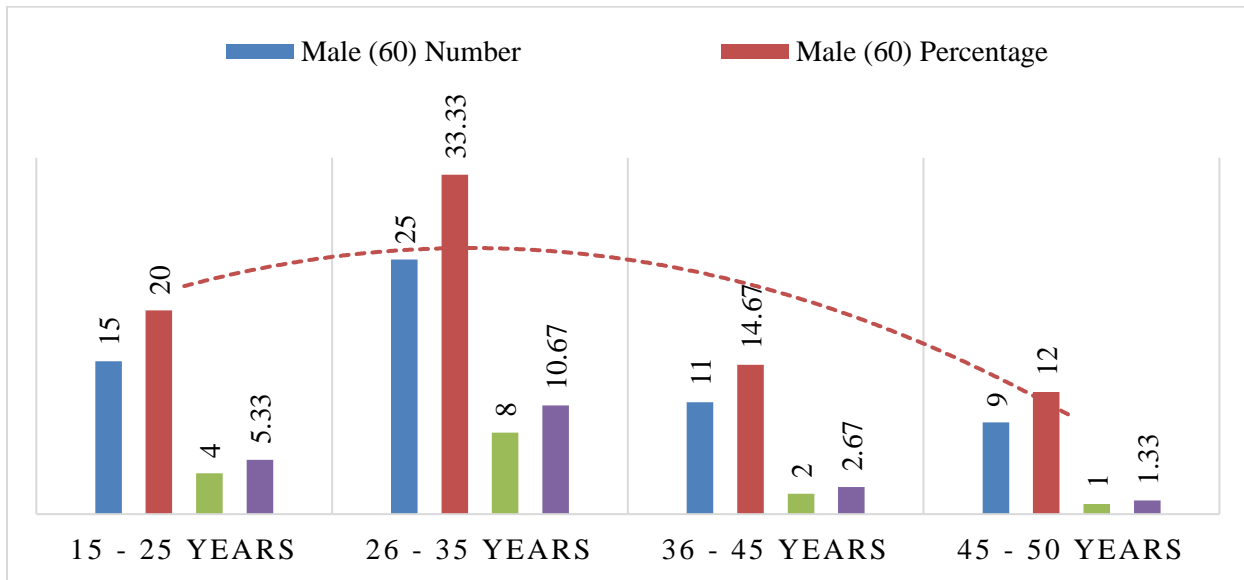


Table – V: Duration of Symptoms

Symptoms Duration	Presence of Meniscal Injury (77)		Absence of Meniscal Injury (23)	
	Number	Percentage	Number	Percentage
1 - 4 Weeks	46	59.74	10	43.47
Above 4 - 8 Weeks	31	40.26	13	56.52

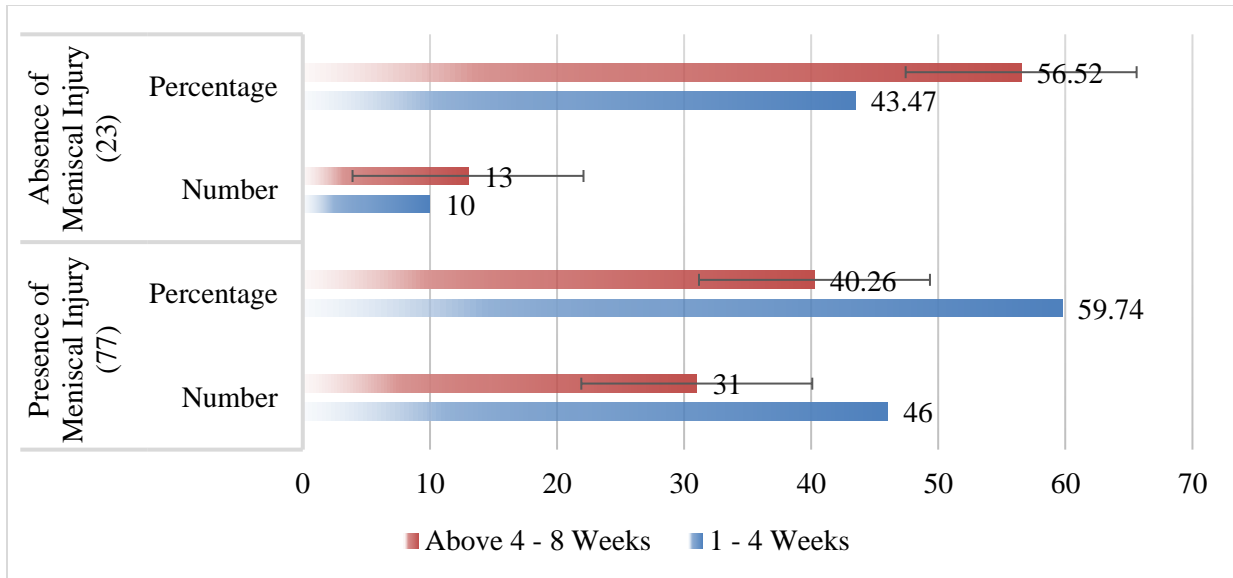
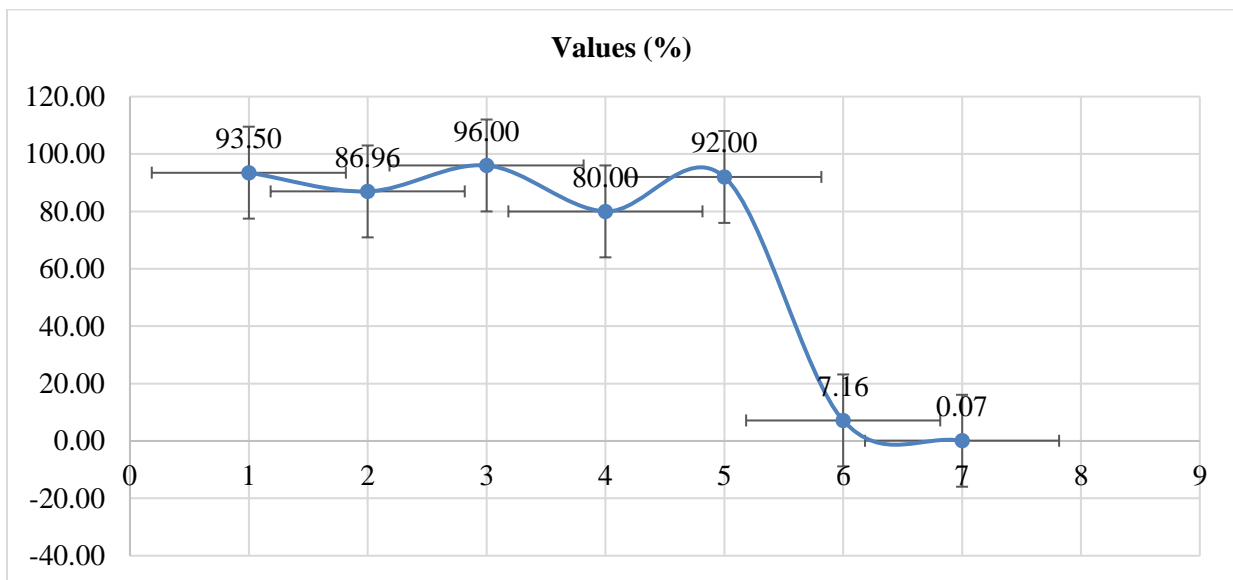


Table – VI: Ultrasonographic Evaluation

Ultrasonographic Assessment	Values (%)
Sensitivity	93.50
Specificity	86.96
Positive Predictive Value (PPV)	96.00
Negative Predictive Value (NPV)	80.00
Diagnostic Accuracy	92.00
Positive test result Likelihood	7.16
Negative test result Likelihood	0.07



DISCUSSION:

Most of the meniscal tears influence the medial meniscus and have a tendency to implicate the

posterior horn. Subsequently, experiments should be conducted to discover a diagnostic device that is available with ease, low price as well as noninvasive.

High resolution ultrasounds (HRUS) have entire of these favours but it might replace common procedure only if it has satisfactory sensitiveness as well as specificity. In current research HRUS has displayed improved sensitivity as well as specificity in spotting of meniscal tears which verified on magnetic resonance imaging report [9]. In the current research, the age range was from fifteen to fifty years with 30 ± 2.65 years of average age. Which is comparable to research conducted by Forouzmehr A et al and Khan RA et al that is thirty-two and twenty-nine years respectively [10, 11]. The research conducted by Mahmud MZ et al has displayed average age of thirty-nine years since he enrolled patients with much greater age in his research with respect to our research [12]. In one additional research conducted by Sharma UK et al and Mahmud MZ et al declare that meniscal injuries were too common in women whereas the current research displayed multiple of meniscal injuries in males [12, 13]. One more research performed by EL Monem SA et al and Forouzmehr A et al also displayed male's supremacy [14]. So current research presented the huge numbers of male's patients having meniscal injuries of knee joint (76%) with forty-six percent patients ranging between twenty-six to thirty-five years of age. This stated that males are mostly affected with meniscal injuries. This is with respect to national and international research which assists matured males' inclination for meniscal damages [10, 15]. The benefits of high-resolution ultrasounds include inexpensive, nil exposure to radiation, soft tissues direct visualization and promptly assessable dynamic research [16]. In current research diagnostic correctness specificity and sensitivity of HRUS in medial meniscus tear was 94%, 88% and 95.43% respectively whereas sideward meniscus tear was 90%, 88.96% and 91.83% respectively. The research conducted by Silvestri E et al, the sensitivity of ultrasound of the medial meniscus utilizing direct probe is 81% and for the sideward meniscus, it is 41% [17].

CONCLUSION:

This research determines that high-resolution ultrasonography emerges as safe, trustable, precise, available with ease as well as cost-effective procedure utilized for the assessment of meniscal injuries in the zone of low resources, however, MRI is costly and reachable to few ones. However, HRUS also has huge accuracy as well as sensitivity which are closer to magnetic resonance imaging. So, it is the first option to utilized HRUS as an initial evaluation for detecting meniscus injuries so the patients could prevent for conducting much expansive magnetic resonance imaging. So, the current research approved

the utilization of high-resolution ultrasound as a screening device.

REFERENCES:

1. Mahmoud MZ, Manssor EH, Abdulla A, Sid-Ahmed MI, Sulieman A. Ultrasound findings of the knee joint. *Ozean J Appl Sci.* 2012;5(4):243-50.
2. Sharma UK, Shrestha BK, Rijal S, Bijukachhe B, Barakoti R, Banskota B, et al. Clinical, MRI and Arthroscopic Correlation in Internal Derangement of Knee. *Kathmandu Univ Med J.* 2011;35(3):174-8.
3. EL-Monem SA, Enaba MM. Comparative study between high-resolution ultrasound (HRUS) and MRI in the diagnosis of meniscal and cruciate ligaments injury of the knee. *Med J Cairo Univ.* 2012;80(2):233-42.
4. Rahman A, Nafees M, Akram MH, Andrabi AH, Zahid M. Diagnostic accuracy of Magnetic Resonance Imaging in Meniscal injuries of the knee joint and its role in the selection of patients for arthroscopy. *J Ayub Med Coll Abbottabad.* 2010;22(4):10-14.
5. Chiang YP, Wand TG, Lew HL. Application of High-Resolution Ultrasound for Examination of the Knee Joint. *J Med Ultrasound.* 2007;15(4): 203-12.
6. Silvestri E, Martinoli C, Derchi LE, Bertolotto M, Chaisamondia M, Rosenberg I. Echotexture of peripheral nerves: correlation between US and histologic findings and criteria to differentiate tendons. *Radiol.* 1995; 197:291-96.
7. Harrison BK, Abell BE, Gibson TW. The Thessaly test for the detection of meniscal tears: validation of a new physical examination technique for primary care medicine. *Clin J Sports Med.* 2009;19(1):9-12.
8. Avcu S, Altun E, Akpınar I, Bulut MD, Eresov K, Biren T. Knee joint examinations by magnetic resonance imaging: The correlation of pathology, age, and sex. *North Am J Med Sci.* 2010; 2:202-4.
9. Jacobson J, Van Holsbeeck MT. Musculoskeletal ultrasonography. *Orthop Clin North Am.* 1998; 29:135-67.
10. Bin SI, Kim JM, Shin SJ. Radial tears of the posterior horn of the medial meniscus. *Arthroscopy.* 2004; 20:373-8.
11. Forouzmehr A. The Value of Sonography in Diagnosis of Meniscal Injury. *J Res Med Sci.* 2004; 5:216-19.
12. Khan RA, Baloch M, Awais SM. Is MRI Essential Prior to Arthroscopic Management of Internal Derangement of the Knee? Special Edition *Annals KEMU.* 2010;16(1): 42-4.

13. Madhusudhan TR, Kumar TM, Bastawrous SS, Sinha A. Clinical examination, MRI and arthroscopy in meniscal and ligamentous knee Injuries – a prospective study. *J Ortho Surg Res.* 2008; 3:19.
14. Buchman R, Diego F. Imaging of articular disorders in children. *Radiol Clin NAM.* 2004; 42:151-68.
15. EL-Monem SA, Enaba MM. Comparative study between high-resolution ultrasound (HRUS) and MRI in the diagnosis of meniscal and cruciate ligaments injury of the knee. *Med J Cairo Univ.* 2012;80(2):233-42.
16. Friedman L, Finlay K, Popovich T. Sonographic findings in patients with anterior knee pain. *J Clin Ultrasound.* 2003;31(2):85- 97.
17. Chiang YP, Wand TG, Lew HL. Application of High-Resolution Ultrasound for Examination of the Knee Joint. *J Med Ultrasound.* 2007;15(4): 203-12.