



CODEN [USA]: IAJPB

ISSN: 2349-7750

INDO AMERICAN JOURNAL OF PHARMACEUTICAL SCIENCES

<http://doi.org/10.5281/zenodo.3539560>

Available online at: <http://www.iajps.com>

Research Article

A DESCRIPTIVE STUDY TO EVALUATE LIVER HISTOLOGY OF CHRONIC HEPATITIS C PATIENTS

Dr Majid Khushi¹, Dr Muhammad Arslan², Dr Aymen Arif³

¹ Akhtar Saeed Medical and Dental College, Lahore

² Islamabad Medical and Dental College, Islamabad

³ Sharif Medical and Dental College, University of Health Sciences, Lahore

Abstract:

Objective: To evaluate liver histology of chronic hepatitis C patients, who were relapsers or non-responders to previous conventional therapy.

Methods: The descriptive case series was conducted in the Hepatology section of Medical Unit-III at the Services hospital, Lahore, Pakistan, from June, 2018 to May 2019. The study had 109 hepatitis C patients who had relapsed or not responded to the conventional interferon and ribavirin for at least 24 weeks. All the patients were subjected to liver biopsy. The inflammatory activity and fibrosis shown by the liver biopsies were assessed according to the Batts-Ludwig classification. SPSS version 20 was used to analyze data.

Results: A majority (n=57; 52.3%) of the 109 patients were female with hepatitis C virus genotype 3. Among these, 100 (91.7%) patients were non-responders and 9 (8.3%) were relapsers. The mean age of the patients was 38.9±8.8 years. The non-responders had elevated levels of serum aminotransferase. According to Batts-Ludwig classification, Grade 0 inflammation was not present in the non-responders and relapsers; grade 1 in 51 (46.8%); grade 2 in 47 (43.1%); grade 3 in 10 (9.2%); and grade 4 in 1 (0.9%). Stage 0 fibrosis was present in 10 (9.2%); stage 1 in 34 (31.2%); stage 2 in 36 (33.0%); stage 3 in 13 (11.9%); and stage 4 in 16 (14.7%).

Conclusion: Results suggested that even if it failed to eradicate hepatitis C virus, the conventional interferon and ribavirin therapy was able to halt the progress of necroinflammation and fibrosis.

Keywords: Hepatitis C, Non-responder, Relapser, Conventional interferon, Ribavirin.

Corresponding author:

Dr. Majid Khushi,

Akhtar Saeed Medical and Dental College, Lahore

QR code



Please cite this article in press Majid Khushi et al., A Descriptive Study To Evaluate Liver Histology Of
Chronic Hepatitis C Patients., Indo Am. J. P. Sci, 2019; 06(11).

INTRODUCTION:

Chronic hepatitis C virus (HCV) infection, including its sequelae, is an important healthcare problem in Pakistan. WHO has estimated that already about 180 million people are infected with HCV; 130 million of these are chronic HCV carriers and are at risk for developing liver cirrhosis and cancer. Every year, three to four million individuals are newly infected and 40-60 percent of them will develop chronic hepatitis [1]. Anti-viral therapy is an important consideration in the management of patients with chronic HCV infection, as a sustained virologic response (SVR) to therapy may halt fibrosis progression, decrease the risk of hepatocellular carcinoma, and improve survival [2,3]. Genotypes 3a and 3b are the most prevalent HCV genotypes in Pakistan and are most responsive to interferon and ribavirin combination therapy [4-6]. Using conventional interferon alpha (IFN- α) 3 million units three times per week along with daily ribavirin 800-1200mg for 6 months, three randomized, controlled trials from Taiwan, Italy and Sweden were the first to show significant higher SVR 43, 47, and 40% respectively [7]. Liver biopsy is the important tool to determine the response of treatment in non-responders and relapsers of IFN- α 3 plus ribavirin therapy and their relation with clinical and biochemical features. The aim of the present study was to evaluate liver histology of chronic hepatitis C patients, who were non-responders or relapsers to previous conventional therapy.

METHODOLOGY:

Conducted at the Hepatology Section of Medical Unit-III at the Services hospital, Lahore, Pakistan, from June, 2018 to May 2019, the study was approved by the Institution's Review Board. A total of 109 male and

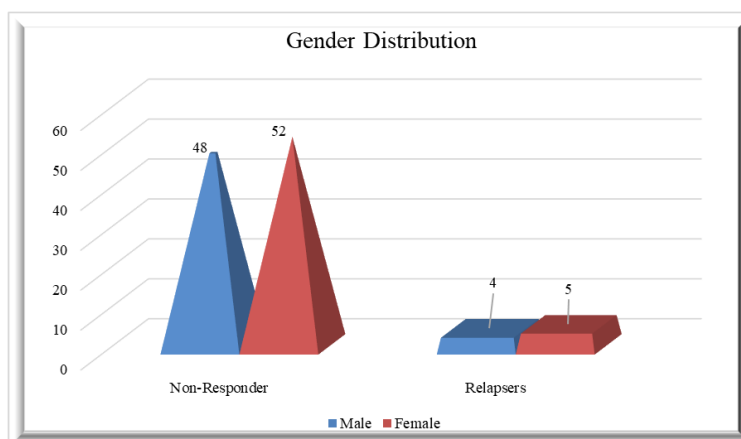
female outpatients aged >17 years with serological evidence of chronic hepatitis C by an anti-HCV antibody test and quantifiable serum HCV ribonucleic (RNA), who had previously received one course of conventional interferon 3 million units thrice per week plus ribavirin 800-1200 mg daily for at least 24 weeks were considered eligible for the study. Informed written consent was taken from all study participants. All patients had a liver biopsy that showed findings consistent with a diagnosis of chronic hepatitis C infection according to the Batts-Ludwig classification. The biopsies were done by trainees under supervision of consultants after taking informed written consent. Patients having previous course of conventional interferon monotherapy, age below 17 years, concomitant evidence of B or D virus infections, human immunodeficiency (HIV) infection, decompensated cirrhosis, alcohol or intravenous drug abuse, pregnancy, malignancy and autoimmune disease were not included. SPSS 20 was used to analyze data. Mean \pm standard deviation was calculated for quantitative variables.

RESULTS:

Of the 109 patients, 57 (52.3%) were women and 52 (47.7%) were men. Mean age was 38.9 ± 8.8 years (Table-1). Among these, 100 (91.7%) patients had never achieved undetectable HCV RNA (qualitative polymerase chain reaction [PCR] testing) during the first treatment, and were, thus, non-responders, while 9 (8.3%) patients had shown undetectable HCV RNA during the therapy, but had become HCV RNA positive after discontinuing medication and were, thus, relapsers. Genotype 1 was seen in 29 (26.6%) patients and Genotype 3 in 78 (71.6%). Genotype of 1 patient was missing.

Table No 01: Demographics and baseline characteristics of all patients

Characteristic	Non-Responder n= 100 (91.7%)	Relapsers n= 9 (8.3%)
Age (mean \pm SD)	39.19 \pm 8.91	35.89 \pm 8.35
Sex		
Male	48	4
Female	52	5
HCV		
Genotype 1	27	2
Genotype3	73	6
Missing	1	
Liver Function Tests		
Total bilirubin (mg/dl)	0.811 \pm 0.28	0.71 \pm 0.25
Aspartate aminotransferase (U/L)	75.40 \pm 52.11	42.3 \pm 9.27
Alanine aminotransferase (U/L)	68.46 \pm 43.56	54.43 \pm 36.42
Abdominal Ultrasound		
Normal	40	4
Hepatomegaly	16	3
Hypoechoic liver	5	1
Coarse liver &	8	0
Splenomegaly	2	0
Coarse liver	29	1
Haemoglobin (g/dl)	12.3 \pm 2.33	12.1 \pm 1.24
White blood cell count (/ml)	6412 \pm 2354	6722.22 \pm 2429.39
Platelet count (\times 103/ml)	205 \pm 90	246 \pm 97



Grade 1 inflammation were present in 51 (46.8%) patients; grade 2 in 47 (43.1%); grade 3 in 10 (9.2%); and grade 4 in 1(0.9%). Stage 0 fibrosis was present in 10 (9.2%) patients; stage 1 in 34 (31.2%); stage 2 in 36 (33.0%); stage 3 in 13 (11.9%); and stage 4 in 16 (14.7%) (Table-2).

Table No 02: Comparison of Histopathological Characteristics by Batts-Ludwig Classification

Histological severity* Batts-Ludwig classification	Non-Responder n= 100(%)	Relapsers n= 9(%)
Grade of Inflammation		
0	0	0
1	48 (48%)	3 (33.3%)
2	42 (42%)	5 (55.6%)
3	9 (9%)	1 (11.1%)
4	1 (1%)	0
Stage of Fibrosis		
0	10 (10%)	0
1	31 (31%)	3 (33.3%)
2	33 (33%)	3 (33.3%)
3	11 (11%)	2 (22.2%)
4	15 (15%)	1 (11.1%)
*Histological severity. Grade refers to the degree of portal, periportal and lobular activity including portal inflammation, piecemeal necrosis, liver cell degeneration and necrosis, and lobular inflammation. Stage refers to the extent of liver fibrosis.		

DISCUSSION:

Chronic hepatitis C patients who are non-responders and relapsers to conventional interferon (IFN) and ribavirin represent one of the most difficult challenges in clinical routine in Pakistan. The current standard of care for chronic hepatitis C is treatment with combination therapy of pegylated interferon (PEG-IFN) plus weight- based ribavirin, with an overall SVR rate of 70-90% in Asian patients compared with 50-80% in Caucasian patients [8,9]. In developing countries like Pakistan where the burden of chronic hepatitis C is increasing day by day, it is very difficult to prescribe PEG-IFN to every patient. In Pakistani patients with chronic hepatitis C, clinical observations indicate that SVR obtained with conventional IFN and ribavirin is higher than that in studies conducted in Western countries [10].

Hepatic fibrosis is a primary endpoint in the evaluation of the severity of chronic liver disease. Liver biopsy remains the gold standard for assessment of hepatic fibrosis [11]. In the current study, HCV infection was higher among women. The mean age of the non-responders was 39.19±8.9 years and relapsers 35.89±8.3 years, which is a very productive part of life.

Most of the patients were non-responders to conventional IFN therapy, and only 8.3% of the patients were relapsers. The most common HCV

genotype in both the relapsers and the non-responders was Genotype 3 followed by Genotype 1. Shin et al. reported in a cohort of Korean chronic hepatitis C (CHC) patients that risk factors for relapse were age older than 50 years, Genotype 1 cases, higher baseline HCV RNA level, while lower adherence to treatment was important in Genotype 2 and 3 patients [12]. Older age was not the risk factor in our patients. Treatment responses to antiviral therapy with IFN plus ribavirin have been shown to be influenced by the genotype, and the SVR is higher for patients with HCV Genotype 2 or 3 than for those with HCV Genotype 1 [13]. Majority of the non-responders and relapsers in our study had HCV Genotype 3, which reflects the most common HCV genotype in Pakistan [14]. Aminotransferase levels were high in the non-responders compared to the relapsers. Basso et al. indicated that alanine aminotransferase (ALT) elevation in the later course of antiviral therapy of HCV RNA negative patients was associated with virologic relapse [15]. In this study both mean ALT and aspartate aminotransferase (AST) levels were elevated in the non- responders compared to the relapsers.

The current study had limitations as baseline liver biopsy was not done, baseline HCV RNA levels were not checked and, on treatment, virological responses were not available.

CONCLUSION:

Even if not eradicating HCV, conventional anti-viral therapy is able to halt the progress of necroinflammation and fibrosis, and, hence, hepatocellular carcinoma. Although the number of patients in the study was very low; but stage IV fibrosis was not seen in the relapsers and they also had less degree of inflammation that might be the histological response with conventional interferon and ribavirin therapy. Further studies are required to establish this relationship with certainty.

REFERENCES:

1. Pradat P, Trepo C. HCV: epidemiology, modes of transmission and prevention of spread. *Bailliere's Best Pract Res Clin Gastroenterol* 2000; 14: 201-10.
2. Craxi A, Camma C. Prevention of hepatocellular carcinoma. *Clin Liver Dis* 2005; 9: 329-46.
3. Maylin S, Martinot-Peignoux M, Moucari R, Boyer N, Ripault MP, Cazals-Hatens D, et al. Eradication of hepatitis C virus in patients successfully treated for chronic hepatitis C. *Gastroenterology* 2008; 135: 821-9.
4. Hakim ST, Kazmi SU, Bagasra O. Seroprevalence of hepatitis B and C genotypes among young apparently healthy females of Karachi-Pakistan. *Libyan J Med* 2007; 7: 123-8.
5. Idrees M, Riazuddin S. Frequency distribution of hepatitis C virus genotypes in different geographical regions of Pakistan and their possible routes of transmission. *BMC Infect Dis* 2008; 8: 69.
6. Ahmad N, Asghar M, Shafique M, Qureshi JA. An evidence of high prevalence of Hepatitis C virus in Faisalabad, Pakistan. *Saudi Med J* 2007; 28: 390-5.
7. Lai MY. Combined interferon and Ribavirin therapy for chronic hepatitis C in Taiwan. *Intervirology* 2006; 49: 91-5.
8. Liu CH, Liu CJ, Lin CL, Liang CC, Hsu SJ, Yang SS, et al. Pegylated interferon-alpha-2a plus ribavirin for treatment-naïve Asian patients with hepatitis C virus genotype 1 infection: a multicenter, randomized controlled trial. *Clin Infect Dis* 2008; 47: 1260-9.
9. Yu ML, Chuang WL. Treatment of chronic hepatitis C in Asia: when East meets West. *J Gastroenterol Hepatol* 2009; 24: 336-45.
10. Zuberi BF, Zuberi FF, Memon SA, Qureshi MH, Ali SZ. Sustained virological response based on rapid virological response in genotype-3 chronic hepatitis C treated with standard interferon in the Pakistani population. *World J Gastroenterol* 2008; 14: 2218-21.
11. Saadeh S, Cammell G, Carey WD, Younossi Z, Barnes D, Easley K. The role of liver biopsy in chronic hepatitis C. *Hepatology* 2001; 33: 196-200.
12. Shin SR, Sinn DH, Gwak GY, Choi MS, Lee JH, Koh KC, et al. Risk factors for relapse in chronic hepatitis C patients who have achieved end of treatment response. *J Gastroenterol Hepatol* 2010; 25: 957-63.
13. Toyoda H, Kumada T, Kiriya S, Sone Y, Tanikawa M, Hisanaga Y. Differences in viral kinetics between genotypes 1 and 2 of hepatitis C virus after single administration of standard interferon- alpha. *J Med Virol* 2009; 81: 1354-62.
14. Ali A, Ahmed H, Idrees M. Molecular epidemiology of Hepatitis C virus genotypes in Khyber Pakhtoonkhaw of Pakistan. *Virol J* 2010; 7: 203.
15. Basso M, Giannini EG, Torre F, Bianchi S, Savarino V, Picciotto A. Elevations in alanine aminotransferase levels late in the course of antiviral therapy in hepatitis C virus RNA-negative patients are associated with virological relapse. *Hepatology* 2009; 49: 1442-8.