



CODEN [USA]: IAJPBB

ISSN: 2349-7750

INDO AMERICAN JOURNAL OF PHARMACEUTICAL SCIENCES

<http://doi.org/10.5281/zenodo.1450857>

Available online at: <http://www.iajps.com>

Research Article

MARROW SIGNAL MIMICKING TUMOR ON MRI T1-WEIGHTED IMAGING AFTER NEO-ADJUVANT CHEMOTHERAPY IN EXTREMITY OSTEOSARCOMAS

¹Dr. Sania Butt,²Dr. Safena Pervez,³Dr. Aeman Zahra Bukhari

¹WMO, DHQ Hospital, Sheikhpura.

²WMO, DHQ Hospital, Narrowal.

³WMO, BHU Kot Haibat, Dera Ghazi Khan.

Abstract:

Several studies had represented that Magnetic Resonance Imaging (MRI T1-weighted) considered a highly accurate approach to analyzing the intramedullary degree of margin osteosarcoma. Therefore, in this research, we recognized that after neo-adjuvant chemotherapy latest MRI T1 imaging with low signal was identified near the tumor, which imitated the progression of the tumor. The objective of this research was to elaborate the incidence and new signal type to divulge this imaging change with pathological correlation.

We comprised seventy-four highly osteosarcomas handled in the period of June 2011 to November 2012 in this reflective study. The MRI T1-weighted images of affected margin before the neo-adjuvant chemotherapy and after that process were analyzed and associated. These subjects were again organized as per the border appearance between the normal marrow and the area involved by osteosarcoma with specific attention paid to whether the border was constant and the width of the transition zone.

The population of this study was further categorizing into four different sub-sections: "clear", "continuous diffuse", "discontinuous island-like" and "discontinuous diffuse". Eleven patients endured MRI of consensual extremities and specifically for these patients, we analyzed the uninvolved extremity appearance with that with osteosarcoma. Below mentioned tumor's surgical resection, pathologic manifestation was associated with the pre-operative findings of MRI.

As per the system of classification, all seventy-four subjects were diagnosed "clear" before neo-adjuvant chemotherapy. Thirty subjects (which are 40.5%) after neoadjuvant chemotherapy were even clear. Similarly, off the forty-four (59.5%) not mentioned as "clear", 29.7% (22) were mentioned as "continuous diffuse", 5.4% (4) mentioned as "discontinuous island-like" and finally 24.3% (18) mentioned as "discontinuous diffuse". MRI of bilateral femurs subjects, there is no difference in radiology was distinguished in the normal marrow bilaterally.

Neo-adjuvant chemotherapy regarding extreme osteosarcoma may result in different alterations of the appearance of MRI of adjacent bone and marrow tumor. Points of signal change outside the tumor which signify marrow adaptation and not the progression of tumor represent on T1 weighted imaging to lesser in signal rather than subcutaneous fat with developed in indicating than muscle. Identifying the presence of the neo-adjuvant chemotherapy effect on the MR manifestation of the tumor and contiguous bone and myeloid components is significant so as to propose for oncological comprehensive tumor resections as circumventing resecting more typical bone than necessary.

Corresponding author:

Dr. Sania Butt,
WMO, DHQ Hospital,
Sheikhpura.

QR code



Please cite this article in press Sania Butt et al., *Marrow Signal Mimicking Tumor on MRI T1-Weighted Imaging after Neo-Adjuvant Chemotherapy in Extremity Osteosarcomas.*, Indo Am. J. P. Sci, 2018; 05(10).

1.0 INTRODUCTION:

Several studies had represented that MRI; (Magnetic Resonance Imaging) T1-weighted is a highly accurate approach to analyze the intramedullary degree of osteosarcoma extremity. Therefore, this research analyzed that after the process of neo-adjuvant chemotherapy, a zone of low signal strength on MRI, T1-weighted was noticed near the tumor, the radiological presence of the progression of the suggested tumor, but on ensuing pathologic analysis represented there is no involvement by tumor. This study objective was to explore and organize the several types of these signal alteration and to narrate their incidence. These images findings' correlates with pathological judgments was also achieved (Deng *et al.*, 2017).

2.0 METHODS:

In this study the data has been gathered through PubMed Database from all patients with Osteosarcoma from June 2011 to November 2012. In this database, all patients with one pre-chemotherapy and post-chemotherapy scans were included. Also, patients with two or more pre-operative MRI scans and communication systems (PACS) with electronic pictures were included. For the diagnosis of Osteosarcoma, biopsy was done to every individual. However, patients who had undergone surgery at the site of tumour or patients with pathological issues and patients with Osteosarcoma of Fibula as their marrow space was narrow were excluded (Bansal and Santosh, 2015).

This study was undergone 74 patients in which 45 males, 29 females with the age range 9-25 years were included. Tumour were reported to exist in Proximal tibia (26 patients), Distal Femur (39 Patients), Proximal Femur (1 Patient), Distal Tibia (1 Patient) and Proximal Humerus (7 Patients). High Dosage of Cisplatin, Methotrexate, Doxorubicin and Ifosfamide was given for chemotherapy. Moreover, during

chemotherapy, leukopenia was diagnosed in all patients after whom G-CSF was given for Marrow Hyperplasia. Computed Tomography (CT), CT scan of the chest, Plain Radiographs, Total Body Scintigraphy and MRI of the limbs was done in staging studies (Jyoti, 2015).

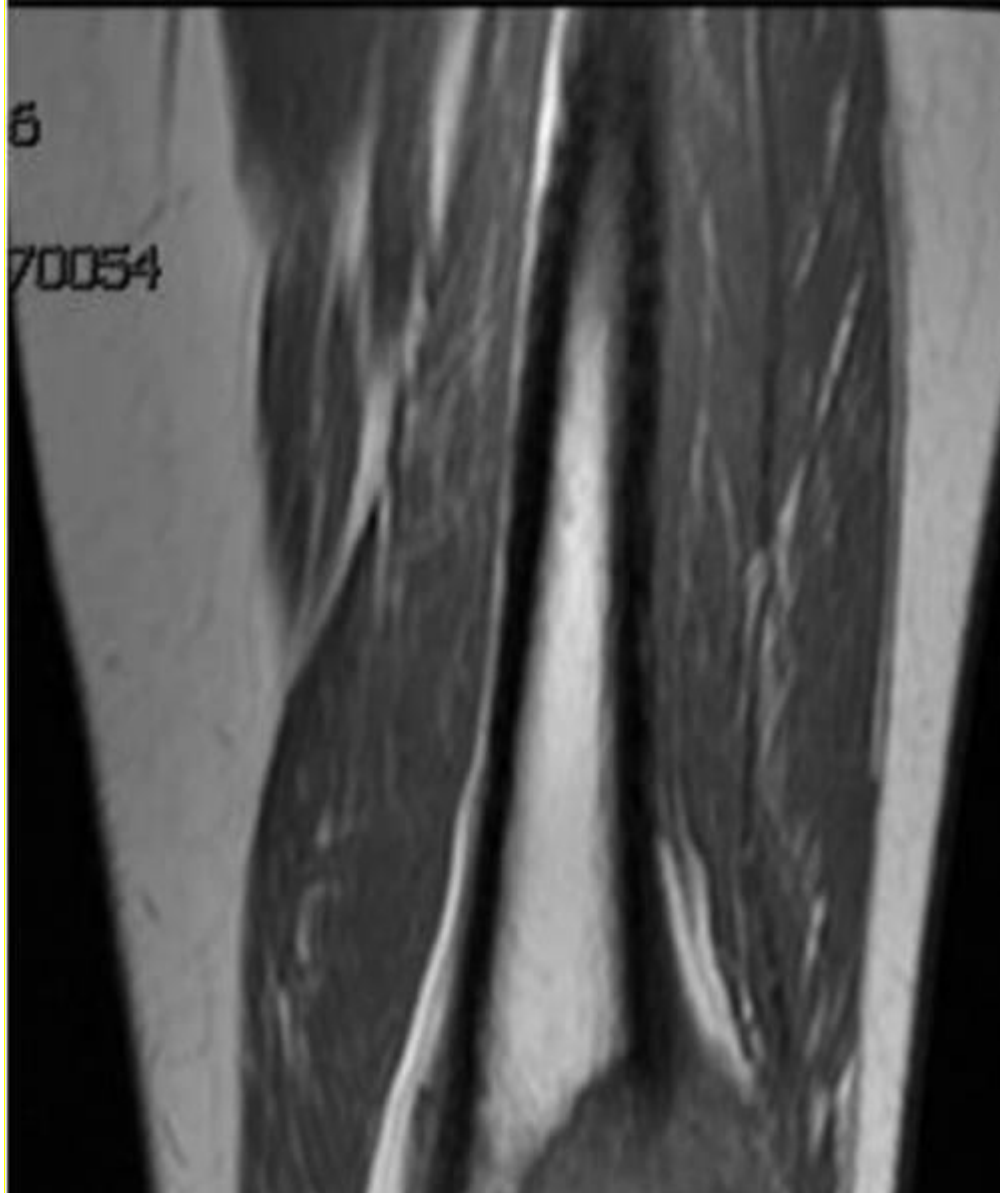Pre-chemotherapy and Post Chemotherapy T1 weighted imaging was the criteria set for taking up the MRI examinations. All the patients were followed-up in a pattern. This pattern was 3 months in the first 2 years, 4 months for the 3rd and 4th year and every 6 months in the 5th year. Cases notes were made in order to note down all the minor and major details of every single patient for a better outcome and results (Rozenblatt *et al.*, 2018).

3.0 RESULTS

3.1 Signal Types

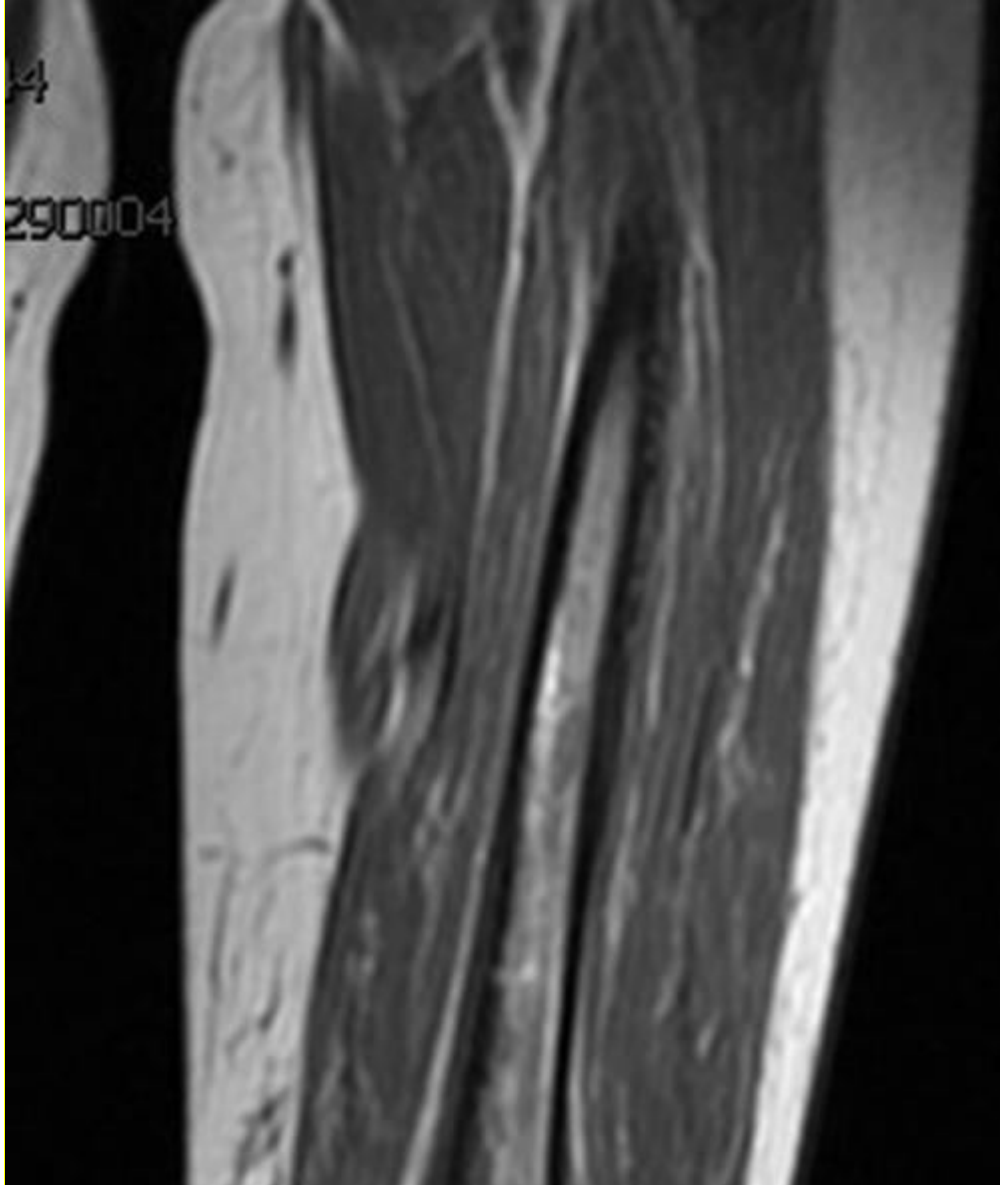
A total of 12447 articles were approved from the 15824 articles of the required topics, shortlisting them genuine and authorized. Out of these, 236 were selected by abstract and title screen, but after full-text analysis 205 were excluded. Moreover, 11 more articles were also excluded due to uncooperative behavior (permission issues) or incomplete data. Furthermore, only 20 articles were finalized after shortlisting the articles. After a very detailed study, for meta-analysis, only 11 studies were selected and later finalized for reports which were complete (Rozenblatt *et al.*, 2018).

Four groups were made by shaping MRI T1-weighted imaging, these groups were as follow: "Discontinuous Diffuse", "Discontinuous Island-like", "Continuous Diffuse" and "Clear". Clear: In Fig.1, Distinct margin is seen interpolating the two areas of normal fatty marrow with high signal intensity and the areas affected by tumors with low signal intensity (Rozenblatt *et al.*, 2018).



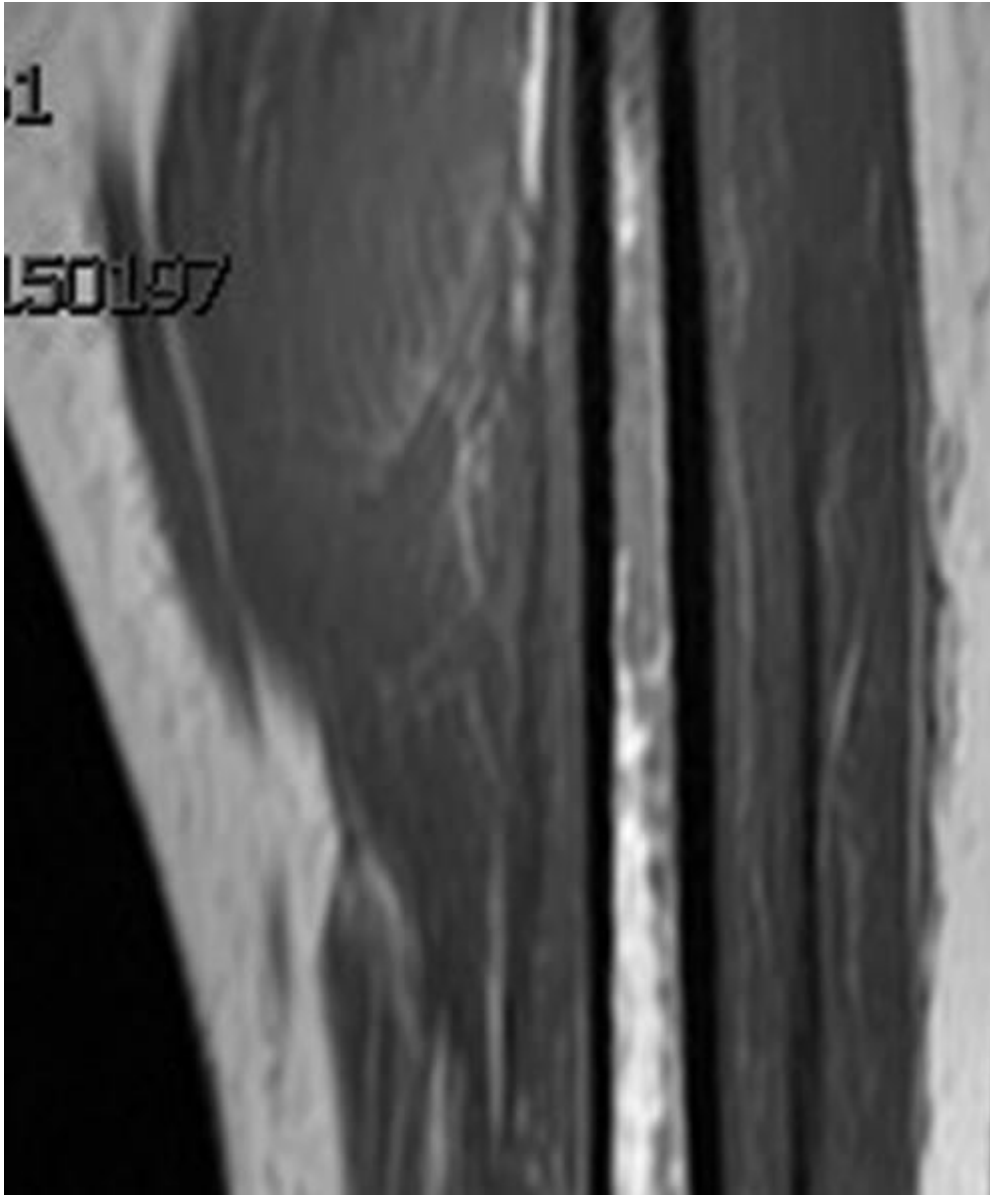(Source: Rozenblatt et al., 2018)

Continuous Diffuse: In Fig.2. The area spotted with tumor and unpatched was under intermediate signal. This was the area having signal intensity lower than normal fatty marrow and tumor but higher than the skeletal muscles.



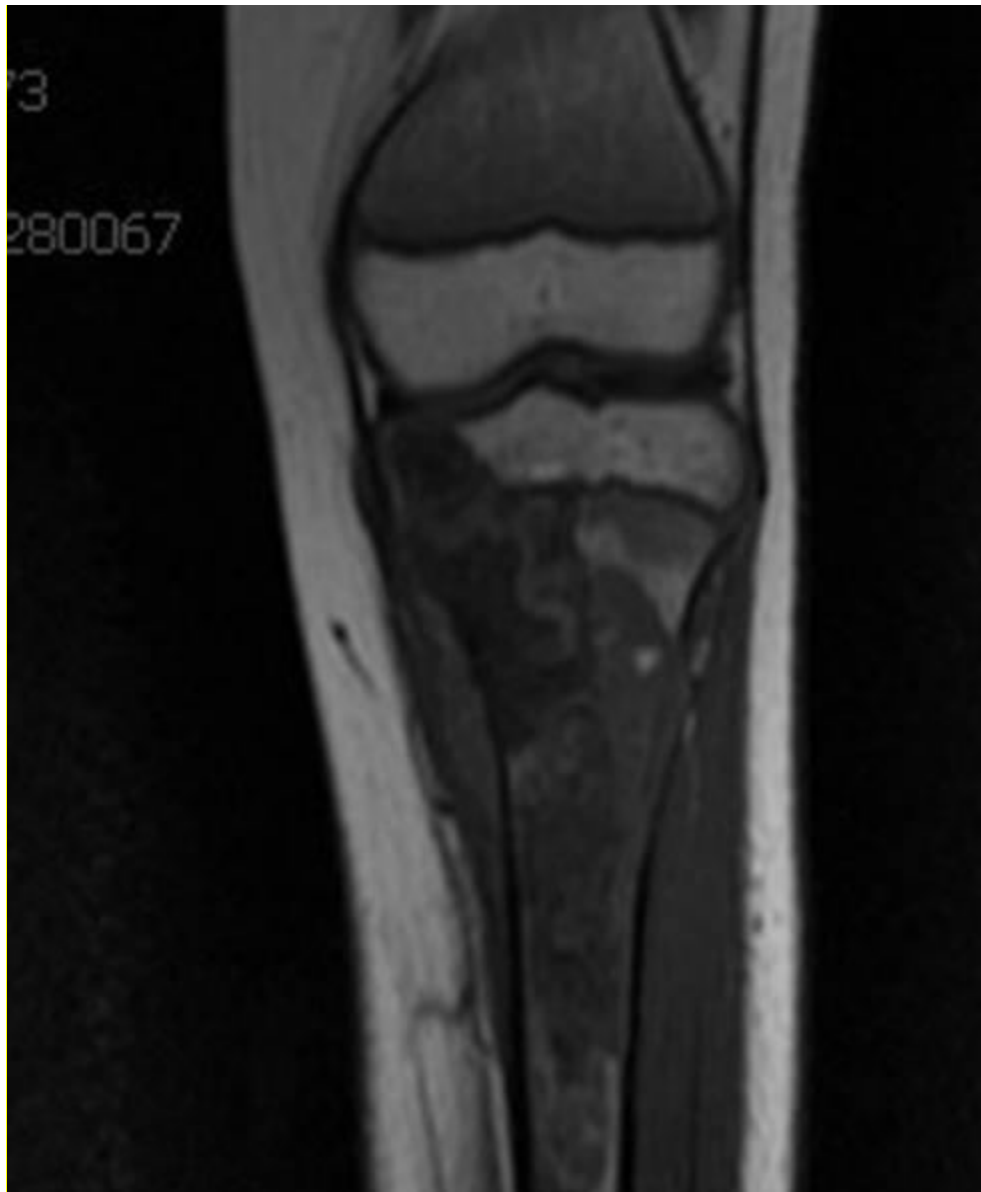(Source: Rozenblatt et al., 2018)

Discontinuous Diffuse: As shown in Fig.3. The patchy, diffused are the areas with intermediate signal intensity. Moreover, these were interweaving with the areas of normal fat signals and non- contiguous with tumor.



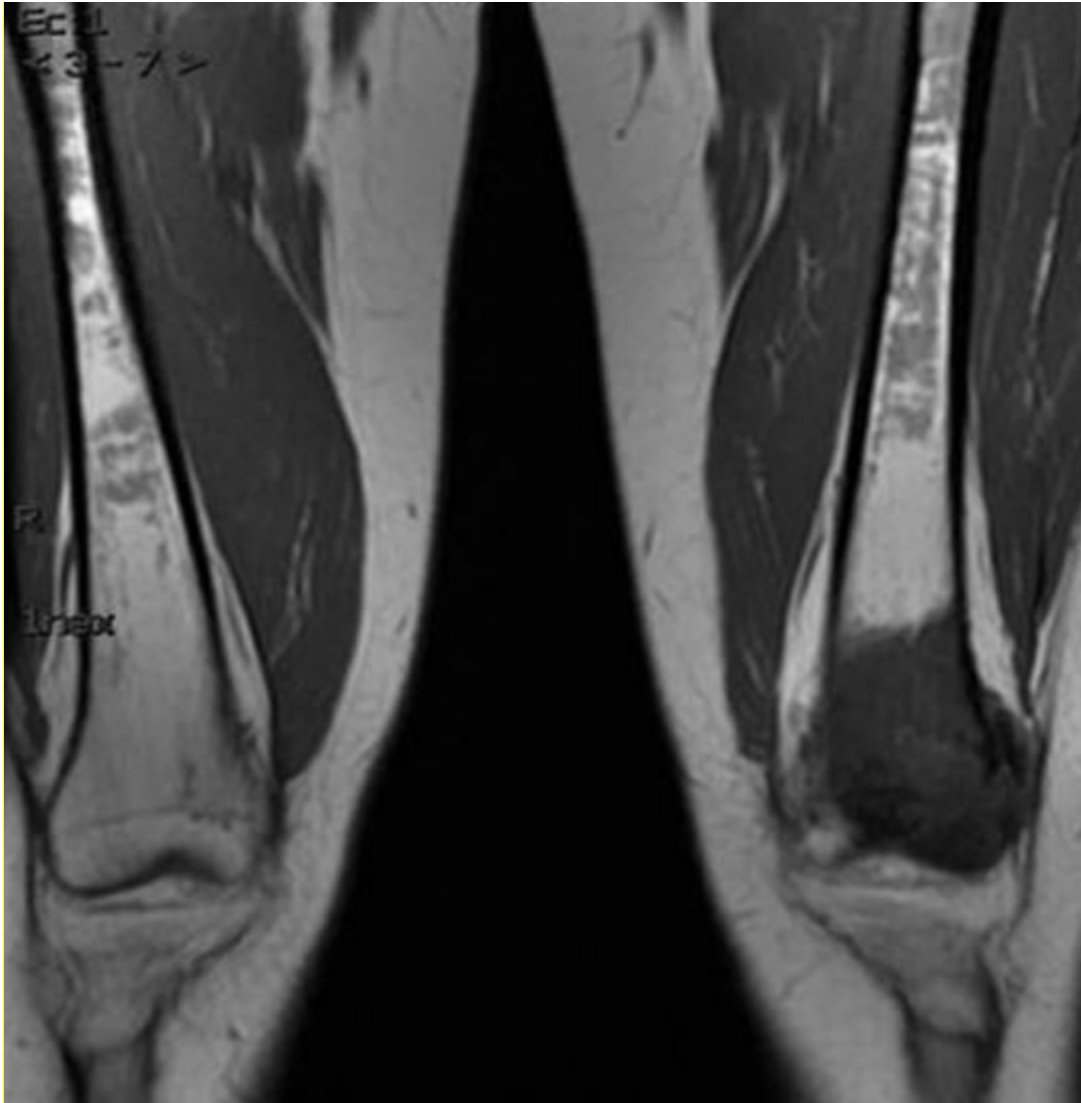
(Source: Rozenblatt et al., 2018)

Discontinuous Island-like: The Fig.4 shows, a normal fat signal was seen between the locations of intermediate signal above the tumor.



3.2 The incidence of Signal Change

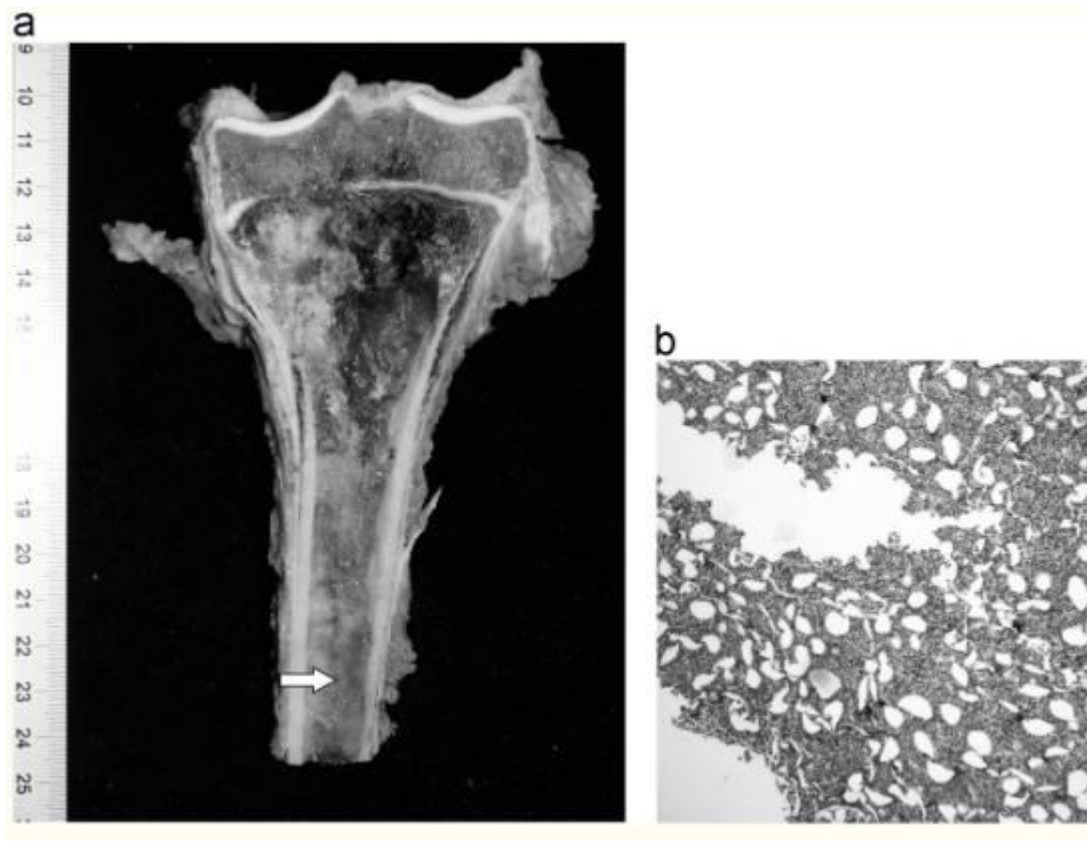
Initially, a total of 74 cases were selected that were marked clear before the neoadjuvant chemotherapy. After the process, about 30 cases were still labeled as clear contributing to 40.5% of the result. In the rest of the 44 cases; different categories were made. These were categorized as, “Discontinuous island-like” – 4 cases (“5.4 %”), “Continuous Diffuse”- 22 cases (“29.7 %”) and “Discontinuous Diffuse” – 18 cases (“24.3 %”). In 11 of the cases, femurs at the bilateral extremities were identified in the MRI in post-chemotherapy. The marrow signal in the Normal femur and the Osteosarcoma femur were alike as shown in Fig.5. Only hematopoietic cells were identified in the results with no traces of tumor in the histological studies (Sugiyanto, 2017).



(Source: Rozenblatt et al., 2018)

3.2.1. Pathological correlation

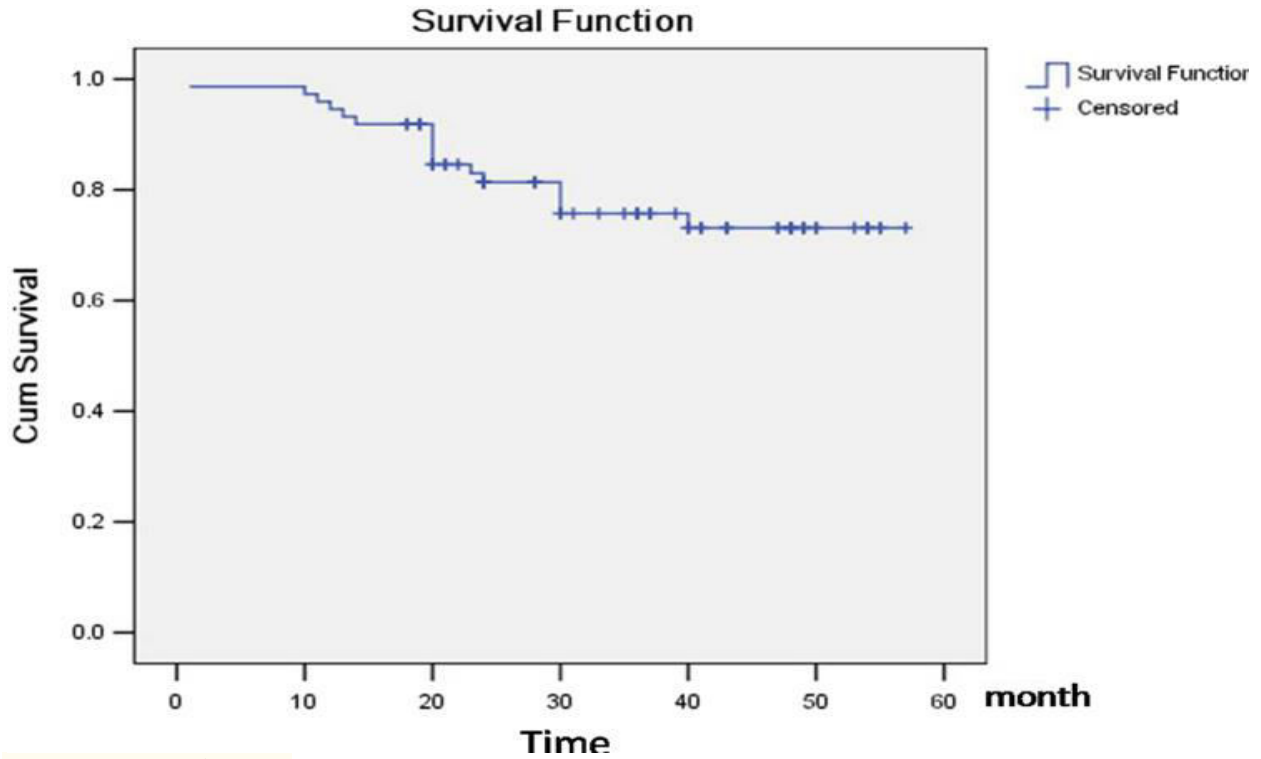
Only hematopoietic cell proliferation was seen in the images as shown in Fig. 6A and 6B. However, in Intermediate Signal Intensity no tumor was seen in patients.



(Source: Rozenblatt *et al.*, 2018)

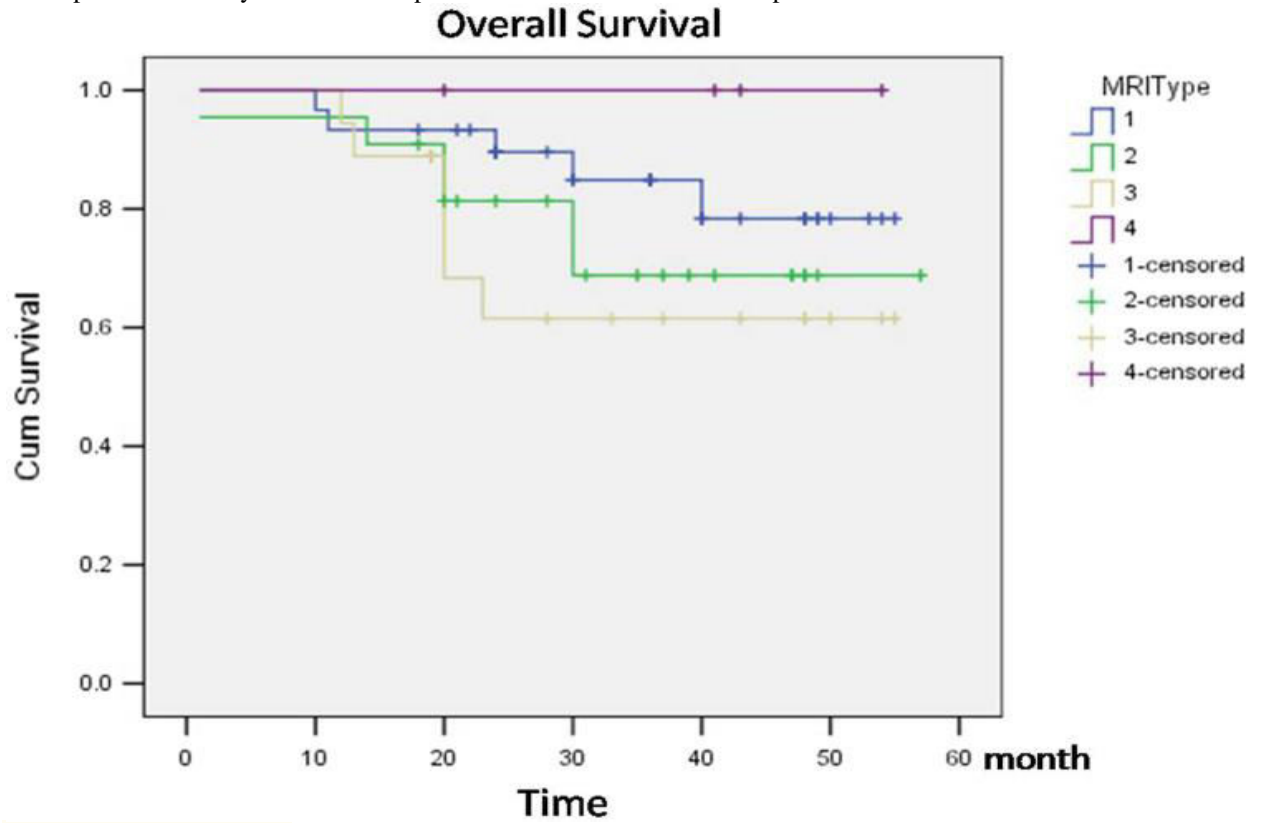
3.2.2. Follow-up

The follow-up time period was from 1 month and lasted to 57 months, making cases for 37 months on average. Considering the patients who were alive, the follow-up sessions were from 19 months to 57 months. Moreover, due to the development of local recurrence leading to metastasis, one patient collapsed at the spot while sixteen other patients survived. However, due to metastasis, later a total of seventeen patients died. Fig.7 shows the ratio of overall patients who survived; whereas, Fig 8 and Fig.9 shows an MRI findings in which an overall survival and relapse free survival is shown, resulting to no difference between the four types of MRI of the patients (Rozenblatt *et al.*, 2018)



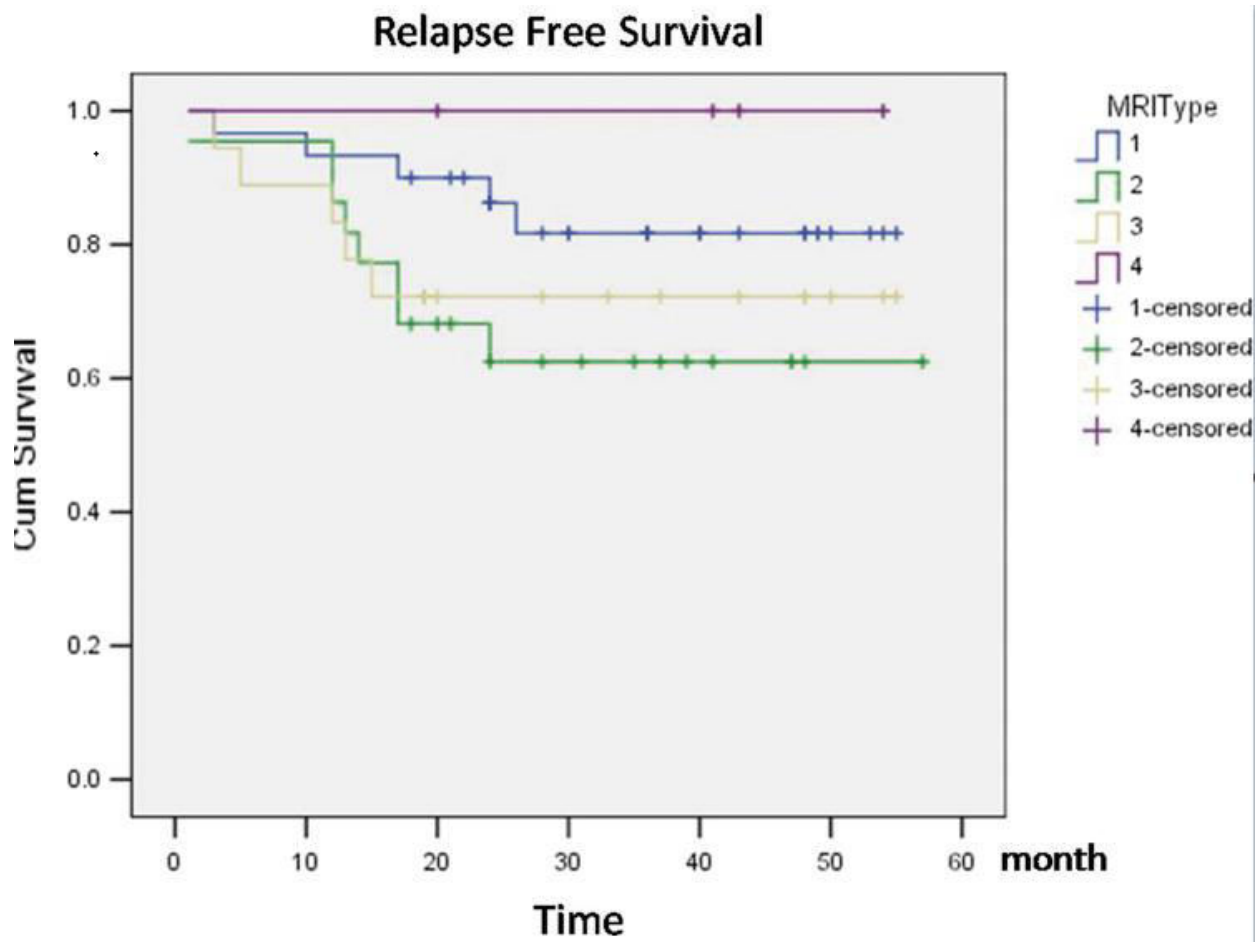
(Source: Deng et al., 2017)

A comprehensive study of all survival patients is shown in the above Kaplan-Meier Survival Curve.



(Source: Deng et al., 2017)

Overall Survival for subjects is shown conforming to subtypes of four imaging displayed in the above Kaplan-Meier Survival Curve.



(Source: Deng et al., 2017)

This above mentioned Kaplan-Meier survival curve representing relapse-free survival organized to the 4 imaging sub-types.

4.0 DISCUSSION:

The outputs of this study represent that, specifically after osteosarcoma neo-adjuvant chemotherapy the signal alteration are general at MRI in the long bones marrow, comprising 29.7% “continuous diffuse” 24.3% discontinuous diffuse and “discontinuous island-like”. The osteosarcoma patients’ survival has elevated intensely as the chemotherapy. MRI has been largely utilized to analyze the tumor extent in the period of osteosarcoma neo-adjuvant chemotherapy. Due to the regenerating of red marrow, on T1-weighted images, the signal intensity declines. Accordingly, we can observe the MRI new signal that is hematopoietic marrow representing tumor. These hematopoietic cells which are commonly symmetric and bilateral represented in this research (Deng et al., 2017).

GCSF (“Granulocyte Colony-Stimulating Factor”) is utilized to encourage in the production of myeloid cells in osteosarcoma patients experiencing chemotherapy. Some researchers have elaborated the MRI signal alteration observed in patients after the utilization of “Granulocyte Colony-Stimulating Factor”. The signal alteration may diffuse homogeneously, simulating the progress of tumor. These alterations may also be described bilaterally and symmetrically or asymmetrically (Rozenblatt et al., 2018).

Occurrence awareness of this alteration is significant to circumvent of this alteration is significant to evade an incorrect judgment of metastases or the progression of the tumor. This study represents how generally this singularity of reconversion of marrow

which can be MRI when GCSF was managed to patients with osteosarcoma. The oncological outputs represent that there are no important variance patients with the finding of MRIs four subtypes. The utilization of GCSF can accelerate the signal alteration in marrow but this alteration is not associated with the oncological outputs (Deng et al., 2017).

CONCLUSION:

At the concluded note, we have designated the kinds and signal changes occur which can be distinguished after neo-adjuvant chemotherapy osteosarcoma in patients. These ranges transitional in the intensity of the signal to hypodermic fat and T1-weighted MRI imaging signals epitomize marrow adaptation and not the progression of the tumor. Establishing of this kind of alteration can evade resecting more general bone in surgery of limb salvage.

REFERENCES:

1. Abbott, D., Pell, G., Pardoe, H. and Jackson, G. (2009). Voxel-based iterative sensitivity analysis of T1-weighted MRI signal intensity (VBIS-T1). *NeuroImage*, 47, p.S125.
2. Bansal, G. and Santosh, D. (2015). Accuracy of MRI for prediction of response to neo-adjuvant chemotherapy in triple negative breast cancer. *Cancer Imaging*, 15(Suppl 1), p.P18.
3. Deng, Z., Ding, Y., Hao, L., Zhang, Q., Su, Y. and Niu, X. (2017). Marrow signal mimicking tumor on MRI T1-weighted imaging after neoadjuvant chemotherapy in extremity osteosarcomas. *Journal of Bone Oncology*, 6, pp.22-26.
4. Eric, J. (2010). The quantitative Relation Between T1-Weighted and T2-Weighted MRI of Normal gray Matter and iron concentration. *Journal of Magnetic Resonance Imaging*, 5(5), pp.554-560.
5. Hanrahan, C. and Shah, L. (2011). MRI of Spinal Bone Marrow: Part 2, T1-Weighted Imaging-Based Differential Diagnosis. *American Journal of Roentgenology*, 197(6), pp.1309-1321.
6. Intven, M., Reerink, O. and Philippens, M. (2012). Diffusion-weighted MRI in locally advanced rectal cancer. *Strahlentherapie und Onkologie*, 189(2), pp.117-122.
7. Jyoti, B. (2015). Accuracy of MRI for Prediction of Response to Neo-Adjuvant Chemotherapy in Triple Negative Breast Cancer Compared to Other Molecular Types. *Chemotherapy: Open Access*, 05(01).
8. Rozenblatt, S., Luckman, J., Yust-Katz, S. and Siegal, T. (2018). P01.104 Evaluation of high signal intensity in globus pallidus and dentate nucleus on unenhanced T1-weighted images after administration of Dotarem vs. Gadavist in brain tumor patients who undergo multiple MRI evaluations. *Neuro-Oncology*, 20(suppl_3), pp.iii255-iii255.
9. Stell, V., Flippo-Morton, T., James Norton, H. and White Jr., R. (2010). Sentinel Lymph Node Biopsy After Neo-adjuvant Chemotherapy. *The Breast Journal*, 17(1), pp.71-74.
10. Sugiyanto, A. (2017). Receive Bandwidth Variation Effect Toward the Signal and Contrast to Noise Ratio in Magnetic Resonance Imaging (MRI) Cervical Examination with the Sequence of T1 Weighted Turbo Spin Echo. *Journal of Medical science and clinical research*, 5(7).
11. Wu, R., Liu, C., Liu, P. and Sun, P. (2012). Improved measurement of labile proton concentration-weighted chemical exchange rate (k_{ex}) with experimental factor-compensated and T1-normalized quantitative chemical exchange saturation transfer (CEST) MRI. *Contrast Media & Molecular Imaging*, 7(4), pp.384-389.