



CODEN [USA]: IAJ PBB

ISSN: 2349-7750

**INDO AMERICAN JOURNAL OF  
PHARMACEUTICAL SCIENCES**<http://doi.org/10.5281/zenodo.1461012>Available online at: <http://www.iajps.com>

Research Article

**CLINICAL PRESENTATION OF INFECTIVE ENDOCARDITIS  
IN HOSPITALIZED PATIENTS****\*Dr. Mariam Tariq, \*Dr. Muhammad Faizan Adeel Khan, \*Dr. Samman Khalid**  
\*Rawalpindi Medical College, Rawalpindi Pakistan**Abstract:**

**Objective:** To investigate the presentation forms, precursor lesions, complications and other clinical parameters related to infective endocarditis.

**Study design:** A case series.

**Place and duration of the study:** From May 2016 to May 2017, the study was carried out in Cardiology Department of Rawalpindi Institute of Cardiology for one year duration.

**Methodology:** Data related to the symptoms, complications, predisposing factors and place of participation of the disease were collected. All patients with the possibility of infectious endocarditis were subjected to trans-thoracic echocardiography. Blood cultures were also sent. Data were analyzed using SPSS version 10.

**Results:** 86 patients were included in the study. Fever was the most common clinical presentation in the study population (87%). The mitral valve was the most affected area (55% of patients). Most of the patients (77%) had rheumatic valve heart disease as a precursor lesion.

**Conclusion:** The majority of patients presented with fever. The prevalence of rheumatic heart disease and embolic complications was higher.

**Key words:** infectious endocarditis, rheumatic heart disease.

**Corresponding author:**

**\*Dr. Mariam Tariq,**  
\*Rawalpindi Medical College,  
Rawalpindi, Pakistan

QR code



Please cite this article in press Mariam Tariq et al., **Clinical Presentation of Infective Endocarditis in Hospitalized Patients.**, Indo Am. J. P. Sci, 2018; 05(10).

**INTRODUCTION:**

Endocarditis is a bacterial or fungal infection of the valvular or endocardium surface of the heart. Prototypic injury is a mass of infective endocarditis, vegetation, platelets, fibrin, microorganisms and few inflammatory cells. Infection typically includes: (as natural or prosthetic) heart valves, also abnormal blood as jets, or damage to foreign bodies can occur on the low-pressure side of the ventricular septum at a defect in the wall endocardium or the intracardiac devices themselves. Responsible partner organisms usually include the group's viridians Streptococcus, Enterococcus, Staphylococcus aureus and Streptococcus epidermis. Other organisms are rarely reported and included gram negative anaerobe, Coxiella burnetii, chlamydia, Candida, Aspergillus and Histoplasmosis. Beta-hemolytic streptococcal group A (GABS) is a rare cause of Streptococcus pyogenes endocarditis. Predisposing cardiac conditions lead to valvular disease, rheumatic fever, a history of endocarditis, congenital heart disease and a pacemaker. Infective endocarditis (IE) is associated with a number of complications. Peripheral systemic embolism is a common and serious complication of

infective endocarditis due to the migration of vegetations. Transthoracic echocardiography is inexpensive, easy to obtain and specific to endocarditis diagnosis. Despite advances in medical, surgical and critical care interventions, infectious endocarditis is associated with significant morbidity and mortality. Therefore, an appropriate diagnosis and adequate, medical or surgical treatment is required. Recommended for patients with infectious endocarditis and congestive heart failure for medical treatment, emergency surgery-induced valve deficiencies, uncomplicated infectious endocarditis for uncomplicated infectious endocarditis, while the patterns are not supported by evidence from randomized trials.

**MATERIALS AND METHODS:**

This cases series was taken place from May 2016 to May 2017, the study was carried out in Cardiology Department of Rawalpindi Institute of Cardiology for one year duration. All patients diagnosed with infective endocarditis according to Duke Criteria were included in the study.

### Duke's Criteria for Infective Endocarditis

**Major Criteria**

- Positive echocardiography
- Positive blood culture

**Minor Criteria**

- Predisposing conditions
- Fever  $> 37^{\circ} \text{C}$
- Vascular phenomenon
- Immunologic phenomenon
- Suggestive echocardiogram
- Ambiguous blood culture

Diagnosis of infective endocarditis requires two major, or one major and three minor or five minor criteria.

Data were collected related to disease symptoms (fever, weight loss, anorexia, nausea, arthralgia or myalgia, headache, fatigue, etc.), complications (petechiae, Osler's lymph nodes, Janeway lesions), Roth, subconjunctival hemorrhage, bleeding, splenomegaly, cerebral embolism, etc.), predisposing factors and place of participation. All patients with the possibility of infectious endocarditis were subjected to trans-thoracic echocardiography. Blood cultures were also sent. Patients with strong suspicion of alternative diagnosis were excluded from the study. Data were analyzed using SPSS version 10. The frequencies and percentages of different clinical parameters were calculated.

**RESULTS:**

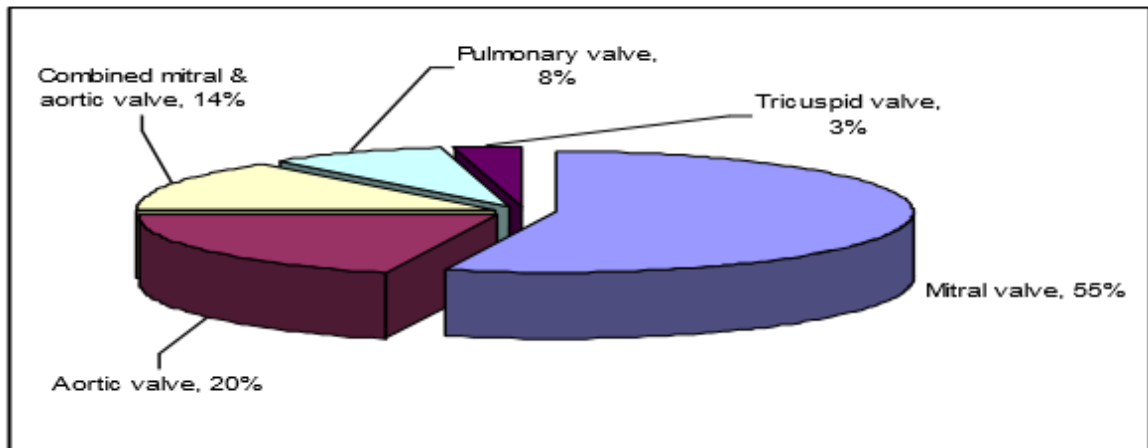
86 patients were included in the study. In the study group, the most frequent clinical presentation (87%) was fever, loss of appetite, tremor and sweating, fatigue, nausea and weight loss (Table 1).

**Table 1: Frequency of presenting clinical features**

Clinical Parameters	%age
Fever	87
Anorexia	44
Chills and sweats	56
Fatigue	33
Nausea	27
Weight loss	15
Headache	23
Arthralgias and myalgias	12

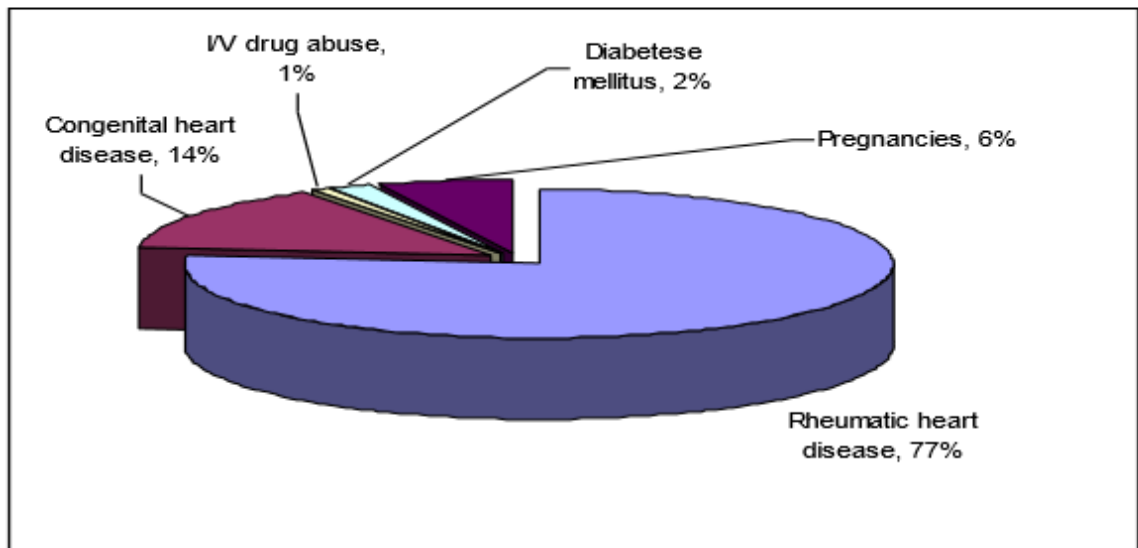
The mitral valve is the most frequently affected area (55%, n = 47) as shown in Figure 1.

**Fig. 1: Site of Endocardial Involvement**



The majority of patients (77%, n = 66) had a rheumatic heart disease, such as pre-substance lesion, 1 (Fig. 2).

**Fig.2: Prevalence of precursor lesions for Infective Endocarditis**



Data on the frequency of various complications and systemic characteristics of the disease are presented in Table 2.

**Table 2: Prevalence of complications**

Parameter	%age	=n
Splenomegaly	32.5	28
Petechial rash	4.6	4
Osler's nodes	8.1	7
Janeway lesions	6.9	6
Splinter hemorrhage	10.5	9
Subconjunctival hemorrhage	12.8	11
Roth's spots	5.8	5
Cerebral embolism	19.8	17
Peripheral embolism	13.9	12

### DISCUSSION:

Infective endocarditis is a rare disease, and it affects approximately 10,000 to 20,000 people in the United States every year. Infectious endocarditis occurs in about one-third of patients and up to 65% of systemic emboli, which is related to the central nervous system, is the second most common cause of deaths after congestive heart failure in this patient population. The risk of embolism was reported to be particularly high during the first week after diagnosis. In our study, mitral valve was the most common site in infective endocarditis, whereas Netzer et al. In one study, it was reported that the aortic valve was the most affected part. The limitation of the study was that the prosthetic valve endocarditis was not a single-center study that was carried out in a training hospital in southern Punjab, so that the only case study was found during the period. In this part of the country, like rheumatic heart disease, rheumatic valve lesions were infectious endocarditis. In our study group, second most common precursor lesions were congenital heart diseases. Cerebral embolism was documented in 19.8% of patients, compared to that reported by Netzer et al. (9%).

### CONCLUSION:

Most patients with infective endocarditis showed typical fever symptoms. Rheumatic heart disease was more frequent in our study than previously published data. The risk of embolic complications was also relatively high.

### REFERENCES:

1. Trinh, Trang D., Evan J. Zasowski, Kimberly C. Claeys, Anthony M. Casapao, Matthew Compton, Abdalhamid Lagnf, Shravya D. Kidambi, Donald P. Levine, and Michael J. Rybak. "Role of Vancomycin Minimum Inhibitory Concentrations by Modified

Population Analysis Profile Method and Clinical Outcomes in High Inoculum Methicillin-Resistant *Staphylococcus aureus* Infections." *Infectious diseases and therapy* 7, no. 1 (2018): 161-169.

2. Shahid, Uzma, Hasanat Sharif, Joveria Farooqi, Bushra Jamil, and Erum Khan. "Microbiological and clinical profile of infective endocarditis patients: an observational study experience from tertiary care center Karachi Pakistan." *Journal of cardiothoracic surgery* 13, no. 1 (2018): 94.
3. Garrido, Rafael Quaresma, José Oscar dos Reis Brito, Ralph Fernandes, Giovanna Ferraiuoli Barbosa, Marcelo Goulart Correia, Wilma Felix Golebiovski, Clara Weksler, and Cristiane C. Lamas. "Early Onset Prosthetic Valve Endocarditis: Experience at a Cardiothoracic Surgical Hospital, 2006–2016." *Surgical infections* 19, no. 5 (2018): 529-534.
4. Young, William J., Daniel A. Jeffery, Alina Hua, Chris Primus, Robert Serafino Wani, Satya Das, Kit Wong et al. "Echocardiography in Patients With Infective Endocarditis and the Impact of Diagnostic Delays on Clinical Outcomes." *The American Journal of Cardiology* (2018).
5. Subbaraju, P., Rai, S., Morakhia, J., Midha, G., Kamath, A. and Saravu, K., 2018. Clinical–microbiological characterization and risk factors of mortality in infective endocarditis from a tertiary care academic hospital in Southern India. *Indian heart journal*, 70(2), pp.259-265.
6. Nunes, Maria Carmo Pereira, Milton Henriques Guimarães-Júnior, Pedro Henrique Oliveira Murta Pinto, Rodrigo Matos Pinto Coelho, Thais Lins Souza Barros, Nicole de Paula Aarão Faleiro Maia, Dayane Amaral Madureira et al. "Outcomes of infective endocarditis in the current era: Early predictors of a poor prognosis." *International Journal of Infectious*

- Diseases*68 (2018): 102-107.
7. Regueiro A, Falces C, Pericás JM, Muñoz P, Martínez-Sellés M, Valerio M, Regueiro DS, Castelo L, de Alarcón A, Belaustegui MC, Goenaga MA. Risk factors of pericardial effusion in native valve infective endocarditis and its influence on outcome: A multicenter prospective cohort study. *International journal of cardiology*. 2018 Aug 7.
  8. Tutarel O, Alonso-Gonzalez R, Montanaro C, Schiff R, Uribarri A, Kempny A, Grübler MR, Uebing A, Swan L, Diller GP, Dimopoulos K. Infective endocarditis in adults with congenital heart disease remains a lethal disease. *Heart*. 2018 Jan 1;104(2):161-5.
  9. Papakonstantinou, Panteleimon E., George Samonis, Angeliki M. Andrianaki, Maria Christofaki, Dimitra Dimopoulou, John Papadakis, Achilleas Gikas, and Diamantis P. Kofteridis. "Epidemiology, Microbiological and Clinical Features, Treatment, and Outcomes of Infective Endocarditis in Crete, Greece." *Infection & chemotherapy* 50, no. 1 (2018): 21-28.
  10. Pericàs, J.M., Cervera, C., Moreno, A., Garcia-de-la-Mària, C., Almela, M., Falces, C., Quintana, E., Vidal, B., Llopis, J., Fuster, D. and Mestres, C.A., 2018. Outcome of *Enterococcus faecalis* infective endocarditis according to the length of antibiotic therapy: Preliminary data from a cohort of 78 patients. *PloS one*, 13(2), p.e0192387.
  11. García-Granja, Pablo Elpidio, Javier López, Isidre Vilacosta, Cristina Sarriá, Raquel Ladrón, Carmen Olmos, Carmen Saéz, Itziar Gómez, and J. Alberto San Román. "Surgery changes prognosis in infective endocarditis: The importance of post-surgical clinical evolution." *European journal of internal medicine* (2018).
  12. García-Granja, Pablo Elpidio, Javier López, Isidre Vilacosta, Cristina Sarriá, Raquel Ladrón, Carmen Olmos, Carmen Saéz, Itziar Gómez, and J. Alberto San Román. "Surgery changes prognosis in infective endocarditis: The importance of post-surgical clinical evolution." *European journal of internal medicine* (2018).
  13. Toru, Milkiyas, Getnet Beyene, Tesfaye Kassa, Zeleke Gizachew, Rawleigh Howe, and Biruk Yeshitila. "Prevalence and phenotypic characterization of *Enterococcus* species isolated from clinical samples of pediatric patients in Jimma University Specialized Hospital, south west Ethiopia." *BMC research notes* 11, no. 1 (2018): 281.
  14. Mangner N, Leontyev S, Woitek FJ, Kiefer P, Haussig S, Binner C, Mende M, Schlotter F, Stachel G, Höllriegel R, Hommel J. Cardiac Surgery Compared With Antibiotics Only in Patients Developing Infective Endocarditis After Transcatheter Aortic Valve Replacement. *Journal of the American Heart Association*. 2018 Sep 4;7(17):e010027.
  15. Bleibtreu, A., Jaureguiberry, S., Houhou, N., Boutolleau, D., Guillot, H., Vallois, D., Lucet, J.C., Robert, J., Mourvillier, B., Delemazure, J. and Jaspard, M., 2018. Clinical management of respiratory syndrome in patients hospitalized for suspected Middle East respiratory syndrome coronavirus infection in the Paris area from 2013 to 2016. *BMC infectious diseases*, 18(1), p.331.