CODEN [USA]: IAJPBB ISSN: 2349-7750

INDO AMERICAN JOURNAL OF
PHARMACEUTICAL SCIENCES

http://doi.org/10.5281/zenodo.3471669

**Available online at:** http://www.iajps.com *Research Article*

# MORPHOLOGIC CHANGES OF THE BRAIN TISSUE AFTER THE ADMINISTRATION OF IONIZED LIQUIDS WITH DIFFERENT OXIDATION-REDUCTION POTENTIAL DURING ANAPHYLACTIC SHOCK AND BRAIN ISCHEMIA.

**[1]I.V. Kovalenko, [2]V.I. Kharina, [3]K.M. Reznikov**

[1]Russia, 394062, 394036, Voronezh, Studencheskaya, 10; kovalenkoirin@gmail.com; +79518654523., [2]Russia, 394036, Voronezh, Studencheskaya, 10; vista.vrn@mail.ru; +74732531065., [3]Russia, 394036, Voronezh, Studencheskaya, 10; rkmp@yandex.ru; +74732531065.

**Article Received:** August 2019 **Accepted:** September 2019 **Published:** October 2019

**Abstract:**

*The purpose of the study: to study the impact of anolyte and catholyte on the structural changes of the brain tissue after their intravenous administration during anaphylactic shock and brain ischemia in laboratory animals. Methodology: anaphylactic shock was modelled at 40 laboratory rabbits by administration of horse serum of blood after 21-day sensitization of the animals. The test liquids (0.9% saline solution, prednisolone, anolyte, catholyte) were administered 20 minutes before the administration of the recall dose correspondingly to each of the 4 groups. Brain sampling for the morphologic analysis was conducted on the 7th day of the study. Experimental brain ischemia was modelled at 33 laboratory rabbits surgically - by the right common carotid (RCC) artery ligation. The agents under study (water for injections, anolyte, catholyte) were administered daily for 14 days correspondingly to each of the 3 groups. Sampling for the study was conducted on the 14th day of the experiment. The findings of the study showed the inexpediency of the catholyte intravenous use during anaphylactic shock. The anolyte intravenous use during anaphylactic shock does not affect adversely on the brain tissue. The morphologic analysis of the laboratory rabbits' brain tissue detected the reduction of adverse effects, which points at the antiallergic action of the test liquid. The water for injections and anolyte administration does not affect the building-up processes of severe destructive changes of the neurocytes of the brain cerebral hemispheres frontal cortex and hippocampus, having irreversible character, appearing after experimental brain ischemia (EBI) (the right common carotid artery ligation). According to the morphologic data, the adverse therapeutic outcome is possible after the administration of liquids with a big positive ORP (oxidation reduction potential) to the ischemic animals, which makes their use during BI (brain ischemia) inexpedient. It is found that the minimum brain tissue damage after ischemia out of all the experimental groups was detected at the group, in which catholyte was administered.*

**Keywords:** *anolyte, catholyte, oxidation reduction potential, anaphylactic shock, brain ischemia, morphology.*

**Corresponding author:**

**I.V. Kovalenko,**

*Russia, 394062, 394036, Voronezh, Studencheskaya, 10; kovalenkoirin@gmail.com; +79518654523.*

QR code

*Please cite this article in press I.V. Kovalenko et al.,* ***Morphologic Changes of the Brain Tissue after the Administration of Ionized Liquids with Different Oxidation-Reduction Potential during Anaphylactic Shock and Brain Ischemia.,*** *Indo Am. J. P. Sci, 2019; 06(10).*

## INTRODUCTION:

Water is known to be an indispensible part of all the living bodies. The body of an adult is made up of 60-70% water, the body of an elderly person - of 50-60%, the new-born baby - about of 80%, a 6-week embryo with an already formed skeleton and tissues - of 97% [1]. Until recently it was considered that water itself from the biochemical point of view is passive and mainly plays a role of a mechanical solvent and water filler, in which numerous active substances transformations take place [2]. Though, a certain amount of water in a living body can bind to substances dissolved in it and with the surface of the biopolymer molecules by the means of hydrogen and ion-dipole interaction force. It can lead to the property change of the membranes, ions and other particles located extra- and intracellularly [3]. Besides that, under the action of the water electric force, water molecules can hold by each other and form three-dimension structures, chains and coils, which allows the realization of proton conductivity [4]. Oxidation reduction potential (ORP) index characterizes the degree of electrons activity in the oxidation reduction reactions (the less its value is, the higher is the free electron concentration in the environment). ORP of a human's body internal environment measured on the platinum electrode relating to the silver-chloride electrode for the comparison is normally always beyond zero, i.e. has negative values that usually fall within the limits of minus 100 to minus 200 millivolts [5]. In the laboratory of FSBEI of Higher Education "Voronezh State Medical University named after N.N. Burdenko", it was shown that a liquid with ORP minus 500 mv makes the life of slipper animalcules longer, but hinders their growth on the early stages of their maturation [6]. Besides, it was experimentally proven that the ionized liquids with different ORP are effective during the treatment and prevention of anxiety and depressive disorder, schizophrenia [7] and other medical conditions [8]. As it is known from the references, the brain of an adult human is made up of 85% liquids [1], of a big interest is the study of the influence of liquids with different oxidation reduction potential on the structural changes of the brain during acute pathological conditions, like anaphylactic shock and brain ischemia.

## MATERIALS AND METHODS:

The studies were carried out in two stages. On the first stage for the study of ionized liquids with different ORP action on the brain tissue during immediate allergic reactions an experimental study on 40 Chinchilla rabbits of both sexes with the body mass of 2500-3500 gr was carried out. The animals were divided into 4 groups by 10 rabbits: The 1st one - control I group (isotonic sodium chloride solution was administered), the 2nd one - experimental A group (ionized liquid with a positive ORP (anolyte, ORP = +720±25 mv), 3rd one - experimental C group (ionized liquid with a negative ORP (catholyte, ORP = -500±50 mv), 4th one - experimental P group (prednisolone). Anaphylactic shock in rabbits was provoked by intravenous administration of horse serum of blood at the rate of 1 ml/kg after 21-day sensitization of the animals. 20 minutes before the recall dose administration, the test liquids were administered intravenous at the rate of 3 ml/kg. The total duration of the experiment was 36 days. On the 7th day brain sampling was carried out on the animals of each group for the morphologic analysis of the changes in the organ under study after the administration of synthesized ionized liquids with different ORP in conditions of the modelled anaphylactic shock.

On the second stage for the study of ionized liquids with different ORP action during brain ischemia, an experimental study was carried out on 33 rabbits. The experimental ischemia was modelled surgically - by the right common carotid (RCC) artery ligation [9]. Depending on the preparation under study, the animals were divided into three groups. The first group (11 rabbits) is the control one. As a control preparation, water for injections was used in the volume of 2ml/kg of the animal's body mass. In the second group (11 rabbits) the evaluation of a liquid with a negative ORP action was conducted (catholyte, ORP = -500±50 mv), in the dose of 2 ml/kg. In the 3rd group (11 rabbits) the evaluation of a liquid with a positive ORP action was conducted (anolyte, ORP = +720±25 mv), in the dose of 2 ml/kg. The test liquids were administered intramusculary in the thigh posterior surface, starting with the first day after the surgery, daily during 14 days at one and the same time.

With the aim of nerve cells and neuroglia damage rate, evaluation during cerebral ischemia, caused by RCC (right common carotid) artery ligation, as well as comparative analysis with the control group of the catholyte effect on the state of the brain nerve tissue after EBI, we conducted the morphologic examination of the brain cerebral cortex and hippocampus. Sampling for the study was conducted on the 14th day of the experiment.

The animals were decapitated under the ether anaesthesia. The brain after the extrication from the braincase was knifed in coronal slices 0.5 cm thick. The brain was fixed immersionally for 48 hours at room temperature by putting it into 10% formaline

solution, prepared on the phosphate buffer (pH 7.4). The fixed material was rinsed with water, passed over the increasing-concentration alcohols, two changes of chloroform and was embedded in paraffin. Out of paraffin blocks the slices 6-micrometer thick were made. For the survey, the slices were stained with Karazi's haematoxylin - eosin (during experimental anaphylactic shock). To visualize the morphologic changes of the nerve cells and neuroglia, the Nissl Toluidine histoneurologic blue stain was used (during experimental brain ischemia) [10]. The preparations were studied with the use of light microscopy in different magnifications. The study object was layers III and V of the brain cerebral hemispheres frontal cortex (cytoarchitectonic fields Fr1, Fr2) and cytoarchitectonic field CA3 of hippocampus. In the brain preparations the features of cyto- and angioarchitecture were evaluated. The analysis of the neurocytes morphologic changes was carried out in compliance with the classification [11], according to which the morphologic forms of borderline, alternative (destructive) and adaptive (compensatory-adaptive) variability were distinguished. The animals housing in vivarium and all the experimental procedures and protocols used for this study corresponded to the rules of laboratory practice in accordance with the guideline for experimental studies and the Order of the Ministry of Health and Social Development of Russia № 708N under date of 23.08.2010 "On approval of good laboratory practice regulations" (GLP), following international guidelines of European Convention for the Protection of Vertebrate Animals used for Experimental and other Scientific Purposes [ETSN 124, Strasbourg, 22.06.1998]. For experimentations, the requirements of the Commission on animals treatment ethics of Russian National Committee for Bioethics and ethical norms set out in "The International Recommendations for conducting the biological studies with the use of animals" (1989) were considered. The euthanasia of the animals was carried out under obligatory ether anaesthesia.

**The first study stage results:**

The observational light microscopy of the untreated rabbits' brain showed the neurons with no visible pathological changes with optically light cytoplasm, vessels with a normal blood content, whole ependyma. In the group of animals which did not receive treatment and died of anaphylactic shock, a perivascular and pericellular brain tissue edema was detected, the vessels were full-blooded with a sign of sludged red blood cells. There are subependimal small lesions of gliomatosis. The pia mater vessels had unequal congestion.

After the intravenous administration of the isotonic sodium chloride solution to the animals during anaphylactic shock on the 1st day of the study there was a perivascular and pericellular brain edema, the vessels were full-blooded with erythrostasis (figure 1A). The neurons were with a dark basophilic cytoplasm. The ependyma is whole everywhere. The pia mater is full-blooded, multicellular. The perivascular and pericellular brain edema remains on the 7th day of the study. The neurons were with an optically dark cytoplasm. In the depth of the grey matter there are gliosis lesions with a lymphocytes and histiocytes accumulation. The pia mater had an unequal congestion and an increased cellularity (figure 1B). The ependyma had an increased cellularity and proliferation lesions.

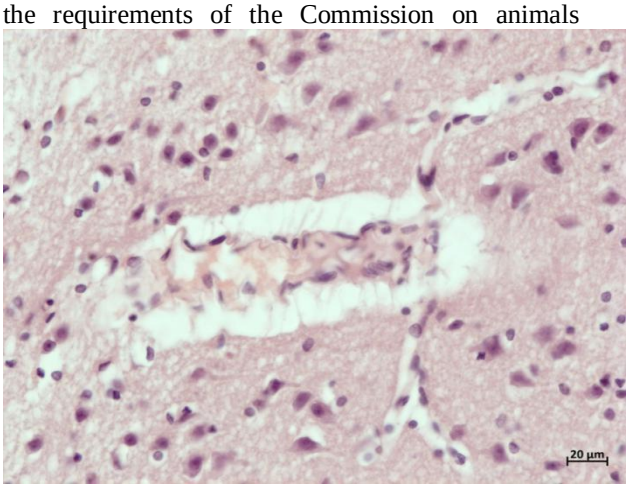


A

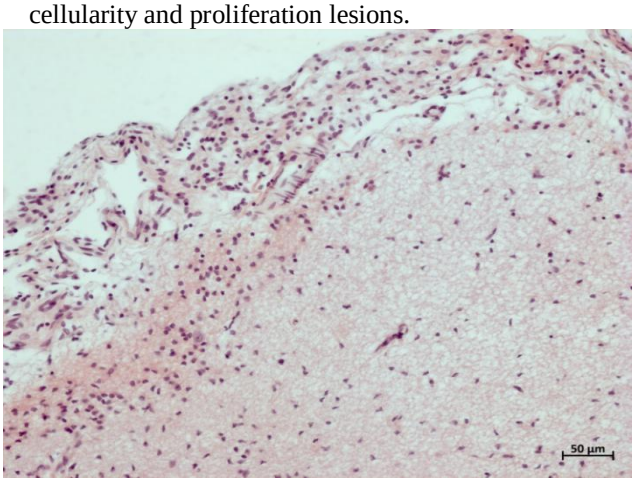


B

Figure 1 - Brain tissue condition of the rabbits after 0.9% sodium chloride solution administration during anaphylactic shock.
Note: stained with haematoxylin and eosin. A - day 1 of the study; approximation 200, B - day 7 of the study; approximation 50.

After the intravenous administration of the catholyte to the animals during anaphylactic shock on the 1st day of the study there was a perivascular and pericellular brain edema. The vessels are full-blooded with erythrostasis (figure 2A). The neurons were with an optically light cytoplasm. The pia mater vessels are enlarged and full-blooded. The perivascular and pericellular brain edema remains by the 7th day of the study, the vessels are full-blooded. The neurons had an optically dark cytoplasm and a big amount of Nissl substance, diffusely spread on all the cytoplasm surface and located along the cytoplasm periphery. In the periventricular there are small lesions of gliosis (figure 2B). The ependyma is whole everywhere.

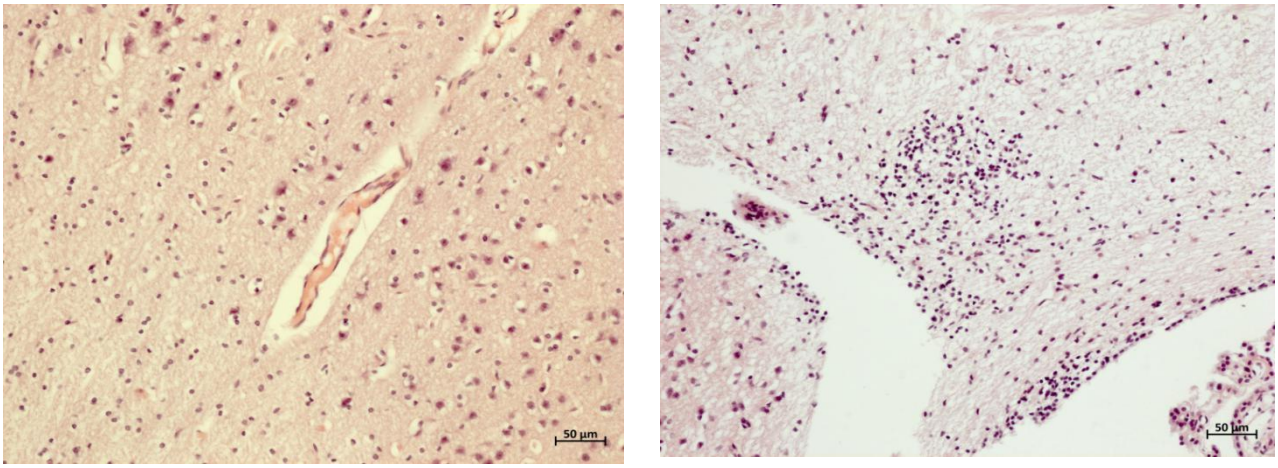


A B

Figure 2 - Brain tissue condition of the rabbits after ionized liquid with a negative ORP intravenous administration during anaphylactic shock.
Note: stained with haematoxylin and eosin. A - day 1 of the study; approximation 50, B - day 7 of the study; approximation 50.

After the intravenous administration of the anolyte to the animals during anaphylactic shock on the 1st day of the study there was a perivascular and pericellular brain edema, at some places the brain tissue has net structural pattern (figure 3A). The neurons had an optically dark cytoplasm and a big amount of Nissl substance, diffusely spread on all the cytoplasm surface. The vessels are full-blooded. The pia mater is multicellular. The perivascular and pericellular brain edema remains on the 7th day of the study. The pia mater vessels are full-blooded and enlarged. The neurons have no visible pathological changes. The pia mater is multicellular (figure 3B).

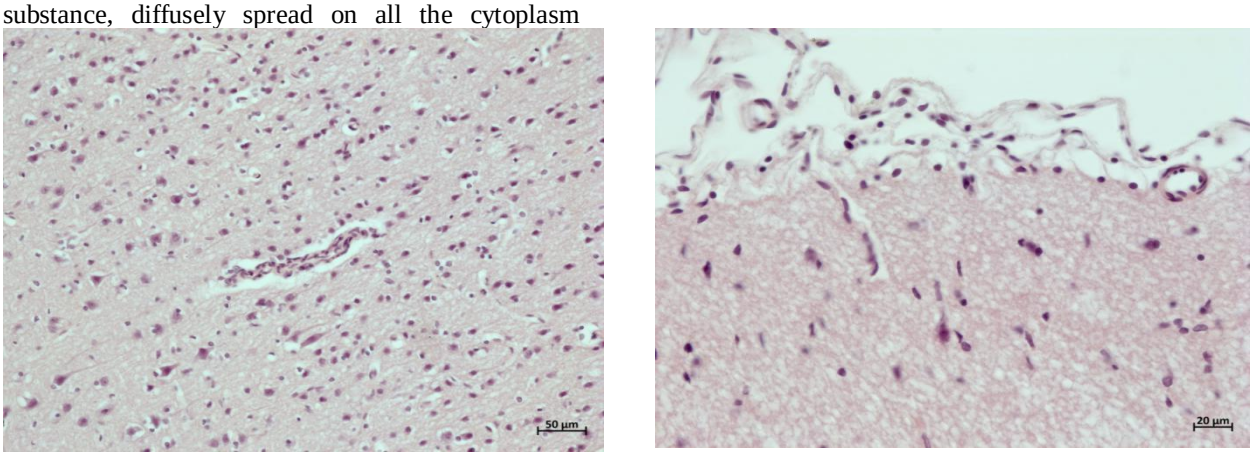


A B

Figure 3 - Brain tissue condition of the rabbits after ionized liquid with a positive ORP intravenous administration during anaphylactic shock.
Note: stained with haematoxylin and eosin. A - day 1 of the study; approximation 50, B - day 7 of the study; approximation 200.

**The second study stage results:**
At survey light microscopy of untreated rabbits' frontal cortex within the fields Fr1, Fr2, a distinct stratification of cortical formations is seen. In brain cortex layers III and V pyramidal neurons and glial cells are located in accordance with the cytoarchitecture of these areas. The CA3 hippocampus area constitutes a band-shaped accumulation of pyramidal cells located in two layers: a surface layer and a deep one. The pyramidal neurons bodies of the frontal cortex are located at a distance from each other; they are located more densely in layer III in comparison with layer V. The neurocytes of the CA3 hippocampus area are located more densely and are round-oval shaped. On the preparations stained with the Nissl method in the brain cortex areas under study in the neurons there is perikaryon, containing basophilic Nissl substance; the nucleus situated in the center has one, the hippocampus neurocytes in some cases have two. Basing on the neuroplasm tinctorial properties there were distinguished normo-, hypo- and hyperchromic neuron cells (figure 4). Among the neurons prevail normochromic cells with smooth sharp contours of nucleus and perikaryon. The nucleus is light, the nucleolus is basophilic, usually located in the center. The Nissl substance is distributed quite homogeneously, though in the axonal colliculi area, the cytoplasm lucent areas are seen.

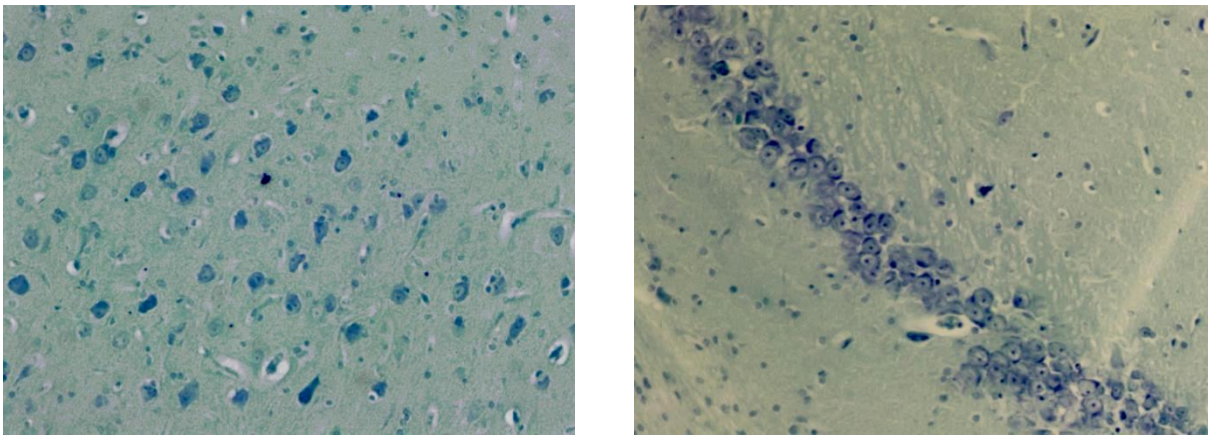

A B

Fig. 4. The neurons polymorphism of the frontal cortex (A) and hippocampus (B) of the untreated animals. Nissl stain method. Approximation 100.

The hypochromic neurons differ by the presence of several big chromatolysis lesions in cytoplasm and a lower level of chromatophilia in comparison with normochromic. The hyperchromic neuron cells have a more intense dark cytoplasm colour. The body and nucleus contours are smooth with a regular shape. In the nuclei of such cells there are bigger nucleoli which are located centrally. Besides the above stated neuron cells shapes there were singular pycnomorphic neurons. Such cells have an irregular shape of the cell body. The nucleus is shrunken with a severe hyperchromia and most often cannot be visualized. The pycnomorphic neuron cells in some cases have a coloured axon with a direct or a sulcated form. There is also a small amount of cell ghosts. They have an indistinct contour of the cell body and a various level of chromatophilia. The nucleus and nucleolus are not identified in them. Such a structure type represents fragments of destructively changed neurocytes.

Thus, in the brain cortex areas under study of the untreated animals there were neurocytes with various forms of physiological variability, representing different functional states of the neuron cells, as well as destructively changes neurons in the volume not exceeding the physiological destruction.

The study of the cerebral cortex structure of the animals that intramuscularly received water for injections showed the presence of necrotic neuron cells of a coagulative (pycnomorphic neurocytes) and a colliquative (cell ghosts) type (figure 5). In this group the destructive changes were expressed most intensively in comparison with the other experimental subgroups. In the layer III of the large hemispheres frontal cortex there was a significant reduction of the neurons number.

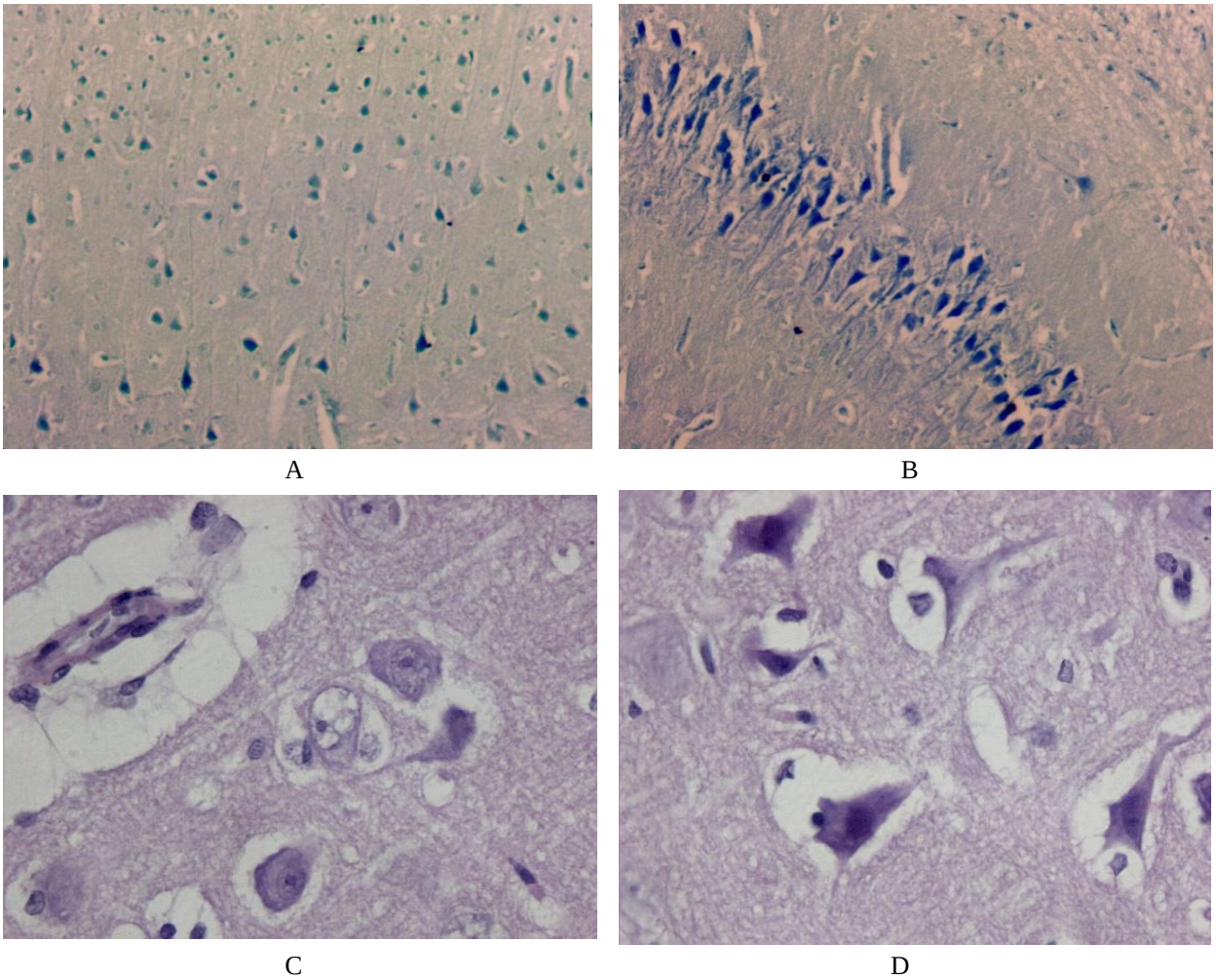


Fig. 5. The morphologic characteristic of the large hemispheres frontal cortex (A, C, D) and hippocampus (B) at water for injections administration to the animals with EBI during 14 days. Nissl stain method. A - approximation 100. B - approximation 100. C - approximation 630. D - approximation 630.

Among the whole neurocytes there was a significant number of burned-out cells mostly of hypochromic type, which was characterized by cytoplasm vacuolization, focal lysis of the Nills substance, the displacement of the nuclei in a distal direction. There were plenty of cell ghosts in the hippocampus. There were expressed pericellular and perivascular brain edema. In microcirculation vessels there were scattered rouleaus. During ischemia the number of perineuronal glia with the evidence of satellitosis increased. The microglia activation caused its replacement in the area of the neuronecrosis, its accumulation around the cell debris with the development of the neuronophagy. In the brain microcirculation vessels there were signs of stasis and a complete bloodflow shutdown.

Thus, without medication administration the processes of expressed destructive changes formations of the frontal cortex and hippocampus neurocytes have an irreversible character, appearing after the EBI modelling (the right common carotid artery ligation).

At a constant catholyte administration after the right common carotid artery ligation and EBI modelling, the observable morphofunctional changes were consistent with the control group rates, though the level of the dystrophic changes was higher in comparison with the Cortexin group (EBI modelling) (figure 6). There were cortex areas with a reduced after cytolysis density of neurocytes. There was a pycnomorphic neurocytes increase and cell ghosts with neuronophagy, the signs of perivascular and pericellular brain edema.

Thus, the catholyte administration did not have a visible neuroprotective effect. Though for a definitive and objective conclusion additional studies are needed.

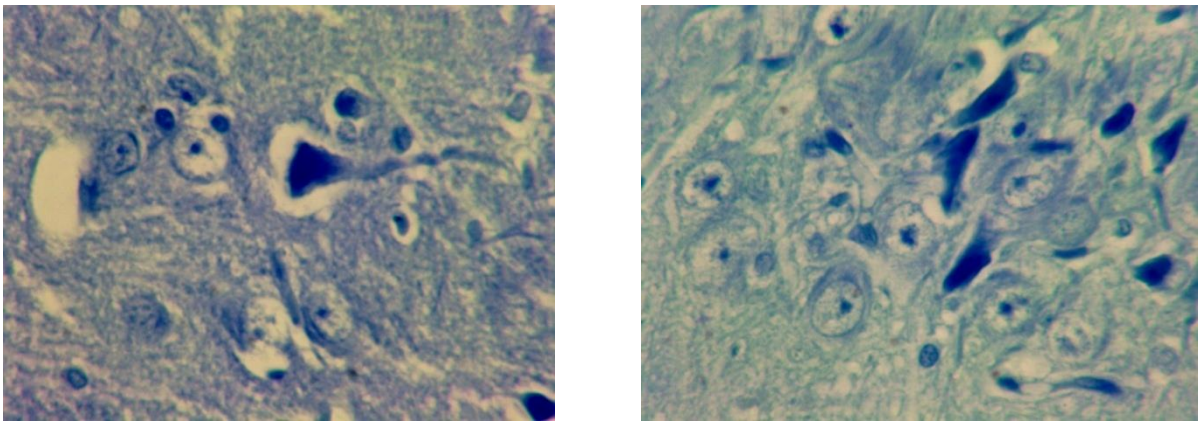

A B

Fig. 6. The morphologic characteristic of the large hemispheres frontal cortex (A) and hippocampus (B) at catholyte administration to the animals with EBI during 14 days. Nissl stain method. Approximation 400.

In the group of animals receiving anolyte, the morphofunctional changes are mostly similar to those that the animals administered with water for injections had. In the cortex and hippocampus there were loci with a reduced neuronal density, dystrophic and degenerative neurocytes changes in the form of hyperchromatism and pycnosis of the nucleus with perikaryon, cytoplasm vacuolization and an eccentic location of the nucleus, cell ghosts formation, neuronophagy, expressed pericellular and perivascular brain edema (figure 7).

Thus, anolyte administration does not affect the building-up processes of severe destructive changes of the neurocytes of the brain cerebral hemispheres frontal cortex and hippocampus, having an irreversible character, appearing after the EBI modelling (the right common carotid artery ligation).

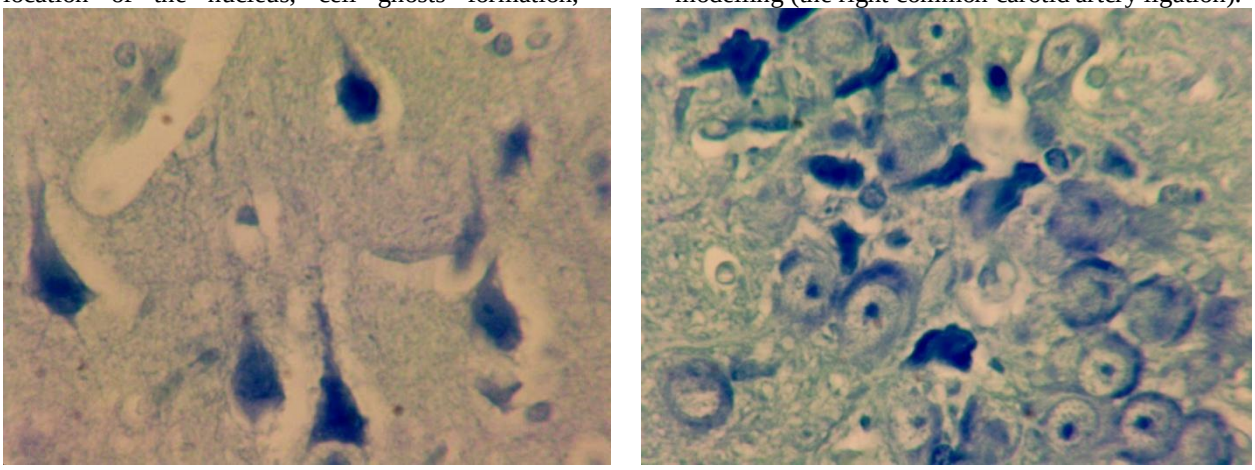

A B

Fig. 7. The state of the large hemispheres frontal cortex (A) and hippocampus (B) at anolyte administration to the animals with EBI during 14 days. Nissl stain method. Approximation 400.

## RESULTS DISCUSSION:

Quite often during allergic shock brain damage takes place, which requires urgent measures, including the intravenous medication administration [12]. The intravenous administration of the liquid with different ORP during allergic reactions of immediate type was studied on the experimental model of anaphylactic shock in laboratory rabbits. The findings of the study showed the inexpediency of the catholyte intravenous use during anaphylactic shock. It can be associated with the immunotropic effect of the liquid under study: stimulating the immune response, catholyte

worsens the onset of the allergic reaction of immediate type. The anolyte intravenous use during anaphylactic shock does not affect adversely. The morphologic analysis of the laboratory rabbits' brain tissue detected the reduction of adverse effects, which points at the antiallergic action of the test liquid. Possibly, entering the body, anolyte increases the oxidation reduction potential of the intercellular fluid, which leads to mast cell membrane stabilization and slowing down of the allergy mediators release. Besides, in the intercellular fluid there are H1-receptors and altering the physical-chemical properties of this liquid affects their activity. Possibly, altering the oxidation reduction potential of the intercellular fluid, the ionized liquid with a positive ORP reduces the H1-receptors activity. As analyte is an oxidizing agent, it can reinforce the process of histamine oxidation, and therefore accelerate the process of its transition to the resting state.

On the second stage the morphologic study of cerebral cortex and hippocampus was carried out, the main aim of the study was to detect the neuronal damage rate during cerebral ischemia, caused by RCC (right common carotid) artery ligation, as well as comparative analysis of liquids with different ORP effect on the brain nerve tissue after EBI. The observable morpho functional changes of the neuron cells were homogeneous and showed various rate of the dystrophic and necrotic changes of hypoxic-ischemic type. The most significant neuron morpho functional changes were detected in the subgroups of the animals that received water for injections and anolyte during EBI modelling. It was the prevalence of the morphologic forms of the neurons destructive variability. Such neurons reactions on hypoxia and ischemia are considered to be nonspecific and mostly irreversible [13, 14]. Similar changes can be explained by the fact, that water for injections has a positive ORP = +300mV, and anolyte = + 720mV.

Thus, the water for injections and anolyte administration do no affect the formation processes of the expressed destructive changes of the frontal cortex and hyppocampus neurocytes, which are irreversible and take place after EBI modelling (the right common carotid artery ligation). According to the morphologic data, the adverse therapeutic outcome is possible after the administration of liquids with a big positive ORP to the ischemic animals, which makes their use during brain ischemia inexpedient.

In accordance with the conducted morphologic analysis, it is found that the minimum brain tissue damage after ischemia out of all the experimental groups was detected at the group, in which catholyte was administered. Though, during the catholyte consistent administration there were cortex areas with a reduced after cytolysis density of neurocytes. There was a pycnomorphic neurocytes increase and cell ghosts with neuronophagy, the signs of perivascular and pericellular brain edema. Thus, the catholyte administration did not have a visible neuroprotective effect.

## CONCLUSIONS:

1. During allergic reactions of immediate type intravenous catholyte administration causes the reinforcement of the brain tissue dystrophic changes in comparison with the brain samples of the animals from the control groups.
2. Intravenous anolyte administration reduces the expression of the brain tissue dystrophic changes during anaphylactic shock.
3. The morphological pattern during EBI modelling after water for injections and anolyte administration is prognostically adverse, the dystrophic changes in these groups were evident significantly more often and higher than in the animals of other groups.
4. During morphologic study catholyte scarecely has any visible neuroprotective effect.

## REFERENCES:

1. Farashchuk N.F. Water is a structural framework for adaptation / N.F. Farashchuk, Y.A. Rakhmanin. - Moscow ; Smolensk, 2004. - 180 p.
2. Bulenkov N.A. On a possible role of hydration as a leading integration pattern in the organism of biosystems on different levels of their hierarchy / N.A. Bulenkov // Biophisica (Biophysics). – 1991. – Vol.36, №2. – P.181-243.
3. Ion is a water crystal association / A.A. Stekhin [et al.] // Electrochemical activation : abstract and brief reports of the second international symposium Moscow, 1999. – P.106-112.
4. Smith S. Electromagnetic bioinformation and water / S. Smith // Vestnik biofizicheskoy meditsiny (Biophysical Medicine Bulletin). – 1994. – № 1. – P. 3-13.
5. Ashbakh D. Alive and dead water is a brand new medicine of today / D. Ashbakh – Saint Petersburg : Piter, 2008. – 160 p.
6. Reznikov K.M. The action of the liquids with different oxidation reduction potentials on the central nervous system : monography / K.M. Reznikov, E.B. Sabitova, O.Y. Shiryayev; under the editorship of I.E. Yesaulenko. – Voronezh :

Nauchnaya kniga (Scientific book), 2012. - 279 p.
7. The comparative analysis of different ways to overcome the non-response to medicamentous therapy in case of schizophrenia / E.A. Gamburg [et al.] // Sistemnyy analiz i upravleniye v biomeditsinskikh sistemakh (Systems analysis and management in biomedical systems). – 2013. – Vol. 12, № 2. – P. 430-435.
8. The role of water segment in its life-sustaining activity processes / under the editorship of K.M. Reznikov. – Voronezh : Publishing house BGMA, 2014. – 249 p.
9. Tupikova, T. V. The experimentally acquired hypertonia obtained by the brain blood supply limitation at rabbits [Text] / T. V. Tupikova // Cardiology. – 1963. – № 3. – P. 14–21.
10. Sarkisov, D.S. Microscopic equipment (guidance for doctors and laboratory assistants) [Text] / D. S. Sarkisov, Y. L. Perov. – M.: Meditsina (Medical science), 1996. – 543 p.
11. Fedorov, V. P. Ecological neuromorphology. The classification of typical forms of CNS morphologic variability under the influence of anthropogenic factors [Text] / V. P. Fedorov, A. V. Petrov, N.A. Stepanyan // Zhurnal teoreticheskoy i prakticheskoy meditsiny (The Journal of theoretical and practical medicine). – 2003. – Vol. 1, № 1. – P. 62–66.
12. Yemel'yanov A.V. Anaphylactic shock: handbook for doctors / A.V. Yemel'yanov. – Saint Petersburg, 2001. – 24 p.
13. Bogolepov, N. N. Brain ultrastructure during hypoxia [Text] / N. N. Bogolepov. – M. : Meditsina (Medical science), 1979. – 167 p
14. Semchenko, V. V. Postanoxic Encephalopathy [Text] / V. V. Semchenko, V. V. Stepanov, G. R. Alekseyeva. – Omsk, 1999. – 448 p.