CODEN [USA]: IAJPBB ISSN : 2349-7750

INDO AMERICAN JOURNAL OF
PHARMACEUTICAL SCIENCES
SJIF Impact Factor: 7.187
http://doi.org/10.5281/zenodo.4161670

Available online at: http://www.iajps.com *Research Article*

A COMPARATIVE STUDY OF MANDIBULAR ASYMMETRY BETWEEN NORMAL SUBJECTS AND CLEFT LIP PALATE

Dr. Sana Sattar, Dr. Murk Dodani, Dr. Hira Laghari
Bibi Aseefa Dental College Larkana

Article Received: August 2020 **Accepted:** September 2020 **Published:** October 2020

Abstract:
AIM: *The aim of the study was to compare the vertical asymmetry of the mandible between a cleft lip palate and normal class I occlusion subjects.*
Place And Duration: *This study was held in the Orthodontics Department of Chandka Medical College Hospital, Larkana for one-year duration from April 2019 to April 2020.*
Methodology: *The sample for this study consisted of a total of 64 patients divided into two groups: Group 1 consisted of 32 patients with a repaired cleft lip and palate without complex symptoms [further subdivided into: 16 with complete unilateral and 16 with complete bilateral cleft lip and palate]. Group 2 consisted of 32 people. with normal facial morphology and class, I occlusion. Both groups included men and women aged 14 to 16 years [mean age in the cleft group 14.6 years ± 0.73 years and normal group 14.8 years ± 0.73 years]. The index of mandibular asymmetry [condylar, ramal, condylar plus ramal] and the measurements of the gonial angle were computed on a panoramic radiograph.*
Results: *Calculated descriptive statistical measurements between healthy subjects and the cleft lip-palate group showed statistically significant differences in both the condylar and ramal asymmetry index, but in the overall group comparison of the condyle and the fracture height asymmetry index did not show any significant result.*
Conclusion: *In patients with cleft lip and palate the mandible was found to be in proper condition. However, in the unilateral cleft lip and palate, there was a difference in the condylar, ramal and gonial angles between the cleft and non-cleft sides.*
Keywords: *mandible asymmetry, unilateral cleft lip and palate, bilateral cleft lip and palate.*

Corresponding author:
Dr. Sana Sattar,
Bibi Aseefa Dental College Larkana

QR code

Please cite this article in press Sana Sattar et al, ***A Comparative Study Of Mandibular Asymmetry Between Normal Subjects And Cleft Lip Palate.,*** *Indo Am. J. P. Sci, 2020; 07(10).*

INTRODUCTION:

Craniofacial anomalies are a diverse group of deformities associated with the development of the head and neck. Their etiology exhibits complexities such as apert syndrome, Crouzon syndrome, etc. All are either entirely genetic in origin, while some are due to teratogenic influences or may be associated with other developmental anomalies including cleft lip and palate[1-2]. Their course of subordinated growth causes craniofacial features which are significantly different from normal and most often presented as craniofacial asymmetry. Asymmetry refers to differences in size, shape, or relative symmetry between the right and left sides[3-4]. It can affect any part of the human body or the whole thing. In the case of the facial skeleton, there is a slight difference between the right and left side, which is considered normal and usually goes unnoticed, but the deviation from clear proportionality is of great aesthetic, anatomical and physiological importance[5-6]. The data examined showed slight asymmetries with the right half curve wider than the left side with the accompanying left tilted chin. On the face, jaw asymmetries are most often observed, the causes of which are divided into four main groups: developmental, traumatic, pathological and functional. 5% in the upper part of the face, 36% in the middle third and, according to Profit and Severt descriptive data, 74% in the lower third. Cleft lip and palate are clinically manifested, usually as midfacial deficiency, back cross bite with a Class III molar. There are conflicting indications available regarding the asymmetry of the mandible associated with cleft lip and palate. Morphological differences consistently coexist between unilateral and bilateral cleft lip and palate; in the case of bilateral cleft lip and palate, due to the forward shift of the premaxillary jaw, there is no shortening of the total depth of the upper jaw, which, on the contrary, was found positively in unilateral cleft lip and palate due to the pronounced movement of the jaw backwards, it shows a retraction of the jaw[6-7]. The total length of the face is increased in the bilateral cleft lip and palate with a greater backward rotation. It was also investigated that the condyle height turned out to be significant ($p < 0.05$) in this group, which was later discussed as a significant factor related to the symmetrical posterior vertical height of the mandible. Due to the increased mandibular retraction, the bony profile of the bilateral cleft lip and palate is not flattened compared to the unilateral cleft lip. It is also associated with increased pre-maxillary protrusion. In the case of a bilateral cleft lip and palate, the upper incisors are more recessed compared to a unilateral cleft lip and palate[5-7]. In general, the unilateral cleft lip and palate showed asymmetry more on the cleft side than on the non-cleft side. According to data from the international perinatal database of common oral clefts, the overall incidence of cleft lips with or without cleft palate is 9.92 per 10,000 live births. It includes a cleft lip 3.28 out of 10,000. The left lip and palate were found to be 6.64 out of 10,000, 76.8% were isolated, 15.9% had systemic malformations, and 7.3% were associated with syndromes[8]. The left lip and palate unrelated to any syndromic symptoms are caused by an inborn combination of genetic and environmental factors. This is referred to as multi-factorial. A developing embryo inherits genes that increase the risk of cleft lip and / or palate; such genes later develop into a cleft when exposed to certain environmental factors. In Pakistan, the incidence of cleft lip and palate is 1 in 523 deliveries, of which cleft lip is 42%, cleft palate 24%, and cleft lip and combined palate 34%. Boys predominate with a cleft lip and connect the lip / palate, while girls predominate with a cleft palate only6. Overall, the reported cases in our hospital included patients from different regions of the country with different severity of clefts, both syndromic and non-syndromic[9-10]. Due to the variability in height both between unilateral and bilateral clefts of the lip and palate, there is a constant chance of asymmetry. Facial asymmetry is particularly evident in the lower part of the facial skeleton, where mandibular anatomy, morphology and positioning in three-dimensional planes play a key role, which later significantly influence treatment planning, decisions, and treatment outcomes, including orthognathic surgery. Therefore, our main goal is to compare the vertical asymmetry of the mandible between a cleft lip and healthy individuals.

METHODOLOGY:

This study was held in the Orthodontics Department of Chandka Medical College Hospital, Larkana for one-year duration from April 2019 to April 2020. The sample for this study included a total of 64 people. The people were divided into two groups: Group 1 consisted of 32 people with a repaired cleft lip and palate [16 with a total unilateral cleft and 16 with a complete bilateral cleft lip and palate]. Group 2 consisted of 32 people with normal facial morphology and class I occlusion (both men and women). consent was obtained from all patients. The inclusion criterion for the cleft lip and palate group was people without a team of patients, regardless of gender, with repaired unilateral or bilateral cleft lip and palate. Exclusion criteria included cleft lip and palate with systemic diseases, incompletely repaired palate, open fistulas, developmental or acquired deformities of the craniofacial muscles, autoimmune diseases, syndromes, endocrine disorders,

neurological problems, any history of orthodontic treatment, and signs and symptoms and disorders. Inclusion criteria for normal class I subjects included skeletal primary class I [ANB = 2 ° ± 2 °, SNA = 82 ° ± 2 °, SNB = 78 ° ± 2 °], permanent dentition with molars according to Angle I classification belonging to both genders. Exclusion criteria included significant medical history, history of injuries or any previous treatment and surgery, retained, missing teeth, affected periodontal teeth, division into molars, skeletal base II and III with class I molars. Mandibular asymmetry index [condylar, ramal, condylar plus ramal] and the measurements of the gonial angle were computed from a panoramic dental radiograph presented by Habets et al. (Fig. 1).

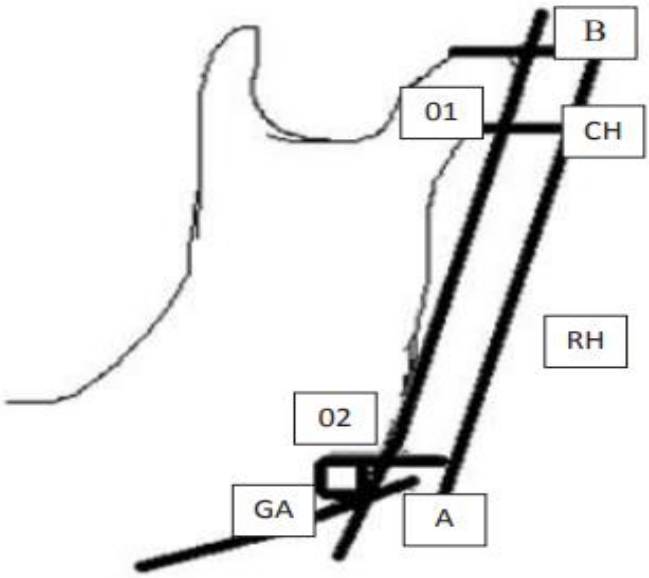

Both right and left condyles and ramus are drawn on cephalometric sheets of lead acetate from OPG. The land markings were identified as Aline joining the most lateral condyle point of image 01 and the ascending frame denoted as image 02.]. The tangent of the arm was taken from the highest point of the condyle image. A perpendicular line was drawn from the tangent above called line B. The height of the condyle [CH] was measured from line B on Alina to point 01. The gonial angle [GA] was measured as the angle formed by the tangent lines to the posterior shoulder and the lower jaw boundary. The value of asymmetry indices calculated above 3% was indicated as actual posterior vertical asymmetry of the mandible. The asymmetry indices were calculated according to the following formula: For the condyle asymmetry index: [(CHRIGHT-CHLEFT) / CHRIGHT + CHLEFT)] X100 For the arm asymmetry index: [(RHRIGHT-RHLEFT) / RHRIGHT + RHLEFT)] X100 For Condylar + Ramal Asymmetry Index: [(CO + RH) RIGHT- (CO + RH) LEFT) / (CO + RH) LEFT) / (CO + RH) LEFT) / (CO + RH) LEFT) / (CO + RH) RIGHT + (CO + RH) LEFT)] X100. For the reliability of the assessment, care was taken to position the head to avoid measurement errors in the vertical and at an angle, which means the limit of positioning the head in all directions, including the occlusal plane not tilted by more than 10 degrees. Statistical analysis was performed using SPSS for Windows version 16. ANOVA and the Mann-Whitney U test was used to calculate the intergroup comparison. Student's t-pair test was used to calculate the differences between the cleft and non-cleft sides in the unilateral cleft lip group. All statistical analyzes were calculated at the 95% confidence level with a significant P value <001.

RESULTS:

The computed descriptive statistical measurements between normal occlusion and cleft lip and palate show significant differences (P <0.001) in both the condylar and humeral asymmetry indexes, but compared to all comparative groups for condyle and arm height asymmetry, the index showed no significant result (P <0.05). In the case of unilateral cleft lip and palate, both shoulder height and palate angle on the cleft side were found to be statistically significant (P <0.001). The statistical measurement shows no significant difference for the sex. The results are also presented in Tables I, II and III below, respectively:

TABLE I: ANOVA SHOWS MEAN DIFFERENCE OF MANDIBULAR ASYMMETRY INDEX BETWEEN NORMAL AND CLEFT LIP AND PALATE GROUP:

	NORMAL		CLEFT		
MEASUREMENT	MEAN[mm]	SD±[mm]	MEAN[mm]	SD±[mm]	SIG.VALUE[p]
Condylar	10.0	.87	7.4	1.4	<0.001
Ramal	2.2	.98	5.1	.52	<0.001
Condylar+Ramal	3.8	.52	4.4	1.5	.067*
Gonial Angle(degree)	120°	1.3°	124°	14.5°	.18*

**P* value>.05 is insignificant for both condylar plus ramal and gonial angle between cleft and normal group.

TABLE II: MANN -WHITNEY U TEST-SHOWS MEAN DIFFERENCE OF MANDIBULAR ASYMMETRY INDEX BETWEEN NORMAL AND CLEFT LIP AND PALATE GROUP:

MEASUREMENT	MEAN[mm]	SD±[mm]	SIG.VALUE[p]
Condylar	8.7	1.7	<0.001
Ramal	3.6	1.6	<0.001
Condylar + Ramal Height	4.1	1.1	.3*
Gonial Angle(degree)	122°	10.4°	.5*

P value<.001 is significant.

**P* value>.05 is insignificant for both condylar plus ramal and gonial angle between cleft and normal group.

TABLE III: T-TEST SHOWS MEAN DIFFERENCE OF MANDIBULAR ASYMMETRY INDEX AMONG UNILATERAL CLEFT LIP AND PALATE GROUP:

MEASUREMENT	MEAN[mm] Non cleft side	SD±[mm]	MEAN[mm] Cleft side	SD±[mm]	SIG.VALUE[p]
Condylar Height	6.3	.87	6.6	1.2	.1
Ramal Height	4.1	.23	4.9	.38	<0.001*
Gonial Angle(degree)	122°	.89°	139°	.73°	<0.001*

**P* value<.001 is significant for both ramal height and gonial angle between cleft and non cleft side among unilateral cleft lip and palate group.

DISCUSSION:

The symmetry in the morphology of the mandible is the key to an aesthetic that connects to the entire face both in terms of aesthetics and development. , et al., Smahel and Mullerova, et al. Worldwide data on mandibular asymmetry in unilateral and bilateral clefts of the lip and palate are limited. The mandibular asymmetry in unilateral and bilateral cleft

lip is incompatible with the type of cleft. Developmental growth studies show variability with respect to craniofacial development due to differences in patterns, timing, and variability factors. Genetic influences span the entire period, making them unpredictable. This result describes a physiologically closed adaptive mechanism[11]. The lower jaw makes up 95% of the lower part of the facial skeleton. The lower face is also influenced by the developmental influences of the base of the skull and the temporal fossa. Ishiguro et al. And Athanasiou et al. described in their study an increase in the width of the lower jaw. This, in turn, turned out to be directly related to the fossa of the mandible, making them directly proportional to each other. Also, Bjork, Skieller et al. The developmental effects of cranial base displacement, gonial fossa remodeling, and growth-related condylar-ramal displacement have been extensively discussed[12]. Melnick et al., Investigated the difference between a cleft and no cleavage in a longitudinal growth study and found no more than 0.5 mm difference. Our study shows that overall, the mean difference in condyle height plus the frame growth rate does not exceed 3%. The asymmetry indices should be greater than 3% to be defined as true posterior vertical asymmetry of the mandible. It has been reported variously that wing muscle injury due to surgery, jaw growth retardation and functional changes have a major influence on mandibular growth. But later it turned out that it had no effect. Omar et al. In their comparative study of 204 patients, including total unilateral cleft lip, total unilateral lip and sockets, and isolated palate, did not report any statistically significant changes associated with mandibular growth. Panoramic dental imaging remains a method for assessing the asymmetry of the mandible, as explained by Habets et al., Miller and Smidt, Kurt et al., And Uysal et al. a factor found in the asymmetry of the mandible and lower face (P.05) between the non-cleft group and the cleft. Our study also shows similar findings in this regard. In total, both anomalies of the base of the skull and the temporal region can affect the asymmetry of the skeleton of the lower face. A descriptive study by Kurt et al. Showed only a difference in the height of the condyles, which was statistically significant ($P < 0.05$) in the group with bilateral cleft lip. This may suggest variability in the displacement of one condylar-ramal unit with a distinct developmental pattern of both bone and muscle in the bilateral cleft lip and palate group.

CONCLUSION:

Mandible in both non syndromic unilateral and bilateral cleft lip/palate subjects was found to be similar to normal subjects. However, there was a difference in condyle, ramus and gonial angle between cleft and noncleft side in unilateral cleft lip and palate subjects.

REFERENCES:

1. Moungkhom, Priyawati, Amit Nagar, Pradeep Tandon, Gulshan Kumar Singh, Alka Singh, Ranjit Kumar Patil, and Veerendra Prasad. "Three-dimensional assessment of craniofacial parameters in subjects with cleft lip and palate: A cone-beam computed tomography study." *Journal of Cleft Lip Palate and Craniofacial Anomalies* 7, no. 2 (2020): 99.
2. Shrestha, Abhishekhi, Masahiro Takahashi, Tetsutaro Yamaguchi, Mohamed Adel, Mayu Furuhata, Yu Hikita, Hiroshi Yoshida, Takatoshi Nakawaki, and Koutaro Maki. "Three-dimensional evaluation of mandibular volume in patients with cleft lip and palate during the deciduous dentition period." *The Angle Orthodontist* 90, no. 1 (2020): 85-91.
3. Fang, Xiaoxu, Cunhui Fan, Chunmiao Jiang, Qing Xue, Wenlin Xiao, Xu Tao, Zhonghui Tian, and Xiaolin Xu. "Relationship between dental calcification of mandibular teeth and cervical vertebrae maturity in patients with unilateral complete cleft lip and palate." *Oral radiology* (2020).
4. Maspero, Cinzia, Marco Farronato, Francesca Bellincioni, Davide Cavagnetto, and Andrea Abate. "Assessing mandibular body changes in growing subjects: A comparison of CBCT and reconstructed lateral cephalogram measurements." *Scientific Reports* 10, no. 1 (2020): 1-12.
5. Kochhar, Anuraj Singh, Maninder Singh Sidhu, Mona Prabhakar, Ritasha Bhasin, Gulsheen Kaur Kochhar, Himanshu Dadlani, and Gianrico Spagnuolo. "Frontal and Axial Evaluation of Craniofacial Morphology in Repaired Unilateral Cleft Lip and Palate Patients Utilizing Cone Beam Computed Tomography; An Observational Study." *International Journal of Environmental Research and Public Health* 17, no. 21 (2020): 7786.
6. Bindayel, Naif A., Maan Alsultan, S. E. Hayek, and Khalid Almoammer. "Comparison between Chronological Age and Dental Ages of Saudi Patients with Cleft Lip and Palate." *The journal of contemporary dental practice* 20, no. 5 (2019): 604.
7. Szyszka-Sommerfeld, Liliana, Agata Budzyńska, Mariusz Lipski, Sławomir Kulesza, and Krzysztof Woźniak. "Assessment of Masticatory Muscle Function in Patients with Bilateral Complete Cleft Lip and Palate and Posterior

Crossbite by means of Electromyography." *Journal of Healthcare Engineering* 2020 (2020).

8. Liberton, Denise K., Payal Verma, Konstantinia Almpani, Peter W. Fung, Rashmi Mishra, Snehlata Oberoi, Figen Ç. Şenel et al. "Craniofacial Analysis May Indicate Co-Occurrence of Skeletal Malocclusions and Associated Risks in Development of Cleft Lip and Palate." *Journal of Developmental Biology* 8, no. 1 (2020): 2.
9. Lemes, Christian Reis, Carolina Fernandes Tozzi, Saulo Gribel, Bruno Frazão Gribel, Giovana Cherubini Venezian, Caroline do Carmo Menezes, and William Custodio. "Mandibular ramus height and condyle distance asymmetries in individuals with different facial growth patterns: a cone-beam computed tomography study." *Surgical and Radiologic Anatomy* (2020): 1-8.
10. Cesur, Emre, Can Arslan, Aslı Patır Münevveroğlu, and Ayşe Tuba Altuğ. "Evaluation of Dental Age in Individuals of Different Ages with Unilateral Cleft Lip and Palate." (2020).
11. Fan, Wei, Deguo Gao, Yuting Wang, Yutong Chen, Yusheng Li, Shijun Lu, and Zhendong Wang. "Three-dimensional measurement and analysis of mandibular characteristics in subjects with impacted mandibular second molars." *Orthodontics & Craniofacial Research* (2020).
12. Van Dyck, Julie, Giacomo Begnoni, Guy Willems, Annouschka Laenen, Patrick Thevissen, Anna Verdonck, and Maria Cadenas de Llano-Pérula. "Dental development in patients with and without unilateral cleft lip and palate (UCLP): a case control study." *Clinical Oral Investigations* (2020): 1-13.
13. Awuti, Shataer, Yuka I. Sumita, Mahmoud Elbashti, Shajidan Kelimu, Amel Aswehlee, and Mariko Hattori. "The role of non-contact digitizer in geometrical evaluation of mandibular prostheses effect on facial asymmetry of mandibulectomy patients." *Journal of Prosthodontic Research* (2020): JPOR_2019_326.
14. Khanna, Rohit, Tripti Tikku, Sneh Lata Verma, Geeta Verma, and Saumil Dwivedi. "Comparison of maxillofacial growth characteristics in patients with and without cleft lip and palate." *Journal of Cleft Lip Palate and Craniofacial Anomalies* 7, no. 1 (2020): 30.
15. Idrys, Akram, Beste Kamiloğlu, and Ayşe Tuba Altuğ. "A multicenter retrospective 3D study of cleft lip and palate casts to evaluate dental shape, size, and anomalies in eruption around the cleft area before fixed orthodontic treatment." *Journal of Nanoparticle Research* 22, no. 8 (2020): 1-12.