CODEN [USA]: IAJPBB ISSN : 2349-7750

INDO AMERICAN JOURNAL OF
PHARMACEUTICAL SCIENCES
SJIF Impact Factor: 7.187
http://doi.org/10.5281/zenodo.4076866

Available online at: http://www.iajps.com *Research Article*

EFFICACY OF HRCT IN IDENTIFYING ACTIVE PULMONARY TUBERCULOSIS

[1]Dr Muhammad Afaq Saleem, [2]Dr Yasin Ashiq, [3]Dr Mahnoor Amjad
[1]Allama Iqbal Medical College, Lahore
[2]I.K Akhunbaev Kyrgyz State Medical Academy Kyrgyzstan
[3]DG Khan Medical College, DG Khan

Article Received: August 2020 **Accepted:** September 2020 **Published:** October 2020

Abstract:
Introduction - *The aim of the study is to show the role of high-resolution computed tomography (HRCT) in the diagnosis of active pulmonary tuberculosis. The appearance of tree buds in HRCT is more sensitive than chest X-ray in detecting early endobronchial spread, 97% of patients with active pulmonary tuberculosis had evidence of bronchogenic spread in HRCT.*
Place and Duration: *In the Department of Radiology, Jinnah Hospital Lahore for one-year duration from April 2019 to April 2020.*
Materials and methods. *One hundred patients with clinically suspected active pulmonary tuberculosis with chest X-rays suggestive of disease were subjected to HRCT.*
Results - *HRCT results showed that 76 patients had active pulmonary tuberculosis, and further clinical studies showed that the definitive diagnosis of the disease was confirmed in 52 patients. According to the binomial test, the combination of the two main symptoms of HRCT, the median-lobular nodule and the symptoms of "tree in embryo" accurately confirms the diagnosis of tuberculosis. The sensitivity of HRCT in the diagnosis of active pulmonary tuberculosis in this study was 96%, and the negative predictive value was 93%.*
Conclusion - *We concluded that HRCT is a powerful and reliable diagnostic tool in the diagnosis of tuberculosis, which means that it can be used even before obtaining mycobacteriological results.*
Key words *• HRCT • active pulmonary tuberculosis*

Corresponding author:
Dr. Muhammad Afaq Saleem,
Allama Iqbal Medical College, Lahore

QR code

Please cite this article in press Muhammad Afaq Saleem et al, ***Efficacy Of HRCT In Identifying Active Pulmonary Tuberculosis.,*** *Indo Am. J. P. Sci, 2020; 07(10).*

INTRODUCTION:

The incidence of tuberculosis has increased dramatically worldwide since 1985. In developing countries, pulmonary tuberculosis remains a common disease, especially among socioeconomically disadvantaged, elderly and chronically debilitated people. Therefore, timely diagnosis and treatment of this disease is crucial. The chest radiograph has historically been the main tool in the diagnosis of tuberculosis and is used in conjunction with the tuberculin skin test as a means of detecting the disease. The stability of the radiographic results is the main element in assessing disease activity. Accordingly, a chest radiograph becomes more and more important in disease detection, especially in cases where the patient's reliability is not ensured. In selected cases, high-resolution computed tomography (HRCT) can identify signs of active disease not visible on a chest radiograph. In addition, CT is more sensitive in detecting subtle or latent parenchymal diseases. Recent research suggests a possible role for CT in assessing disease activity. HRCT findings on active tuberculosis have been correlated with pathological outcomes. 97% of patients with active tuberculosis had evidence of bronchogenic disease spread on HRCT. The characteristic appearance of active endobronchial disease in HRCT includes poorly defined medial-lobular nodules 5-8 mm in diameter, branched median-lobular structures and a "tree-in-bud" appearance. These lesions show the heart-shaped material filling the bronchioles, alveolar ducts and parabronchial alveoli, and the parabronchial granuloma. In the case of an acute infectious disease, they are characteristic of active tuberculosis. The aim of the study is to show the role of HRCT in the diagnosis of active pulmonary tuberculosis when other methods of tuberculosis diagnosis, e.g. culture, BAL (Broncho Alveolar Lavage) or TBLB (Trans bronchial Lung Biopsy) fail, are unavailable or are time-consuming.

MATERIALS AND METHODS:

The study included 100 people clinically suspected of having active pulmonary tuberculosis and a chest radiograph with suggestive disease patterns. This cross-sectional study was held in the Department of Radiology, Jinnah Hospital Lahore for one-year duration from April 2019 to April 2020. After meeting the above criteria, patients were included in our questionnaire. Our method of collecting information was a questionnaire that was completed based on signs and symptoms, along with chest X-ray reports and laboratory results. First, HRCT was performed, and then some patients were admitted to the hospital for further diagnosis (sputum smear and culture, and if necessary, BAL and TBLB). Our final diagnosis was based on one of the following criteria:

1. Positive smear and / or culture results for Mycobacterium tuberculosis.

2. Positive smear and / or BAL culture results for Mycobacterium tuberculosis.

3. Positive pathological results of TBLB.

If all of the above results were negative, but the patient showed a dramatic response to anti-tuberculosis drugs, the patient was classified as pulmonary tuberculosis with negative smear. Chest radiographs were viewed for typical active changes (eg, apical opacities). All patients underwent HRCT. The research was carried out on scans obtained at the end-inspiratory lung volume. Intravenous contrast agents were not used routinely; instead, contrast agents were selectively administered primarily to evaluate the mediastinum in patients with ambiguous mediastinal pathology. From the apices of the lungs to the diaphragm, sections 1.5 mm thick were taken at 10 mm intervals. All images were prospectively reconstructed using a high resolution (bone) algorithm to assess the nature of the lung lesions. Finally, the diagnosis of HRCT was compared with that obtained from the patient's clinical and paraclinical assessment to assess the diagnostic performance of HRCT. The analysis and comparison of the rank values was performed using the chi-square method. P values less than 0.05 were considered statistically significant. Sensitivity, specificity, positive and negative predictive value were also calculated.

RESULTS:

One hundred two patients (38 women and 62 men) aged 10 to 83 years, with a mean age of 47.15 ± 22.6 years, participated in the study. They all had clinical signs and symptoms of active pulmonary tuberculosis; 82.3% cough, 50% fever, 38.2% hemoptysis, 64% sputum, 31% have night sweats, and 50% weight loss. Sixty patients had a negative sputum smear and culture, 9 were positive for both the sputum smear and culture, 5 had a negative sputum smear and positive culture, and 26 were diagnosed with BAL and TBLB results. In all cases, chest radiographs were performed with a suggestive image of active pulmonary tuberculosis, i.e. infiltration or cavitation in the upper lobes. According to the HRCT results, 76 patients (74.5%) had active pulmonary tuberculosis, and further clinical studies confirmed the definitive diagnosis of active pulmonary tuberculosis in only 52 patients. Final diagnosis and diagnosis of HRCT showed a strong positive correlation. The sensitivity of HRCT in the diagnosis of active pulmonary tuberculosis was 96%, specificity 50%, positive predictive value 67%,

and negative predictive value 93%. Due to the small number of TBLB and BAL performed, no correlation was found between these results and the HRCT results. In order to find the diagnostic performance of each of the characteristic radiographic signs of tuberculosis found on computed tomography. Data analysis showed that although neither of these two parameters can be individually diagnostic (P = 0.80), their combination correctly confirms the diagnosis of tuberculosis (P = 0.082).

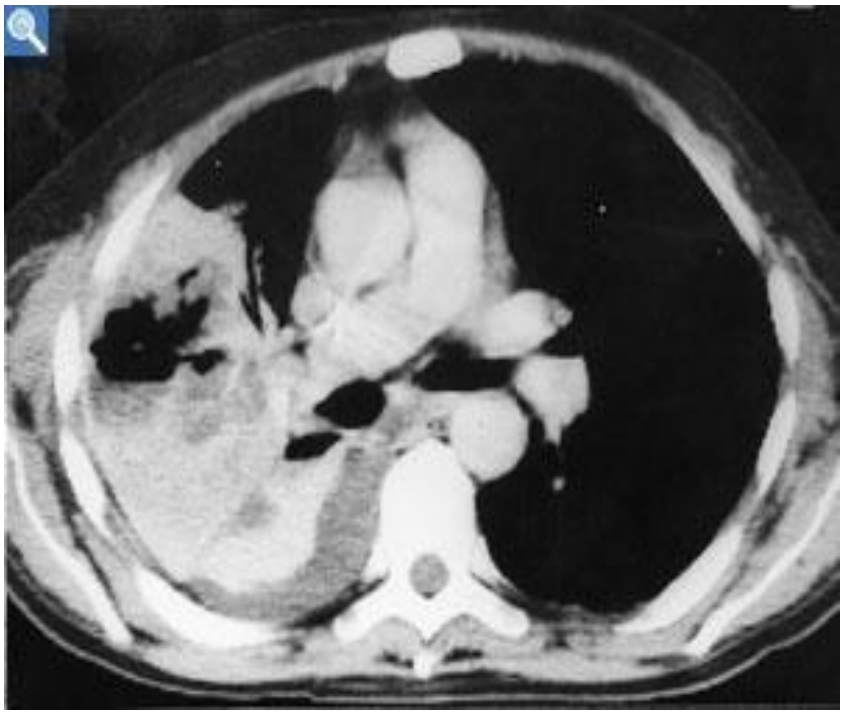

Fig. Consolidation with cavity formation seen on HRCT.

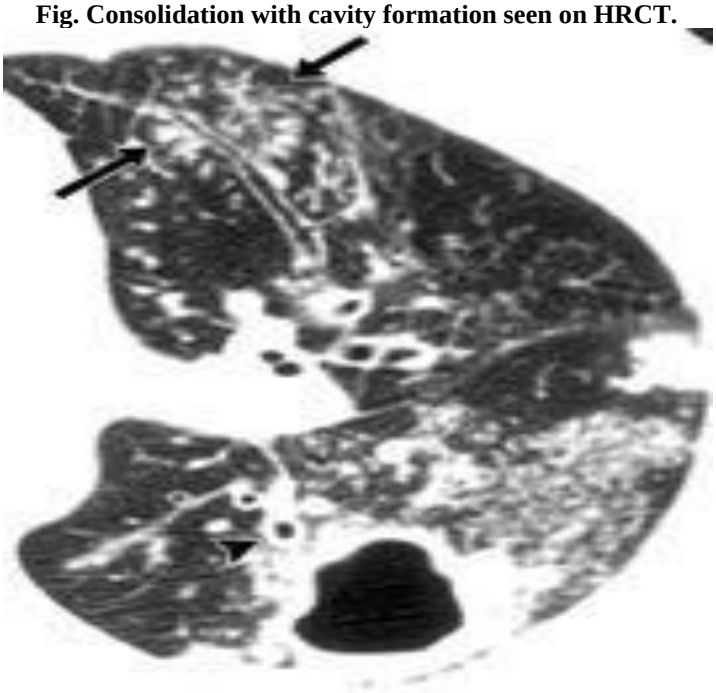

Fig. Consolidation with bud tree appearance

DISCUSSION:

Tuberculosis after primary tuberculosis is usually a disease of adolescence and adulthood. The earliest evidence of tuberculosis after its initial form is heterogeneous, poorly marginalized opacity (exudative lesion), usually in the apical or posterior part of the upper lobes. Cavitation is observed on chest radiography in 40% to 87% (mean 50%) of patients, sometimes in the course of the disease. A chest CT scan has been shown to be more accurate in detecting cavitation, especially in cases complicated by extensive fibrosis and architectural distortion. The most common complication of tuberculous cavitation is endobronchial spread, which is radiologically detected in 19–58%, and HRCT in even 98% of cases. Consequently, the detection of median lobular nodules and the appearance of a shaft in the navel in HRCT is more sensitive than a chest radiograph in detecting early endobronchial disease. In selected cases, HRCT can identify signs of active disease not visible on chest radiographs. The increased sensitivity of computed tomography may also prompt a diagnosis, even while waiting for the results of microbiological tests. In our study, we found that in 76 cases (74.5%), HRCT suggested a diagnosis of active pulmonary tuberculosis before bacteriological results were available. Further studies showed that 52 of these cases (51%) were in fact infected with Mycobacterium tuberculosis and therefore received anti-tuberculosis therapy with promising results. Chi-square analysis showed a strong positive correlation between the final diagnosis and the diagnosis of HRCT with a sensitivity of 96% and a specificity of 50%, which strongly supports our hypothesis about the role of HRCT in the diagnosis of active pulmonary tuberculosis. Although chest radiographs usually provide sufficient information for a diagnosis of active pulmonary tuberculosis, minimal exudative tuberculosis may be overlooked on standard chest radiographs. The aim of the study was to evaluate the results of active pulmonary tuberculosis tests in high resolution computed tomography (HRCT) and to evaluate the possibility of their use in determining the disease activity. The diagnosis of active pulmonary tuberculosis was based on positive acid-fast mycobacteria in smears or cultures of sputum and bronchial lavage and / or changes in serial radiographs obtained during treatment. In the case of middle-lobular lesions using the HRCT method (n = 29), in the case of active pulmonary tuberculosis, the most frequently observed appearance was "tree in bud" (n = 23) and macronodules 5-8 mm in diameter (n = 22). HRCT scans showed fibrotic changes (n = 34), distortions of bronchovascular structures (n = 32), emphysema (n = 28), and bronchiectasis (n = 24) in patients with inactive tuberculosis. Medial lobular densities in and around the small airways and the appearance of a tree in a bud were the most characteristic features of disease activity on CT. The HRCT scan clearly differentiated the old fibrotic lesions from the new active lesions and showed early bronchial spread. Furthermore, our results showed that although infiltration was the predominant symptom of HRCT, the appearance of a "middle lobule nodule" and "tree in a bud" were the main symptoms in most cases of active pulmonary tuberculosis.

CONCLUSION:

In this study, we concluded that HRCT is a powerful and reliable tool for tuberculosis diagnosis when other tuberculosis diagnosis methods (eg, culture, BAL or TBLB) do not resolve the matter, are unavailable or time consuming.

REFERENCES:

1. Pant, Chiranjibi, Anusmriti Pal, Manoj Kumar Yadav, and Bishow Kumar Shrestha. "High resolution computed tomography and chest x-ray findings in patient with pulmonary tuberculosis." *Journal of Chitwan Medical College* 9, no. 4 (2019): 32-34.
2. Chunawala, Zainali, and Ira Shah. "Clinical Profile of Children with Mediastinal Tuberculosis." *Journal of Tropical Pediatrics* (2020).
3. Devi, RK Jayshree, and Kh Mani Singh. "Computed Tomography Thorax-Role in the Diagnosis of Pulmonary Tuberculosis." *Journal of Evolution of Medical and Dental Sciences* 9, no. 7 (2020): 422-428.
4. Johari, Bushra, and Mohammad Hanafiah. "Unilateral Nonconfluent Cluster of Micronodules: Atypical Radiologic Appearance of Pulmonary Tuberculosis in an Immunocompetent Patient." *Case Reports in Medicine* 2020 (2020).
5. Rout, Bijnan Kumar, Basanta Manjari Swain, Mamata Singh, and Theeta Mohanty. "High-resolution computed tomography thorax evaluation of sputum positive/CBNAAT positive pulmonary tuberculosis in diabetic and non-diabetic patients." *Eastern Journal of Medical Sciences* (2020).
6. Sharif, Nadia, Mirza Saifullah Baig, Sana Sharif, and Muhammad Irfan. "Etiology, Clinical, Radiological, and Microbiological Profile of Patients with Non-cystic Fibrosis Bronchiectasis at a Tertiary Care Hospital of Pakistan." *Cureus* 12, no. 3 (2020).
7. Sahu, Niranjan, Somadatta Das, and Rabindra Nath Padhy. "Radiological significance of high-

resolution computed tomography for elderly pulmonary tuberculosis patients–an analysis with culture test." *Polish Journal of Radiology* 85 (2020): e125.

8. Meshram, S. H., A. Alexander, R. Yadav, S. Muley, C. Shamkuwar, and A. Ghandhare. "Pulmonary Alveolar Microlithiasis-A Rare Entity from Rural India." In *B40. TEASERS IN DIFFUSE LUNG DISEASE*, pp. A3307-A3307. American Thoracic Society, 2020.
9. Malik, Mahmood Iqbal, Taymmia Ejaz, Jamal Ahmed, Komal Arshad, Yousaf Jamal, and Zeenat Zohfreen. "DIAGNOSTIC ACCURACY OF GENEXPERT ASSAY AND COMPARISON WITH SMEAR AFB ON BRONCHIAL WASHINGS IN SPUTUM NEGATIVE SUSPECTED PULMONARY TUBERCULOSIS." *Pakistan Armed Forces Medical Journal* 69, no. 4 (2019): 857-62.
10. Pandey, Saurabh, Subir Ghosh, Prantiki Halder, Dipankar Pal, Dolon Champa Modak, and Subhasish Kamal Guha. "Pulmonary tuberculosis and pneumocystis jirovecii concurrent pneumonia in HIV infected patients at a resource limited setting in Eastern India: A case series." *Indian Journal of Tuberculosis* 67, no. 3 (2020): 378-382.
11. Satti, Shahzeb Ahmad, Abdul Moueed Tariq, Abdul Latif Khattak, Salman Saleem, Rafi ud Din, and Azhar Ali Chaudhry. "Assessment of Lung Function using Spirometry and Radiological findings in Post Tuberculosis Cases." *Life and Science* 1, no. 3 (2020): 5-5.
12. Shah, Ira, Naman S. Shetty, Anmol Goyal, Nikhil Patankar, and Sujeet M. Chilkar. "Clinical profile of tuberculosis in children." *Medical Journal of Dr. DY Patil Vidyapeeth* 13, no. 1 (2020): 43.
13. Tiamiyu, Abdulwasiu Bolaji, Garba Iliyasu, Farouq Muhammad Dayyab, Zaiyad Garba Habib, Sirajo Haliru Tambuwal, Ayobami Olawale Animashaun, Habibu Galadanci, Sunday A. Bwala, Lovett Lawson, and Abdulrazaq Garba Habib. "A descriptive study of smear negative pulmonary tuberculosis in a high HIV burden patient's population in North Central Nigeria." *Plos one* 15, no. 9 (2020): e0238007.
14. d'Alessandro, Miriana, Alfonso Carleo, Paolo Cameli, Laura Bergantini, Anna Perrone, Lucia Vietri, Nicola Lanzarone, Cecilia Vagaggini, Piersante Sestini, and Elena Bargagli. "BAL biomarkers' panel for differential diagnosis of interstitial lung diseases." *Clinical and Experimental Medicine* (2020): 1-10.
15. Gharbi, Reem, Besma Mhenni, Saloua Ben Fraj, and Helmi Mardassi. "Nontuberculous mycobacteria isolated from specimens of pulmonary tuberculosis suspects, Northern Tunisia: 2002–2016." *BMC infectious diseases* 19, no. 1 (2019): 819.