



CODEN [USA]: IAJPBB

ISSN: 2349-7750

**INDO AMERICAN JOURNAL OF  
PHARMACEUTICAL SCIENCES**<http://doi.org/10.5281/zenodo.1412696>Available online at: <http://www.iajps.com>

Research Article

**WHICH IS A BETTER ANAL FISSURE MANAGEMENT? AAF  
(ANAL ADVANCEMENT FLAP) VERSUS LS (LATERAL  
SPHINCTEROTOMY): A COMPARATIVE RESEARCH**<sup>1</sup>Dr. Mehek Azam, <sup>2</sup>Dr. Maria Qibtia, <sup>3</sup>Dr. Muhammad Ahmad Choudhry<sup>1</sup>WMO, BHU Chak Chaudhary, Noshehra Virkan<sup>2</sup>Mayo Hospital Lahore<sup>3</sup>House Officer Mayo Hospital Lahore**Abstract:**

**Objective:** This research was aimed to compare Anal incontinence and Infection between Anal Advancement Flap (AAF) and Lateral Sphincterotomy (LS) in anal fissure patients.

**Material and methods:** We conducted a comparative research at Allied Hospital, Faisalabad in Surgical Department (February 2016 to January 2017) on a total of one hundred anal fissure patients. Research sample was divided in two group carrying fifty chronic anal fissure patients in each group in the age bracket of (15 – 60) years without any discrimination of gender. We did not include all the patients diagnosed with related perianal diseases along with acute anal fissure such as abscess, fistula and hemorrhoids. We also avoided all the patients who have experienced any previous anal canal surgical procedure. Random division of the patients was made through computer-generated numbers. Group A & B (chronic anal fissure patients) were respectively treated with LS (Lateral Sphincterotomy) and AAF (Anal Advancement Flap) procedures.

**Results:** Sample population was divided into two groups named as Group A and B with respective mean age of (36.45 ± 9.68) years and (38.61 ± 9.77) years. The male proportion in Group A and B was respectively 45 males 56.25% in A group and 46 males 57.5% in B group; whereas, females' proportion in Group A and B was respective 35 females 43.75% in A group and 34 females 42.5% in B group. It was learned through the outcomes analysis of LS and AAF of the anal fissure patients that infected cases were present in both the groups. Group A and B had respectively 10 cases 12.5% and 3 cases 3.75% with a significant P-value (0.01). Group A and B were also observed for anal incontinence having respective cases as 14 cases 17.5% in A group and 2 cases 2.5% in B group with a significant P-value as (0.001).

**Conclusion:** It is concluded that outcomes are much significant and better than the outcomes of for chronic anal fissure treatment regarding anal continence and infection.

**Keywords:** AAF (Anal Advancement Flap), LS (Lateral Sphincterotomy), Anal Fissure, Anal Continence and Infection.

**Corresponding author:**

**Dr. Mehek Azam,**  
WMO, BHU Chak Chaudhary,  
Noshehra Virkan

QR code



Please cite this article in press Mehek Azam et al., *Which is a better anal fissure management? AAF (anal advancement flap) versus ls (lateral sphincterotomy): a comparative research.*, Indo Am. J. P. Sci, 2018; 05(09).

**INTRODUCTION:**

Painful defecation and rectal bleeding are associated with Anal fissure as it is a severely painful state. It is a radial anoderm split that is extended from anal verge to dentate line with varying proximal distance. They are also characterized as non-healing and also induce a linear indurated ulcer. Various factors are used for its pathogenesis such as mechanical trauma, sphincter spasm and ischemia [1]. In the total anorectal patients, this condition is prevalent about 30% – 40%; whereas, this condition develops in dry and hard stool patients [2].

Current management heals and relaxes the internal sphincter through topical pharmacological interventions and agents. Pain and spasm are reduced; whereas, it also increases the ulcer healing and promotes vascular perfusion. These agents are the combination of diltiazem and glyceryl trinitrate with a respectively added proportion of 2% & 0.2% [3]. The surgical approach is the only option left in case if conservative management fails [4]. Lateral internal sphincterotomy can be used even in the absence of a failure of pharmacologic treatment, this practice is applied by the Rectal and Colon surgeons of America [5]. Ultimate management of the anal fissures is treated in this way as it is also taken as a gold standard treatment for anal fissure patients; it has a healing rate of 92% – 100%; fissures are healed in the timeframe of eight weeks (02 months), but incontinence is an added risk [6, 7].

AAF (Anal Advancement Flap) is another effective primary management to heal and treat anal fissure patients, it is also very much effective for the recurrent anal fissure cases. As it is an excellent treatment and possesses quick remedial features so it can be applied on the chronic anal fissure patients as well for the production of good, safe and quick results as it relieves complications and pain [1]. On routine basis chronic anal fissure patients are treated with lateral internal sphincterotomy; whereas, very scarce literature is available about this practice. However, our research will be very much helpful for the generation of awareness and importance of AAF ((Anal Advancement Flap).

**MATERIAL AND METHODS:**

We conducted a comparative research at Allied Hospital, Faisalabad in Surgical Department (February 2016 to January 2017) on a total of one hundred anal fissure patients. The research sample was divided into two group carrying fifty chronic anal fissure patients in each group in the age bracket of 15 – 60 years without any discrimination of gender. We did not include all the patients diagnosed

with related perianal diseases along with acute anal fissures such as abscess, fistula and haemorrhoids. We also avoided all the patients who have experienced any previous anal canal surgical procedure. Random division of the patients was made through computer-generated numbers. Group A & B (chronic anal fissure patients) were respectively treated with LS (Lateral Sphincterotomy) and AAF (Anal Advancement Flap) procedures.

LS (Lateral Sphincterotomy) was carried out in the presence of regional anaesthesia given with open method in the lithotomy position. An incision of five millimetres was made in the perianal skin. After that dissection of internal anal sphincter was carried out and the segment was taken out with the help of artery forces and it was then divided with diathermy up to dentate line level.

AAP (Anal Advancement Flap) was carried out with the help of a V-shaped incision that extended from the fissure edges away from midline but about four centimetres from the anal verge. Sufficient mobilization of fat was made in order to make an advancement in the anal canal to cover the defect of the fissure. We preserved sufficient pedicles for the blood supply adequacy during the procedure. Flap base suturing was made to the lower anal mucosa. The supervisor was available to supervise both the interventions. The operational definition was made intact for the wound assessment after three days of procedure and after three months we assessed anal continence.

**RESULTS:**

The sample population was divided into two groups named as Group A and B with respective mean age of (36.45 ± 9.68) years and (38.61 ± 9.77) years. The male proportion in Group A and B was respectively 45 males 56.25% in A group and 46 males 57.5% in B group; whereas, females' proportion in Group A and B was respective 35 females 43.75% in A group and 34 females 42.5% in B group. It was learned through the outcomes analysis of LS and AAF of the anal fissure patients that infected cases were present in both the groups. Group A and B had respectively 10 cases 12.5% and 3 cases 3.75% with a significant P-value (0.01). Group A and B were also observed for anal incontinence having respective cases as 14 cases 17.5% in A group and 2 cases 2.5% in B group with a significant P-value as (0.001).

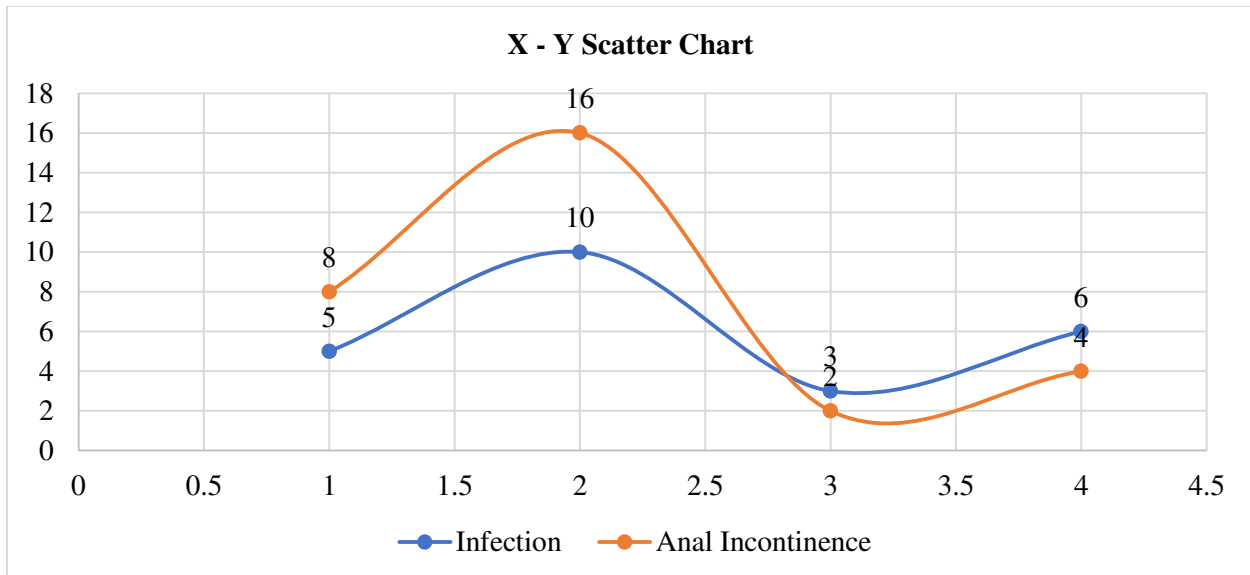
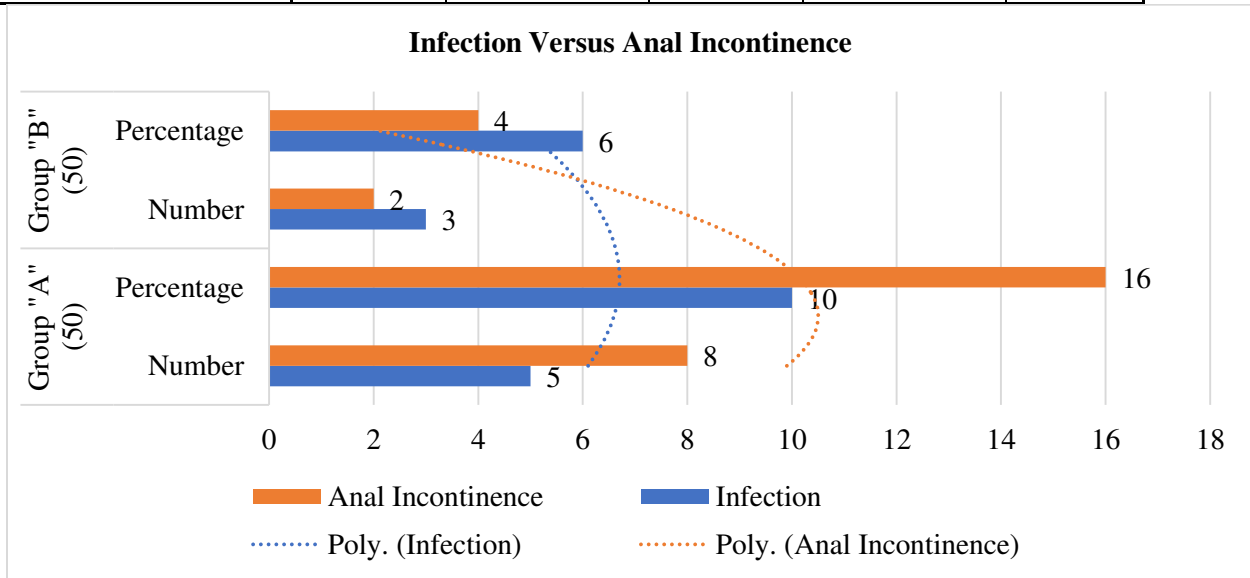
Group A and B were reported infection respective in 5 cases with 10% and 1 cases 2% with a significant P-value as (< 0.05). Anal incontinence in Group A and B was reported respectively as 8 cases 16% and 2

cases 4% with a significant P-value as ( $< 0.05$ ). These both variables were observed significantly low in AAF (Anal Advancement Flap) than without AAF.

Detailed outcomes analysis has been made in the given tabular and graphical data.

**Table: LS (Lateral Sphincterotomy) Versus AAF (Anal Advancement Flap) (100)**

Outcomes	Group "A" (50)		Group "B" (50)		P-Value
	Number	Percentage	Number	Percentage	
Infection	5	10	3	6	< 0.01
Anal Incontinence	8	16	2	4	



**DISCUSSION:**

Previous research studies can be compared with our research in terms of outcomes about the post-operational infection with AAF (Anal Advancement Flap) and without AAF respectively 0% & 7.5% [2]. Anal incontinence with AAF and LS was respectively reported as zero percent and twenty percent after being treated for three months [8].

Chronic anal fissures are also treated with flap anoplasty therapy which involves fissure defect covering with local flaps. It does not involve any internal anal sphincter disruption. Normal anal fissure and obstetrical trauma fissures can better be managed with this therapy. An author reported 81% recovery rate with the management of rotation flap; he also reported flap failure and incontinence rate respectively 11.8% and 0% [9]. Another author gained 98% recovery rate with the application of V-Y advancement flap and also reported flap dehiscence and incontinence rate respectively 5.9% and 0%; whereas, reoccurrence was reported about 5.9% with the formation of the fissure at a different location [10].

Previously total, mild, moderate and severe postoperative incontinence was reported respectively 55%, 33%, 9% and 3%. An improvement in the numbers was observed during follow-up having total, mild, moderate and severe incontinence respectively as 89%, 6.5%, > 63.7% and 0.8%. It is a fact that a number of incontinences were not reported in the category of severe incontinence which reflected better life quality after the application of AAF (Anal Advancement Flap). Patients also reported about an effect on the social life (3.3%), physical state (3.7%) and sexual life (1%) as an outcome of postoperative faecal incontinence. Incontinence affected the lives of under one percent patients as observed through the responses to the questionnaire. AAF (Anal Advancement Flap) is better treatment; this hypothesis needs more deep research work for its validation.

**CONCLUSION:**

It is concluded that outcomes are much significant and better than the outcomes of for chronic anal fissure treatment regarding anal continence and infection.

**REFERENCES:**

1. Zaghayan KN, Fleshner P. Anal fissure. *Clin. Colon Rectal Surg.* 2011; 24:22-30.
2. Patti R, Guercio G, Territo V, Aiello P, Angelo GL, Davita G. Advancement flap in the

management of chronic anal fissure: a prospective study. *Updates. Surg.* 2012; 64:101-6.

3. Poh A, Tan KY, Choen FS. Innovation in chronic anal fissure treatment. *World J Gastrointest Surg.* 2010 27; 2: 231-41.
4. Hancke K. Dermal flap coverage for chronic anal fissure: lower incidence of anal incontinence compared to latera internal sphincterotomy after long-term follow up. *Colon Rectum.* 2010; 53:1563-8.
5. Singh M, Sharma A, Gardiner A, Duthie GS. Early results of a rotational flap to treat chronic anal fissures. *Int J Colorectal Dis.* 2005; 20:339-42.
6. Giordano P, Gravante G, Grondona P, Ruggiero B, Porrett T, Lunniss PJ. Simple cutaneous advancement flap anoplasty for resistant chronic anal fissure: a prospective study. *World J Surg.* 2009; 33:1058-63.
7. Hegazi T, Soliman SS. Combined tailored lateral internal sphincterotomy with v-y advancement flap versus lateral internal sphincterotomy alone in the treatment of chronic anal fissure. *Med J CairoUniv.* 2013;81:959-6
8. Dudhamal TS, Baghel MS, Bhuyan C, Gupta SK. Comparative study of Ksharasutra suturing and Lord's anal dilatation in the management of chronic fissure-in-ano. *Int. Quart. J*
9. Patel HS, ChardaJ, Naik N, Parikh J, study of operated patients of lateral Internal anal sphincterotomy for chronic anal fissure. *J Clin Diag Res.* 2013; 7:2863-5.
10. Altomare DF, Binda GA, Canuti V, Landolfi V, Trompetto M, Villani RD. The management of patients with primary chronic anal fissure: a position paper. *Tech coloproctol* 2011; 15:135-141.