



CODEN [USA]: IAJPB

ISSN: 2349-7750

**INDO AMERICAN JOURNAL OF  
PHARMACEUTICAL SCIENCES**<http://doi.org/10.5281/zenodo.1433620>Available online at: <http://www.iajps.com>

Research Article

**A DESCRIPTIVE RESEARCH TO ASSESS THE RARE  
OCCURRENCE OF KNEE INJURY IN THE LIGHT OF  
CLINICAL AND OPERATIVE OUTCOMES**<sup>1</sup>Dr. Junaid Almas, <sup>2</sup>Dr. Ifra Rehman, <sup>3</sup>Dr. Hafiza Faiza Umbreen Rana<sup>1</sup>Medical Officer, BHU Rukan Pura Okara<sup>2</sup>DHQ Hospital Kasur<sup>3</sup>Demonstrator. Aziz Fatima Medical and Dental College, Faisalabad**Abstract:**

**Objective:** Research was aimed to identify a rare mechanism of a serious knee injury which causes damage to ligaments only.

**Material and methods:** We carried out a descriptive research at Mayo Hospital, Lahore from April 2016 to January 2017. We enrolled twenty cases of the instability of knee in our research. These patients actually fell during construction work at various places from a ladder while falling their ankle entangled in the ladder and it caused the damage to the knee of the individuals. Patients were selected in the age bracket of (22 – 35) years and all the patients were female without any female candidate as a part of this research. In the total sample strength, ten cases were of right and ten were of a left knee injury. Surgery was carried out within the time span of three to fifteen days of reporting to hospital. Rehabilitation consultation was carried out after two weeks of operation and routine follow-up was also continued. All the patients who were focused on injury mechanism were interviewed. All the colleagues or relatives who were present at the time of the accident recalled and narrated the story of the accident and most common reason of injuries was fall from the ladder with an entangled ankle in the ladder that became the source of a severe knee injury. It was also reported that an unusual event or mechanism was responsible for the ligamentous injury which subsequently ended in surgical intervention. It was reported in the surgical outcomes that injuries included anterior cruciate ligament tear and wear, every patient had medial posterior oblique and collateral ligament. Posterior cruciate ligament and post-capsule ligament were also damaged in five cases. In this particular research, no case was reported for lateral menisco-tibial or lateral collateral ligament injury. The mainstay of full physical assessment reconstruction through arthroscopy of anterior or posterior cruciate ligament. Another very important evaluation was of medial collateral ligament (Grade – III) complete tear. The time span of follow-up extended from nine to twenty-four months, which varied patient to patient.

**Results:** Anterior and posterior cruciate ligament reconstruction and medial collateral ligament grade III tear is the mainstay treatment which is followed by complete physical rehabilitation. Routine activities were carried out by the patients in the timeframe of four to six months after the surgery and a smaller number of complications were reported. All the patients were stale but one case had knee stiffness and two others were reported instable mild residual anteromedial. No patient was reported for the neurological deficit.

**Conclusion:** Injury mechanism management awareness was the most significant deciding factor in order to manage the injuries. The chances of abduction-traction injury are also to be considered in the management of knee injuries especially in the patients who fall from certain heights which include freefall jumpers and construction workers.

**Keywords:** Height Fall, Head Downward, Ankle Entrapment, Ladder, Construction, Workers and Parachute.

**Corresponding author:****Dr. Junaid Almas,**

Medical Officer,

BHU Rukan Pura Okara

QR code



Please cite this article in press Junaid Almas et al., *A Descriptive Research to Assess the Rare Occurrence of Knee Injury In The Light Of Clinical and Operative Outcomes.*, Indo Am. J. P. Sci, 2018; 05(09).

**INTRODUCTION:**

Literature reveals about various injuries such as menisci isolated injuries, Knee ligaments and osteochondral surface ligaments [1, 2]. Combined injuries pattern is also found in the patients [3 – 5]. A common mechanism can also be responsible for the combination of injuries [6]. For accurate diagnosis, it is very much important to find out the exact injury mechanism. Precise mechanism description is a complex process as more than one forces are acting on the knee in the sustenance of injury. Active cooperation of the patients and his narration of the event such as movement recalling, injured knee position and external force involvement. Majority of the injuries are reported because of the position while carrying heavy loads. Rotation and compression forces cause osteochondral fractures or meniscal tears. Adduction, abduction and rotation movement causes damage to the ligaments. The research was aimed to identify a rare mechanism of a serious knee injury which causes damage to ligaments only.

**PATIENTS AND METHODS:**

We carried out a descriptive research at Mayo Hospital, Lahore from April 2016 to January 2017. We enrolled twenty cases of the instability of knee in our research. These patients actually fell during construction work at various places from a ladder while falling their ankle entangled in the ladder and it caused the damage to the knee of the individuals. Patients were selected in the age bracket of (22 – 35) years and all the patients were female without any female candidate as a part of this research. In the total sample strength, ten cases were of right and ten were of a left knee injury. Surgery was carried out within the time span of three to fifteen days of reporting to hospital. Rehabilitation consultation was carried out after two weeks of operation and routine follow-up was also continued. All the patients who were focused on injury mechanism were interviewed. All the colleagues or relatives who were present at the time of the accident, recalled and narrated the story of the accident and most common reason of injuries was fall from ladder with an entangled ankle in the

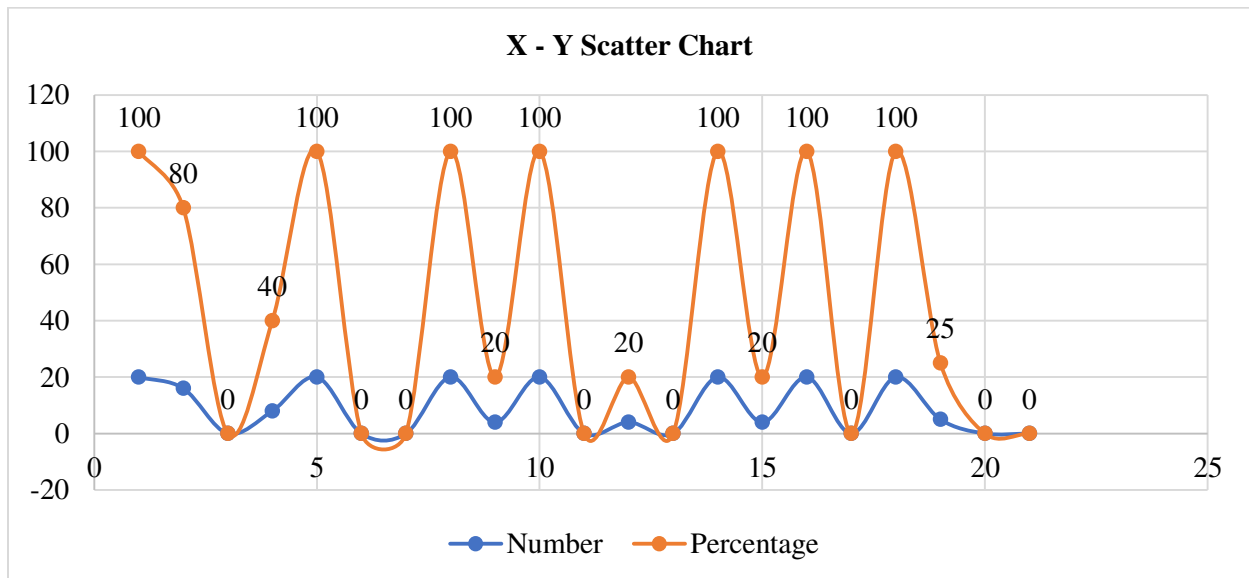
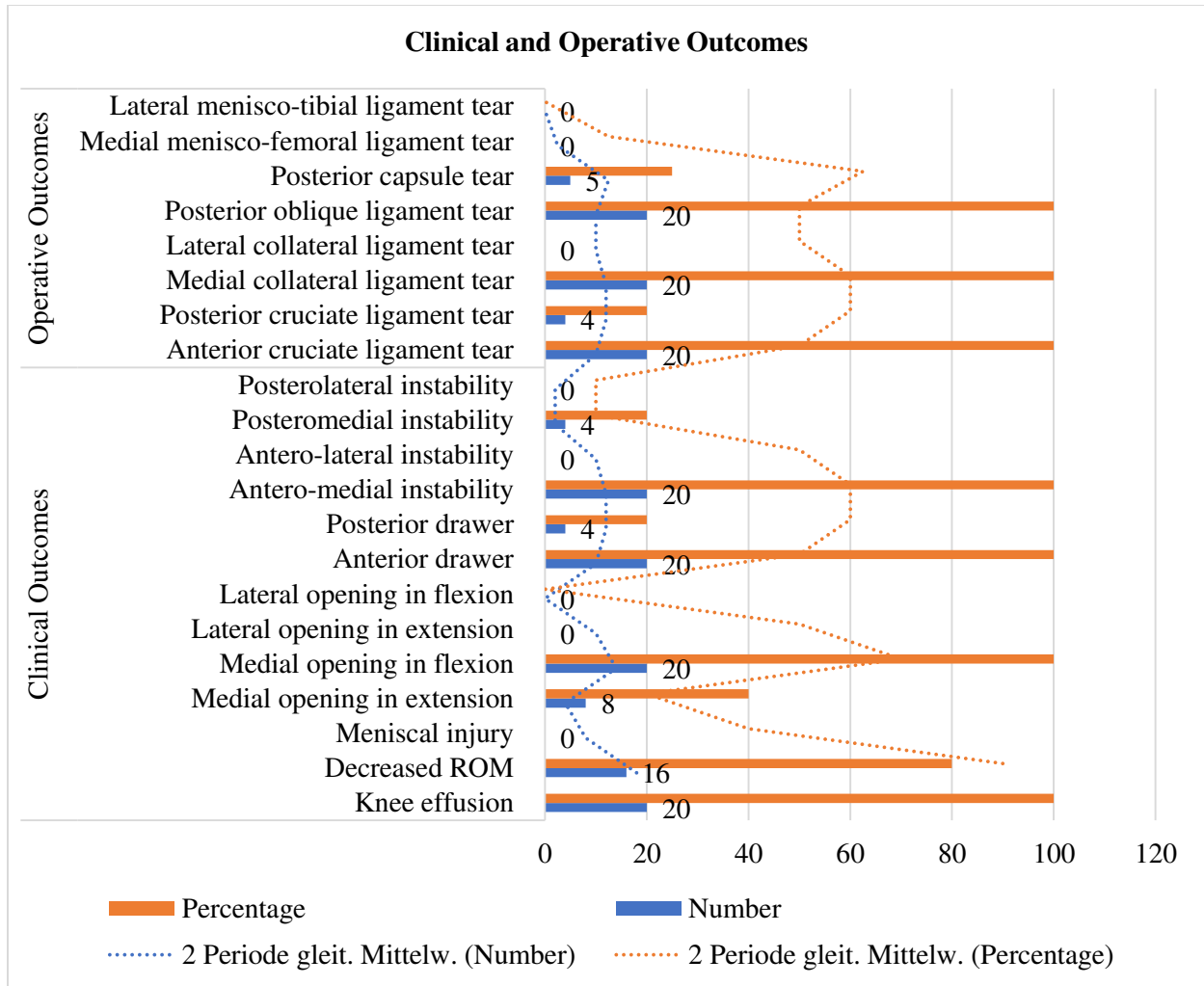
ladder that became the source of severe knee injury. It was also reported that an unusual event or mechanism was responsible for the ligamentous injury which subsequently ended in surgical intervention. It was reported in the surgical outcomes that injuries included anterior cruciate ligament tear and wear, every patient had medial posterior oblique and collateral ligament. Posterior cruciate ligament and post-capsule ligament were also damaged in five cases. In this particular research no case was reported for lateral menisco-tibial or lateral collateral ligament injury. The mainstay of full physical assessment reconstruction through arthroscopy of anterior or posterior cruciate ligament. Another very important evaluation was of medial collateral ligament (Grade – III) complete tear. The time span of follow-up extended from nine to twenty-four months, which varied patient to patient.

**RESULTS:**

Anterior and posterior cruciate ligament reconstruction and medial collateral ligament grade III tear are the mainstay treatment which is followed by complete physical rehabilitation. Routine activities were carried out by the patients in the timeframe of four to six months after the surgery and a smaller number of complications were reported. All the patients were stale but one case had knee stiffness and two others were reported instable mild residual anteromedial. No patient was reported for the neurological deficit. A pre-operative picture of clinical manifestations was revealed through hospital records which has been reflected in the tabular data. Each case was observed with a pre-operative anteromedial instability. No meniscal injury case was observed; whereas, four cases of postero-media. Fibrillation or Osteochondral was not reported in the research sample. A physical rehab program was carried out for every patient. Routine activities were resumed by all patients within the duration of four to six months after the surgical intervention. Detailed outcomes analysis is carried out in the given clinical and operative outcomes.

**Table 1:** Frequency of Operative and Clinical Outcomes (20)

	<b>Outcomes</b>	<b>Number</b>	<b>Percentage</b>
<b>Clinical Outcomes</b>	Knee effusion	20	100
	Decreased ROM	16	80
	Meniscal injury	0	0
	Medial opening in extension	8	40
	Medial opening in flexion	20	100
	Lateral opening in extension	0	0
	Lateral opening in flexion	0	0
	Anterior drawer	20	100
	Posterior drawer	4	20
	Antero-medial instability	20	100
	Antero-lateral instability	0	0
	Posteromedial instability	4	20
	Posterolateral instability	0	0
	<b>Operative Outcomes</b>	Anterior cruciate ligament tear	20
Posterior cruciate ligament tear		4	20
Medial collateral ligament tear		20	100
Lateral collateral ligament tear		0	0
Posterior oblique ligament tear		20	100
Posterior capsule tear		5	25
Medial menisco-femoral ligament tear		0	0
Lateral menisco-tibial ligament tear		0	0



**DISCUSSION:**

Barnes and Richman described abduction traction injury of the extended knee or slightly flexed knee [7]. The weight of body acts as a force that pulls the body in the downward direction and counteracts the ankle pulling force (blocking force) in the upside-down direction with the head facing downward direction. The resultant injury (abduction traction) is an instability with knee medial opening in slight flexion. Barnes and Richman used a conservative approach to treat all these patients [7].

Every patient had an anteromedial instability and repeatedly complex instability was faced because of tibia abduction in the semi-flexed knee and lateral rotation [6, 8]. Semi-flexed knee position in lateral rotation and abduction is responsible for anterior cruciate ligament tension reduction and lateral collateral ligament laxity. As a result, tibia posteromedial corner rotates in the forward direction which tears the first medial capsule then it damages the medial collateral ligament and in case of its continuation, it also harms the anterior cruciate ligament [3, 5]. PCL is also considered as an escape injury [4]. We found in our research that there were cases with the torn posterior cruciate ligament that attributed in the posterior medial instability an also caused an anteromedial instability.

In the presence of physiological conditions, body weight compresses the femoral condyles against menisci and tibial condyles, which prevents valgus movement and excessive varus. In this case, there is no harm to the ligaments in the shape of an injury. There are more chances of injury to ligaments and capsule if less load is exerted on the joints [9]. In order to stabilize the body, the rotation is an important factor, knee traction is caused by the body weight in abduction-traction injury cases; in the compromised state of abduction and knee ligaments in addition to lateral rotation tears the medial collateral ligament, post oblique ligament and anterior cruciate ligament. Nine patients also faced a strong traction which caused damage posterior cruciate ligament and posterior capsule.

The force of rotation and compression endangers menisci; whereas, rotatory traction in the presence or absence of (adduction - abduction) tears ligaments [4]. In case of reduced axial load, there are chances of ligament injury less than the menisci damage or increased chances of articular cartilage [10].

About (27% – 62%) of the patients had reduced injured knee ligament with related injuries of menisci [11, 12]. Meniscal injuries were also associated with

ligament injuries in about 17% of patients as stated by an author [13]. Twenty percent cases of acute ligamentous also had fibrillations or chondral fractures [11]. Almost 50% – 100% of patients also demonstrate lateral meniscal injuries in the weight-bearing anterolateral instability [14, 15].

We did not find any case of osteochondral fractures or meniscal tears. Pure ligament injuries were observed. Injuries had no involvement of compression. Outcomes were satisfactory because of ligament reconstruction technical advancement, high expertise and patient's cooperation.

**CONCLUSION**

There is a rare occurrence reported about the knee abduction-traction injury. Better diagnostic strategies can be incorporated with the help of a careful historical probe. Better outcomes can be gained through surgical interventions. Injury mechanism management awareness was the most significant deciding factor in order to manage the injuries. The chances of abduction-traction injury are also to be considered in the management of knee injuries especially in the patients who fall from certain heights which include freefall jumpers and construction workers.

**REFERENCES:**

1. Wang CJ, Walker PS. Rotatory laxity of the human knee joint. *J Bone Joint Surg Am*1974;56(1):161-70.
2. Noyes FR, Bassett RW, Grood ES, Butler DL. Arthroscopy in acute traumatic hemarthrosis of the knee: incidence of anterior cruciate tears and other injuries. *J Bone Joint Surg [Am]*1980; 62-A: 687-95.
3. Hart JAL. Meniscal injury associated with acute and chronic ligamentous instability of the knee joint. *J Bone Joint Surg [Br]* 1982;64-B:119.
4. Pickett JC, Altizer TJ. Injuries of the ligaments of the knee. A study of types of injury and treatment in 129 patients. *Clin Orthop Relat Res* 1971; 76:27-32.
5. Galway RD. The pivot shift syndrome. *J Bone Joint Surg [Br]* 1972;54-B:558.
6. Slocum DB, James SL, Larson RL, Singer KM. Clinical test for anterolateral rotary instability of the knee. *Clin Orthop Relat Res*1976;(118):63-9.
7. Palmer I. On the injuries to the ligaments of the knee joint: a clinical study. 1938. *Clin Orthop Relat Res* 2007 Jan;454:17-22.
8. Richman RM, Barnes KO. Acute instability of the ligaments of the knee as a result of injuries to parachutists. *J Bone Joint Surg Am* 1946; 28:473-90.

9. Abbott LC, Saunders JB del M, Bost FC, Anderson CE. Injuries to the ligaments of the knee joint. *J Bone Joint Surg* 1944; 26:503-31.
10. Markolf KL, Bargar WL, Shoemaker SC, Amstutz HC. The role of joint load in knee stability. *J Bone Joint Surg [Am]* 1981;63-A:570-83.
11. Feagin JA, Abbott HG, Rokous JR. The isolated tear of the anterior cruciate ligament. *J Bone Joint Surg* 1972;54-A:1340-1.
12. Wang JB; Rubin RM; Marshall JL. A mechanism of isolated anterior cruciate ligament rupture. Case report. *J Bone Joint Surg Am* 1975;57(3):411-3.
13. Kennedy JC, Fowler PJ. Medial and anterior instability of the knee: an anatomical and clinical study using stress machine. *J Bone Joint Surg [Am]* 1971: 53-A: 1257-70.
14. Nicholas JA. The five-one reconstruction for anteromedial instability of the knee: indications, technique and the results in fifty-two patients. *J Bone Joint Surg [Am]* 1973: 55-A: 899-922.
15. Kennedy JC, Weinberg HW, Wilson AS. The anatomy and function of the anterior cruciate ligament: as determined by clinical and morphological studies. *J Bone Joint Surg [Am]*1874; 56-A: 223-35.