



CODEN [USA]: IAJPBB

ISSN: 2349-7750

INDO AMERICAN JOURNAL OF
PHARMACEUTICAL SCIENCES

<http://doi.org/10.5281/zenodo.3386696>

Available online at: <http://www.iajps.com>

Research Article

COMPARISON OF NON-INVASIVE BIOCHEMICAL MARKERS (APRI, FIB-4) WITH FIBROSCAN FOR PREDICTION OF CIRRHOSIS IN HEPATITIS C PATIENTS

¹Dr. Sidra Zaheer, ²Dr. Mehwish Jalil, ³Dr Ammad Amjad

¹Pakistan Institute of Medical Sciences, ²Akhtar Saeed Medical and Mental College Lahore, ³Shalamar Hospital, Lahore.

Article Received: July 2019

Accepted: August 2019

Published: September 2019

Abstract:

Aim: The key purpose of our research was to measure association amongst fibrotic area (FA) as intended through the numerical image analysis (DIA), also to associate analytical correctness of Fibro Scan to additional prevailing Liver fibrosis (LF) indicators while experiencing receiver functioning curve examination.

Methods: Researchers employed 35 cases that experienced the liver resection for 3 diverse etiologies counting standard liver, hepatitis B, also hepatitis C. designed through numerical image analysis to assess Liver fibrosis in order to evade somewhat sample partiality. Researchers observed 36 cases that experienced the liver resection from May 2017 to April 2018. Liver difficulty stayed leisurely through experiencing the Fibro Scan. The fibrotic area remained at that time designed through numerical image analysis to assess Liver fibrosis in order to evade somewhat sample partiality.

Results: The fibrotic area harmfully connected by Prothrombin time, platelet sum, lecithin-cholesterol acyltransferase, also pre-albumin. On supplementary side, results of Fibro Scan connected through comparable signs. The fibrotic area absolutely associated by Fibro Scan, serum hyaluronate equal, also kind IV collagen equal, in addition aspartate transaminase to platelet relation directory. The zone underneath receiver functioning arc for Fibro Scan remained developed than that for extra signs, whereas arithmetical implication remained negligible.

Conclusion: The current conclusions recommend that fibro Scan may primarily remain practiced to measure fibrotic area as the another to the liver biopsy also serum analysis, since this remains very harmless technique through similar indicative correctness concerning present fibrotic area indicators.

Key words: Cirrhosis; Numerical image investigation; Fibro- Scan; Fibrotic zone; Hyaluronate; Lecithin-cholesterol, Pre-albumin.

Corresponding author:

Dr. Sidra Zaheer,

Pakistan Institute of Medical Sciences.

QR code



Please cite this article in press Sidra Zaheer et al., *Comparison Of Non-Invasive Biochemical Markers (Apri, Fib-4) With Fibroscan For Prediction Of Cirrhosis In Hepatitis C Patients*, Indo Am. J. P. Sci, 2019; 06(09).

INTRODUCTION:

The key purpose of our research was to measure association amongst fibrotic area as intended through the numerical image analysis (DIA), also to associate analytical correctness of Fibro Scan to additional prevailing Liver fibrosis indicators while experiencing receiver functioning curve examination. The development of NF rises immobility of the liver also obstacle of the liver circulatory system [1]. An inadequacy of the liver circulatory system leads to dissatisfaction of the liver and a possible liver cirrhosis. In addition, biopsy tests are usually not enough to even consider a correct evening diagnosis of the disease, and characteristic endpoints distinguish between pathologists much of the time. As necessary, a masochistic assessment by and large does not give an unambiguous finding [2]. In addition, the histological estimation of LF is also problematic due to the symptomatic change. Starting with delayed transient elastography is open to the study of NF as a rapid non-invasive strategy that can measure liver robustness from outside the body [3]. The Fibro Scan differs from conventional markers such as haematological markers. Test and fibro test that correctly addresses the condition of liver fibrosis detected by the METAVIR counting scheme. The illustrative precision of Fibro Scan as such was considered a comparison with that of ordinary markers. We next surveyed the compound among FA's and differentiating biochemical markers to perceive which indicators might address a resolution of liver limit related through FA [4]. In adding, researchers similarly assessed association among the fibro scan and various biochemical indicators to understand if the fibro scan could exactly reach the liver limit. We also investigated the relationship between the FA also present LF markers such as fibro scan, hyaluronate, type iv collagen also APRI. The concluding purpose of the current evaluation remained to review association of current revelations with the FA also to analyze medical correctness of the fibro scan in addition various indicators [5].

MATERIALS AND METHODS:

Patients:

Researchers employed 35 cases that experienced the liver resection for 3 diverse etiologies counting standard liver, hepatitis B, also hepatitis C. Liver difficulty stayed leisurely through experiencing the Fibro Scan. The fibrotic area remained at that time designed through numerical image analysis to assess Liver fibrosis in order to evade somewhat sample partiality. Researchers observed 36 cases that experienced the liver resection from May 2017 to April 2018. Compulsive analysis for liver remained

completed in altogether 12 trials of standard liver, liver fibrosis, also liver cirrhosis.

Liver stiffness measurement:

The rule of elastography with a Fibro Scan® is now shown. All estimates were performed in the correct hepatic fold through intercostal spaces in respondents with dorsal decubitus. Location by right arm within maximum gripping range. The landfill of test sensor remained verified through coupling gel also located on skin among ribs at level of correct liver projection. The manager, supported by ultrasound time development also A-mode pictures of scheme, found a part of liver that stayed 7 cm thick at every opportunity and free of immense vascular structures. The outcomes remained articulated in kPa. Mean remained seen as an example of adaptable liver module. The entire report was supported for less than 5 minutes. Only frames with 12 confirmed estimates and a triumphal speed of 65% each remained careful dependable.

Digital image examination of liver fibrotic zone:

Liver fibrosis remained examined with the PC program. Tissue fragments were dissected by Azan-Mallory. refreshing. The fibrotic zone remained colored blue also displayed by means of a basic blue sign with Adobe Photoshop CS. Individually respondent remained observed by 17 new grounds in three diverse models. A field that checked 12 access routes on each occasion. The zone of the blue panel was resolved.

Statistical examination:

The arithmetical examination of connection among pathological fibrosis also additional medical information remained achieved by Spearman's rampant association constant by means of Stat View 5.8 software bundle. Altogether consequences remain articulated as mean \pm SD. $P < 0.06$ remained measured statistically substantial.

RESULTS:

The fibrotic area harmfully connected by Prothrombin time (PT), platelet sum, lecithin-cholesterol acyltransferase (LCAT), also pre-albumin (ALB). On supplementary side, results of Fibro Scan connected through comparable signs. The fibrotic area absolutely associated by Fibro Scan, serum hyaluronate equal, also kind IV collagen equal, in addition aspartate transaminase to platelet relation directory (APRI). The zone underneath receiver functioning arc for Fibro Scan remained developed than that for extra signs, whereas arithmetical implication remained negligible. Researchers designated cases that met a hepatectomy by 3 specific etiologies (Table 1). The sufficient model

for histologic evaluation must be obtained from a cautious model, as biopsy models are usually lacking to perform an accurate examination. We have verified the distinctive fibrotic zone (FA) of LF with a driven image examination (DIA), which is an essential and reliable method. Researchers solitary presented blue shield from the completely concealed image and opted for FA. One showed a negative association observed for ALB, Pre-ALB, LCAT and platelet check (Figures 2 A-D). The supplementary displayed very optimistic

relationship to fibro scan disclosures observed for ZTT and ICGR15 (Figures 2 E and F). The pre-ALB values displayed most astounding association by FA in addition fibro scan among the normal scientific disclosures studied. We inspected the region under the beneficiary work curve (AUC) to take a look at the exposure accuracy of Fibro Scan and various markers (Table 4). The symptomatic differentiation of the fibro scans prolonged with the prolongation of the FA.

Table: Features of the respondent:

Features			n =35
Etiology	262.80 ± 69.34	Choline esterase	10:10:10
(N:CH:LC)	21.92 ± 7.01	Pre-ALB	10:10:10
Gender (Male: Female)	3.19 ± 1.39	RBP (mg/dL)	22:8
Age	100.66 ± 25.78	LCAT (U)	65.4 ± 10.3
Body Mass Index	136.73 ± 32.43	Apo-A1 (mg/dL)	24.3 ± 3.1
ALB	12.86 ± 6.44	ICGR15 (%)	4.03 ± 0.60
Over-all Bilirubin	0.82 ± 0.29	Fibrotic part	98.83 ± 16.85
PT (%)	15.32 ± 9.69	APRI	0.68 ± 0.47

Table: Association through fibrotic part:

Signs	r	P-values
ALB	1.13	1.559
T-Bil	-1.459	1.026a
PT	1.472	1.022a
PT-INR	-1.388	1.067
Platelet count	-1.515	1.011a
RBP	-1.58	1.003
Pre-ALB	-1.447	1.032a
LCAT	1.364	1.002a
ICGR15 (%)	-1.609	1.089

Table 3: Association through Fibro Scan:

Signs	r	P-values
ALB	1.14	1.246
T-Bil	-1.457	1.027a
PT	1.473	1.024a
PT-INR	-1.389	1.069
Platelet count	-1.516	1.01a
RBP	-1.59	1.021
Pre-ALB	-1.448	1.035a
LCAT	1.366	1.082a
ICGR15 (%)	-1.674	1.085

Table 4: Contrast of investigative correctness of Fibro Scan also extra signs:

	Fibrotic Zone >12%						
	OC	Sens	Specie	SE	95%	AUC	CI
Fibro Scan	84.6	0.080	76.5	0.618	- 0.924	96.0	0.803
HA	76.5	84.6	0.081	0.57	0.615	- 0.923	0.801
APRI	0.047	76.9	0.777	100	- 0.999	9.1	0.932
	Fibrotic Zone > 21%						
	OC	Sens	Specie	SE	95%	AUC	CI
Fibro Scan	- 0.993	0.946	0.797	0.991	0.061	106.0	77.3
HA	- 0.985	0.758	0.918	0.071	87.5	6.6	90.9
Col	0.642	68.2	0.58	- 0.937	87.5	0.098	0.824
APRI	95.5	0.024	0.868	100	- 1.000	0.341	13.6

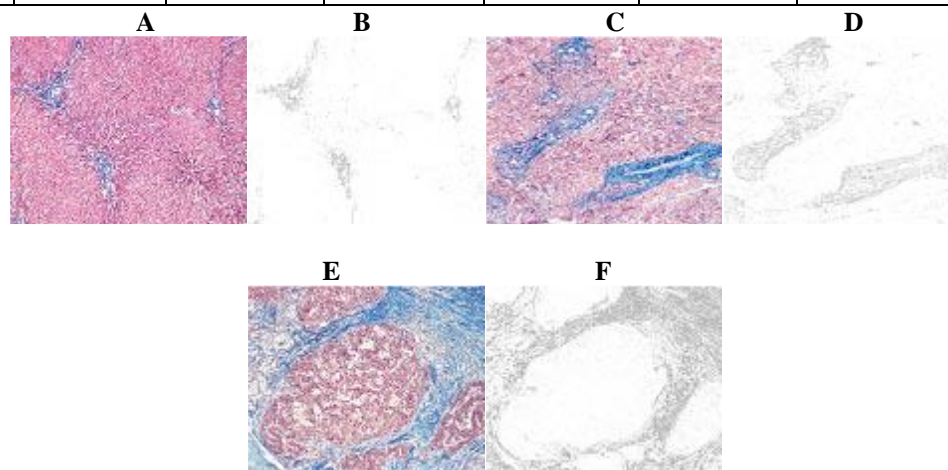


Figure 1: Hematoxylin-eosin discoloration of clinical samples (A, C, also E). The pictures scanned also portrayed individual blue signs by means of the computer database. The blue signs remained calculated as zone of fibrosis (B, D, also F).

DISCUSSION:

We have determined that the biochemical data related to FA are the subject of DIA. Amongst indicators studied pre-ALB presented the advanced undesirable association with FA in addition Fibro Scan than different indicators [6]. The symptomatic correctness of Fibro Scan remained developed than that of additional indicators present, though true vitality remained unimportant. The fibro scan can also remain exercised to assess LF also liver limit deprived of trivial indecency [7].

Biochemical valuation of LF:

Here remain several customs to deal with review LF through serum biomarkers also hypochondriac assessments. Most of these studies are expected to investigate fibrosis in infinite hepatitis C cases. Direct biomarkers, just like these for aspartate aminotransferase alanine aminotransferase extent also AST platelet extent, also business tests, just like Fibro test®, were confirmed to detect patients with true LF and an average liver [8]. In any case, it is unclear

whether they are addressing FA with different etiologies that clearly refer to liver disease. APRI related to FA in the current research. In any case, comparative influence remained significantly not exactly searched for altered markers. It is definitely not difficult to take a look at APRI in clinical trials.

Liver arduousness as the new sign for calculation of LF:

Starting with delay, Fibro Scan was used for the evaluation of LF as opposed to the old-style markers. This outcome remains solid through these in late rumors examining viral hepatitis C cases through abnormal fibrosis otherwise cirrhosis. Despite way in which the AUC of the attempted markers was higher for over 23% FA than for over 10% FA, the AUC of Fibro Scan maintained a really strange condition for over 12% FA [9]. There are a number of scoring structures, for example, histology development Rundown by Kendell et al, in addition their change by Ishak et al, also METAVIR scheme. Regardless, just like illustrative variance in hypochondriac evaluations

cannot be ignored due to the tendency of pathologists and small models.

DIA for precise valuation of LF:

Therefore, a motor image study should be performed to evaluate the NF. On the other hand, the clinically favorable circumstances of mechanized duplicate evaluation remain questionable. The theme of this strategy remains frame exercised to represent stringy signs. At the time when remarkable psychotic images are transformed into a boring scale, it is ultimately extremely difficult to perceive recorded and uncolored areas for an explicit type of recording. Believe it or not, the histogram of portrayed pictures may display opaque twists among them [10].

Biochemical signs for liver purpose display the undesirable connection to LF:

The liver boundary rots during the development of LF and cirrhosis. In any case, it is not fully understood to pay attention to whether serum proteins disintegrate with the reality of the disease and whether they are markers for NF remains blurry. On extra side, researchers originate that LCAT also Pre-ALB remain essentially associated by LF.

CONCLUSION:

The current conclusions recommend that fibro Scan may primarily remain practiced to measure fibrotic area as the another to the liver biopsy (LB) also serum analysis, since this remains very harmless technique through similar indicative correctness concerning present fibrotic area indicators.

REFERENCES:

1. Wright M, Thursz M, Pullen R, Thomas H, Goldin R. Quantitative versus morphological assessment of liver fibrosis: semi-quantitative scores are more robust than digital image fibrosis area estimation. *Liver Int* 2003; 23: 28-34
2. Schneider PD. Preoperative assessment of liver function. *Surg Clin North Am* 2004; 84: 355-373
3. Mizuguchi T, Katsuramaki T, Nobuoka T, Kawamoto M, Oshima H, Kawasaki H, Kikuchi H, Shibata C, Hirata K. Serum hyaluronate level for predicting subclinical liver dysfunction after hepatectomy. *World J Surg* 2004; 28: 971-976
4. Horton RC, Owen JS. LCAT activity as a prognostic liver function test. *Lancet* 1990; 336: 249-250
5. Tahara D, Nakanishi T, Akazawa S, Yamaguchi Y, Yamamoto H, Akashi M, Chikuba N, Okuno S, Maeda Y, Kusumoto Y. Lecithin-cholesterol acyltransferase and lipid transfer protein activities in liver disease. *Metabolism* 1993; 42: 19-23

6. Rondana M, Milani L, Merkel C, Caregaro L, Gatta A. Value of prealbumin plasma levels as liver test. *Digestion* 1987; 37: 72-78
7. Bataller R, Brenner DA. Liver fibrosis. *J Clin Invest* 2005; 115: 209-218
8. Pinzani M, Rombouts K, Colagrande S. Fibrosis in chronic liver diseases: diagnosis and management. *J Hepatol* 2005; 42 Suppl: S22-S36
9. Ginès P, Cárdenas A, Arroyo V, Rodés J. Management of cirrhosis and ascites. *N Engl J Med* 2004; 350: 1646-1654
10. Everson GT. Management of cirrhosis due to chronic hepatitis C. *J Hepatol* 2005; 42 Suppl: S65-S74.